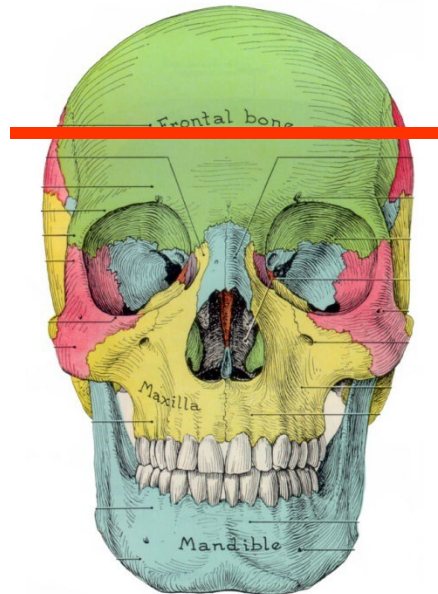


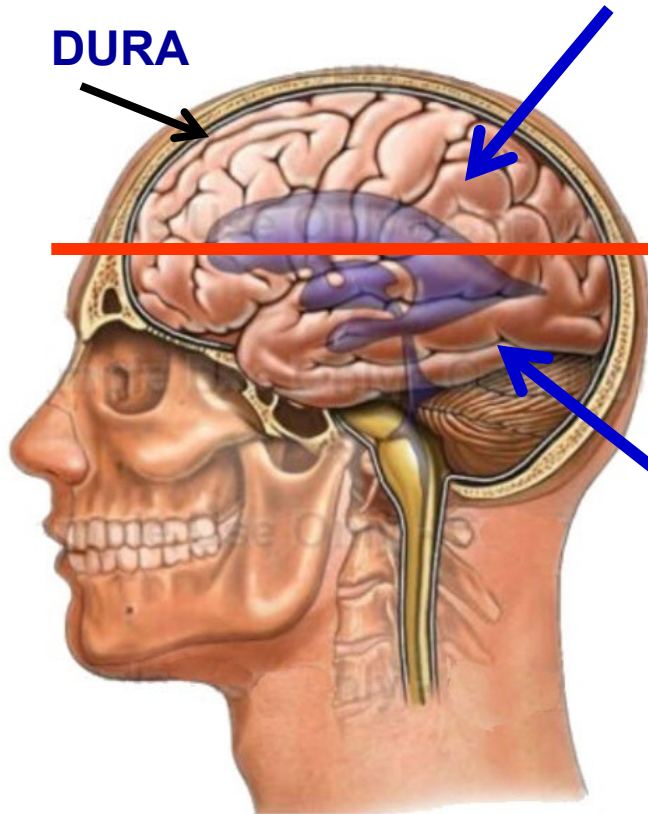
**PHOTOS OF BRAINS (HORIZONTAL CUT)
OF DONOR CADAVERS IN GROSS LAB
(BY DT = TABLE NUMBER)**

**STUDY IN PREPARATION FOR BRAIN
DISSECTION LAB, FRIDAY FEBRUARY 9,
2024**

ORIENTATION OF THE IMAGES: TOP AND BOTTOM HALVES OF CUT HEADS/BRAINS



**REMOVE CALVARIUM
AND UPPER HALF OF
BRAIN
(SAW CUTS ALREADY
MADE)**



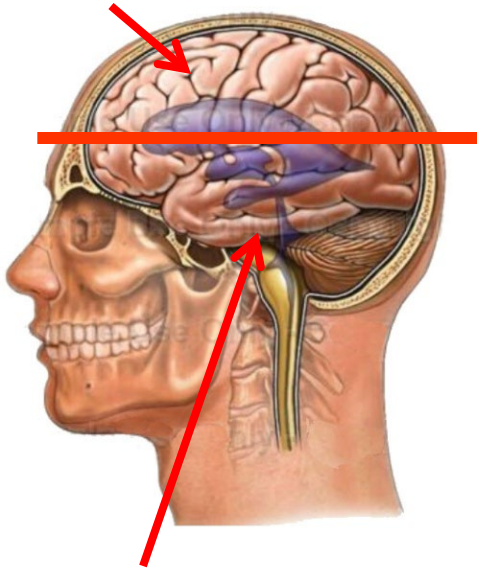
**UPPER HALF HAS
CALVARIUM (WITH
DURA) AND UPPER
HALF OF BRAIN**

**LOWER HALF
HAS REMAINDER
OF BRAIN,
BRAINSTEM,
CRANIAL
NERVES,
ARTERIES**

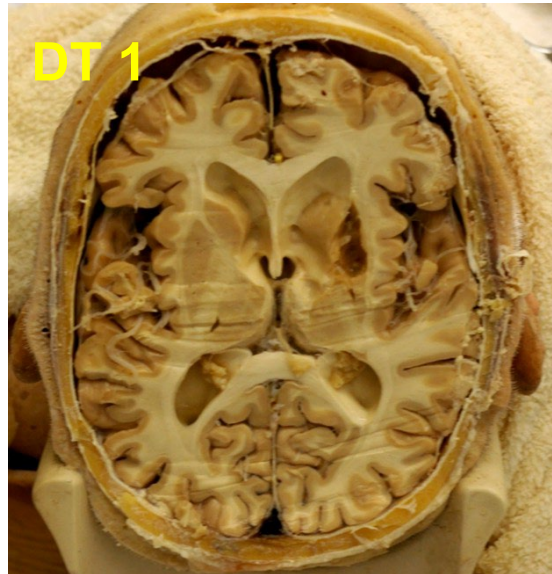
**CALVARIUM ALREADY REMOVED
WITH UPPER HALF OF BRAIN**

ORIENTATION OF THE IMAGES: TOP AND BOTTOM HALVES OF CUT BRAINS (DT = DISSECTION TABLE NUMBER)

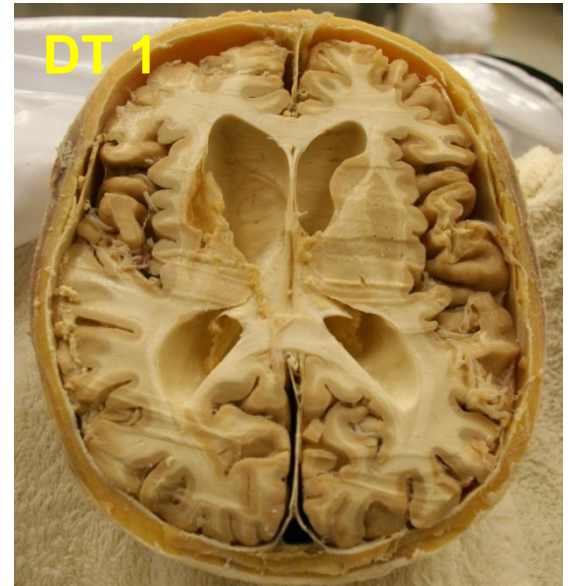
TOP HALF - REMOVED WITH CALVARIUM (SKULL CAP)



BOTTOM HALF - ON CADAVER

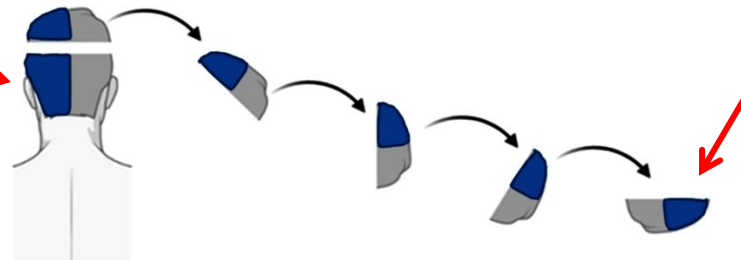
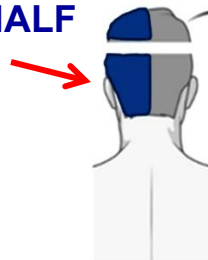


TOP HALF - IN CALVARIUM



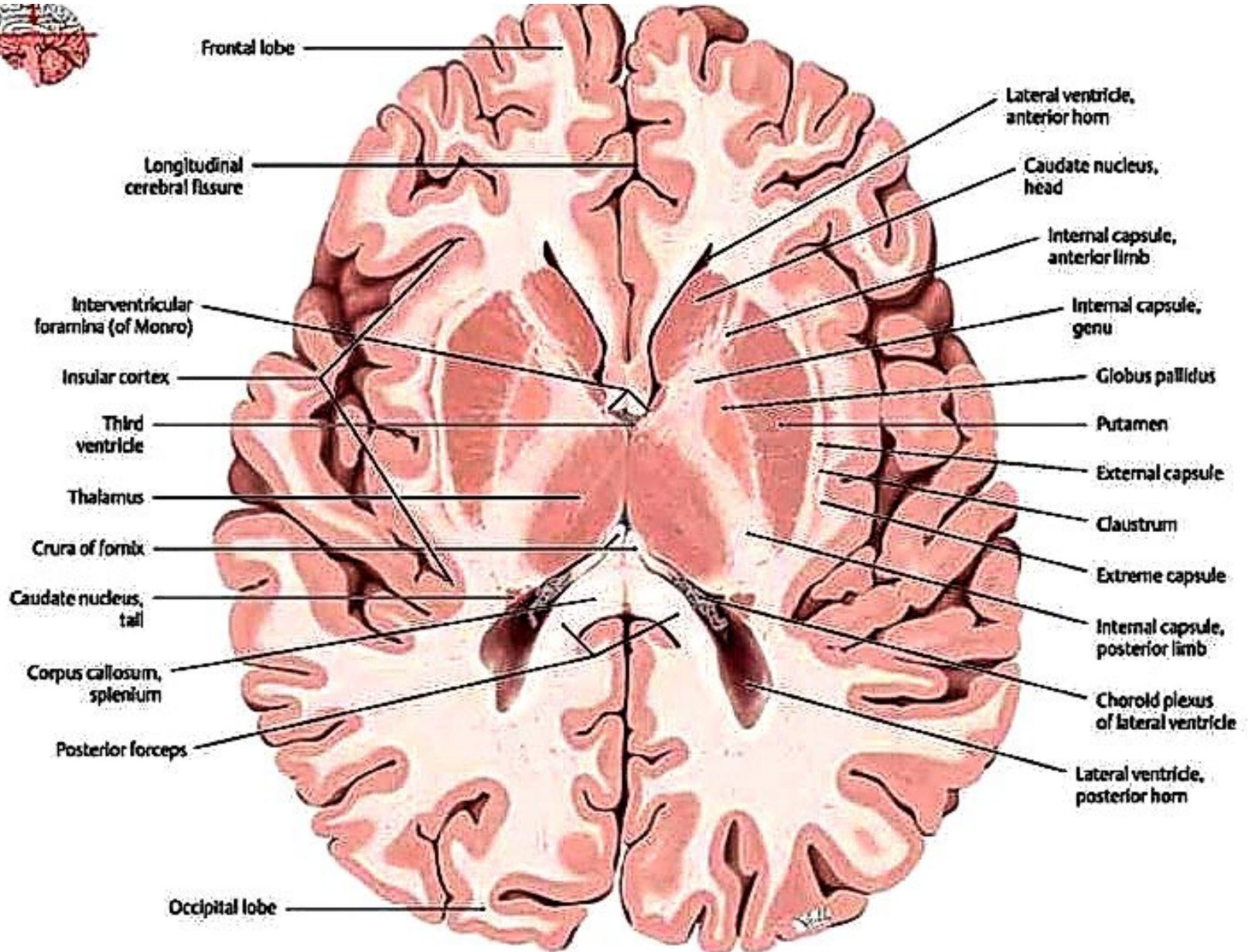
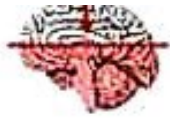BOTTOM HALF - IN CRANIAL CAVITY IN CADAVER

BOTTOM HALF - VIEW ON CADAVER



TOP HALF - NEXT TO CADAVER IN CALVARIUM

STRUCTURES SEEN ON MOST CADAVERS



DT1

Office DEPOT®

DT 1

Sex: Male

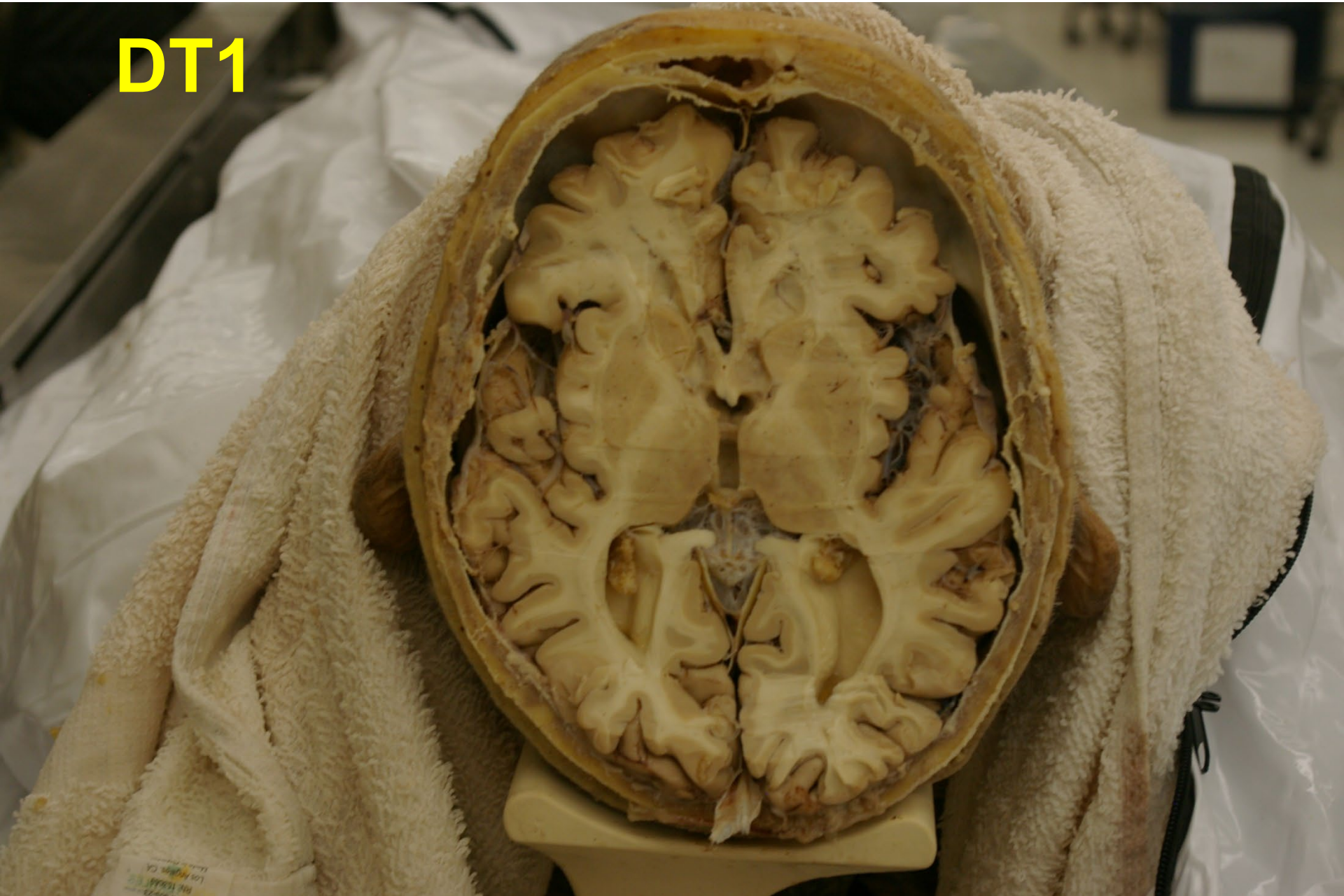Age: 88

SAB: 2022-370

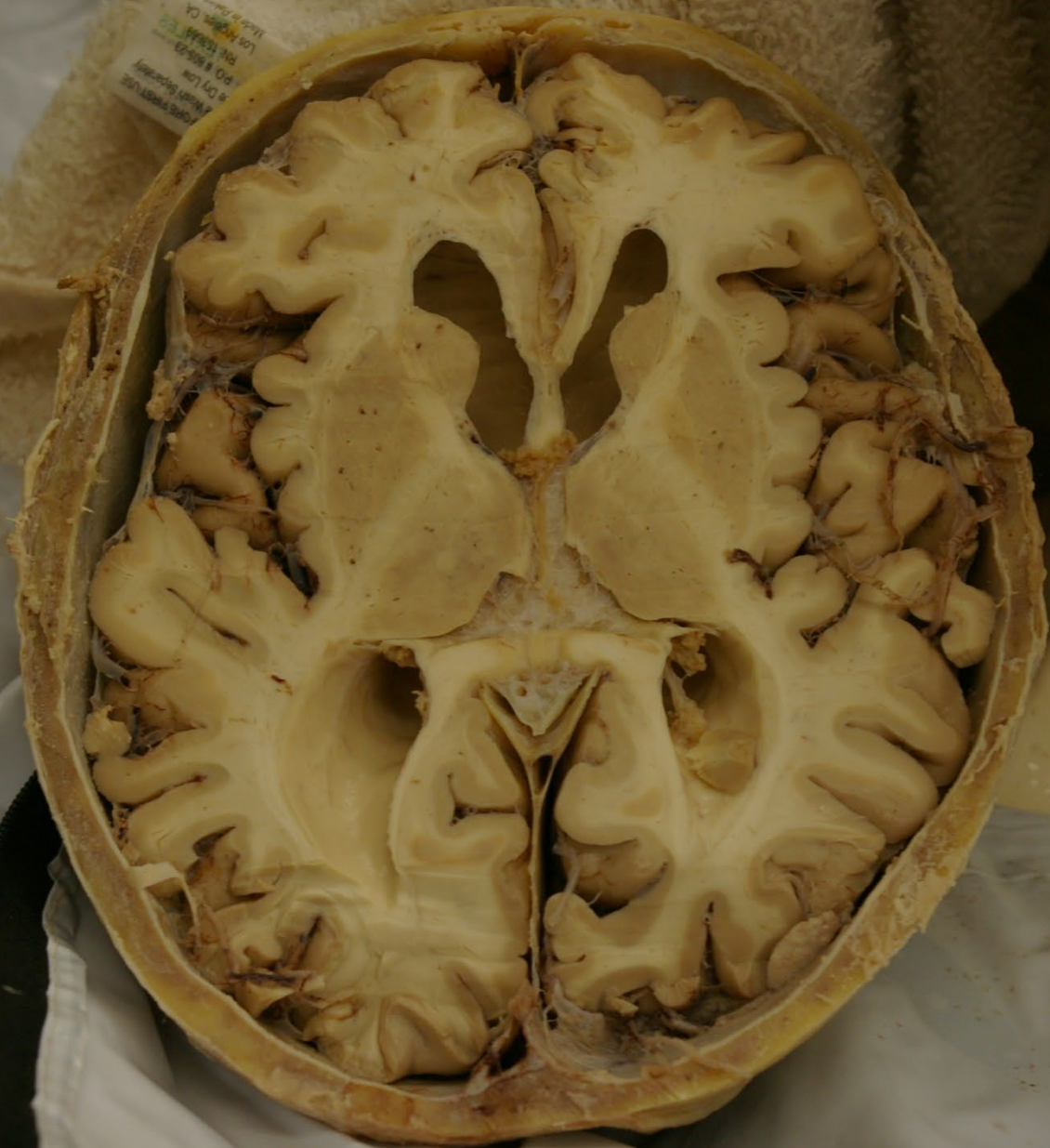COD: Heart Disease

R

DT1



DT1



DT2

Office DEPOT®

DT 2

Sex: Female

Age: 69

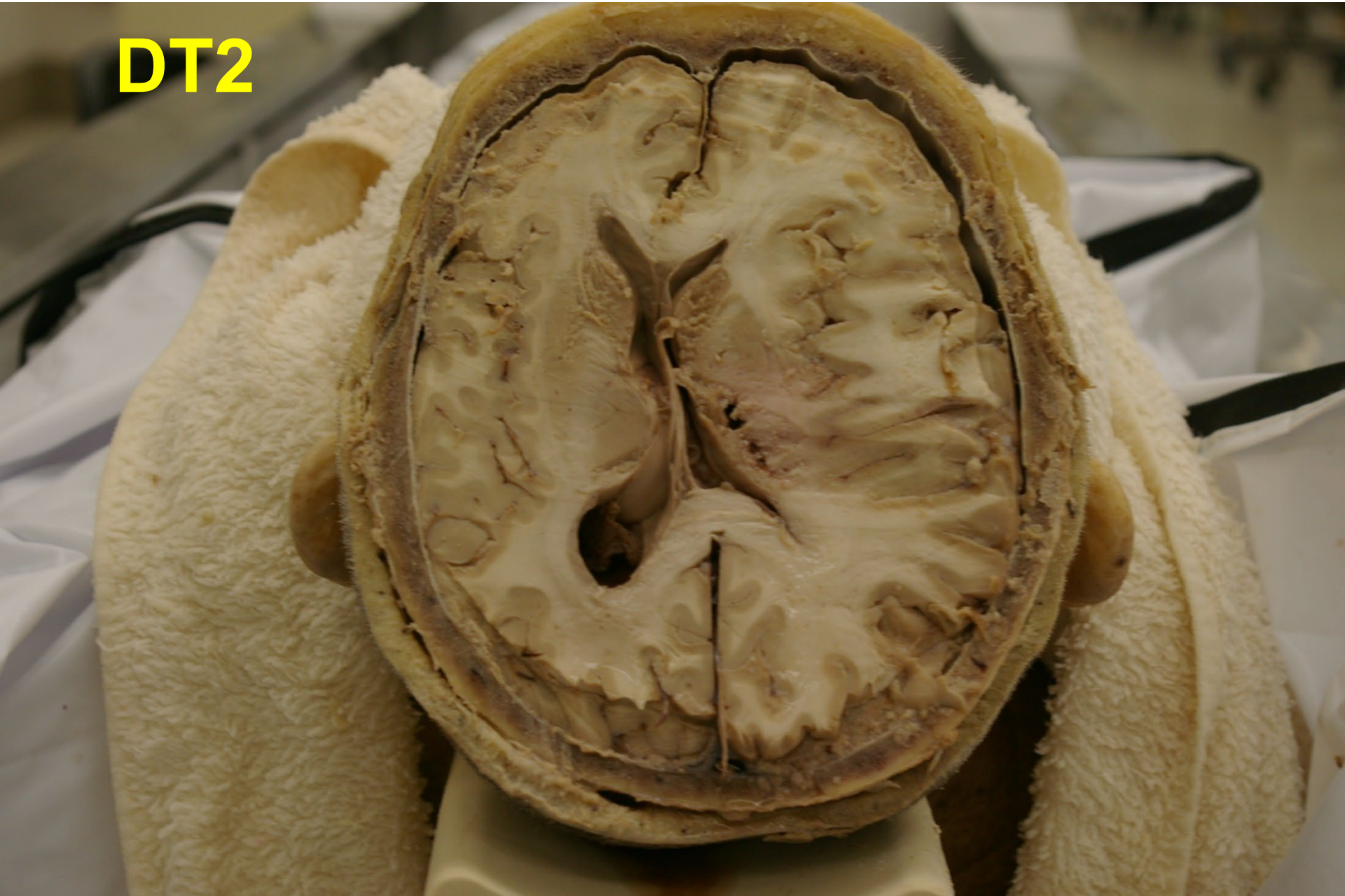
SAB: 2023-043

COD: Strokes

I

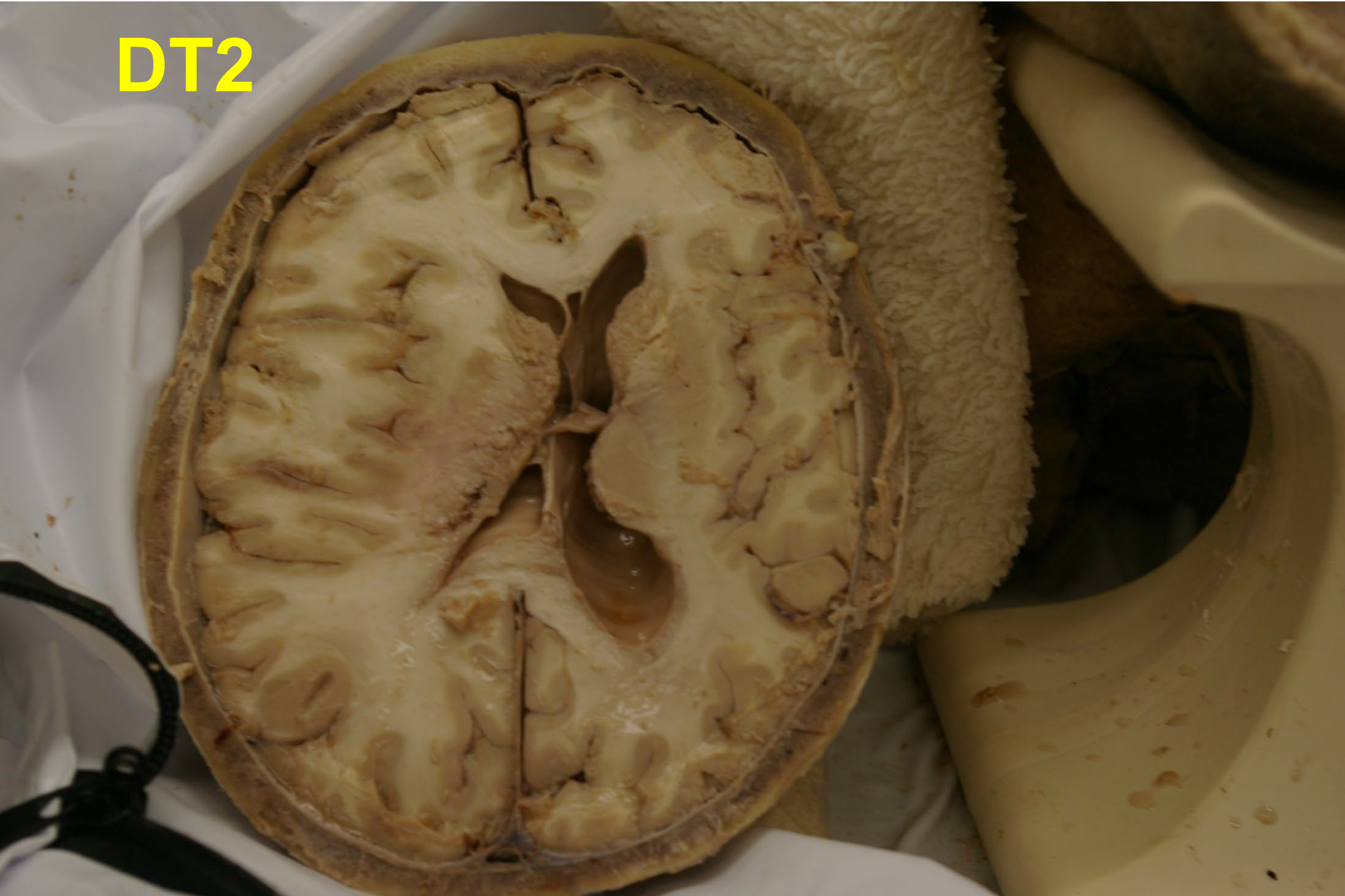What is wrong with this picture?

DT2



What is wrong with this picture?

DT2



DT3

Office DEPOT®

DT 3

Sex: Female

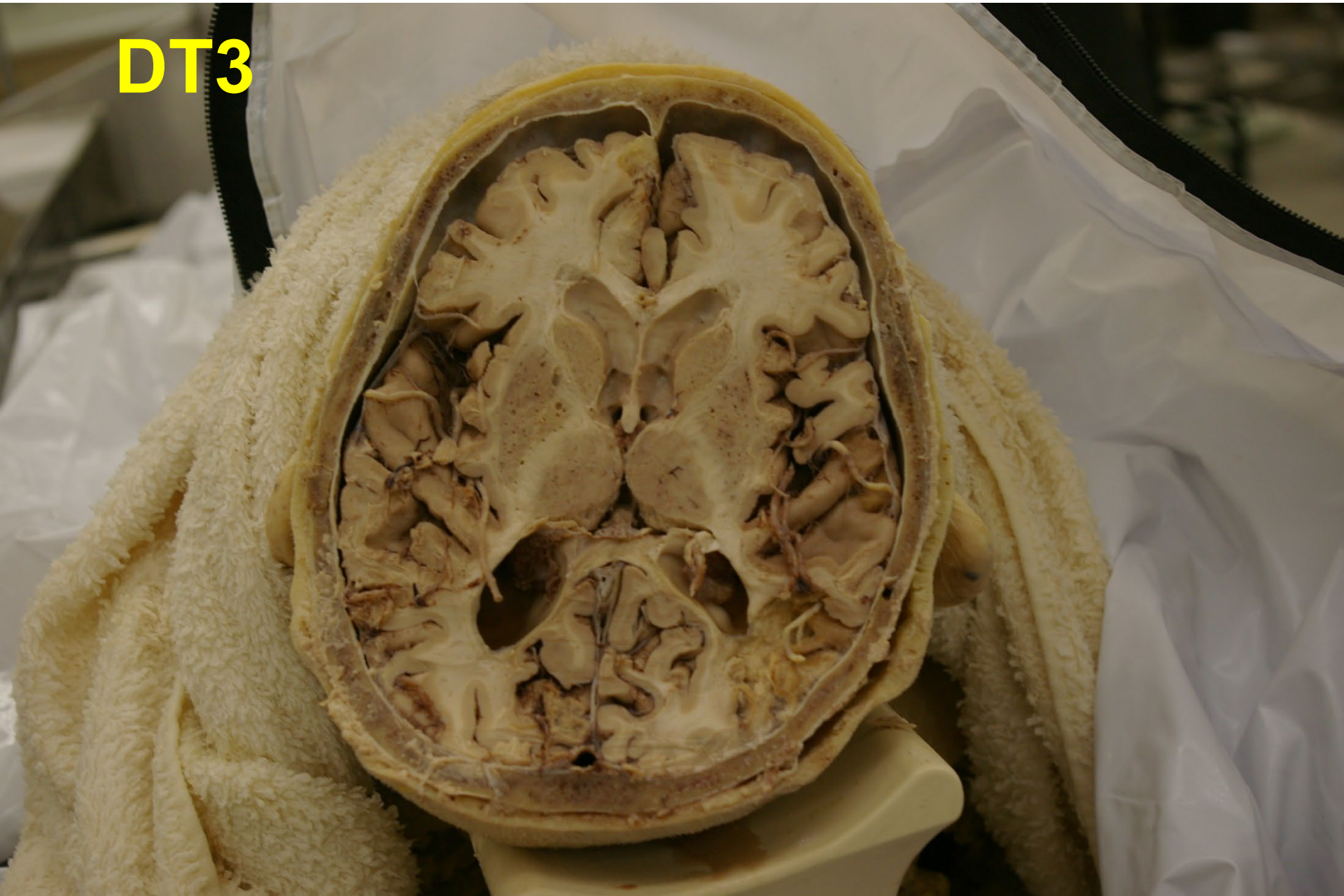Age: 82

SAB: 2023-074

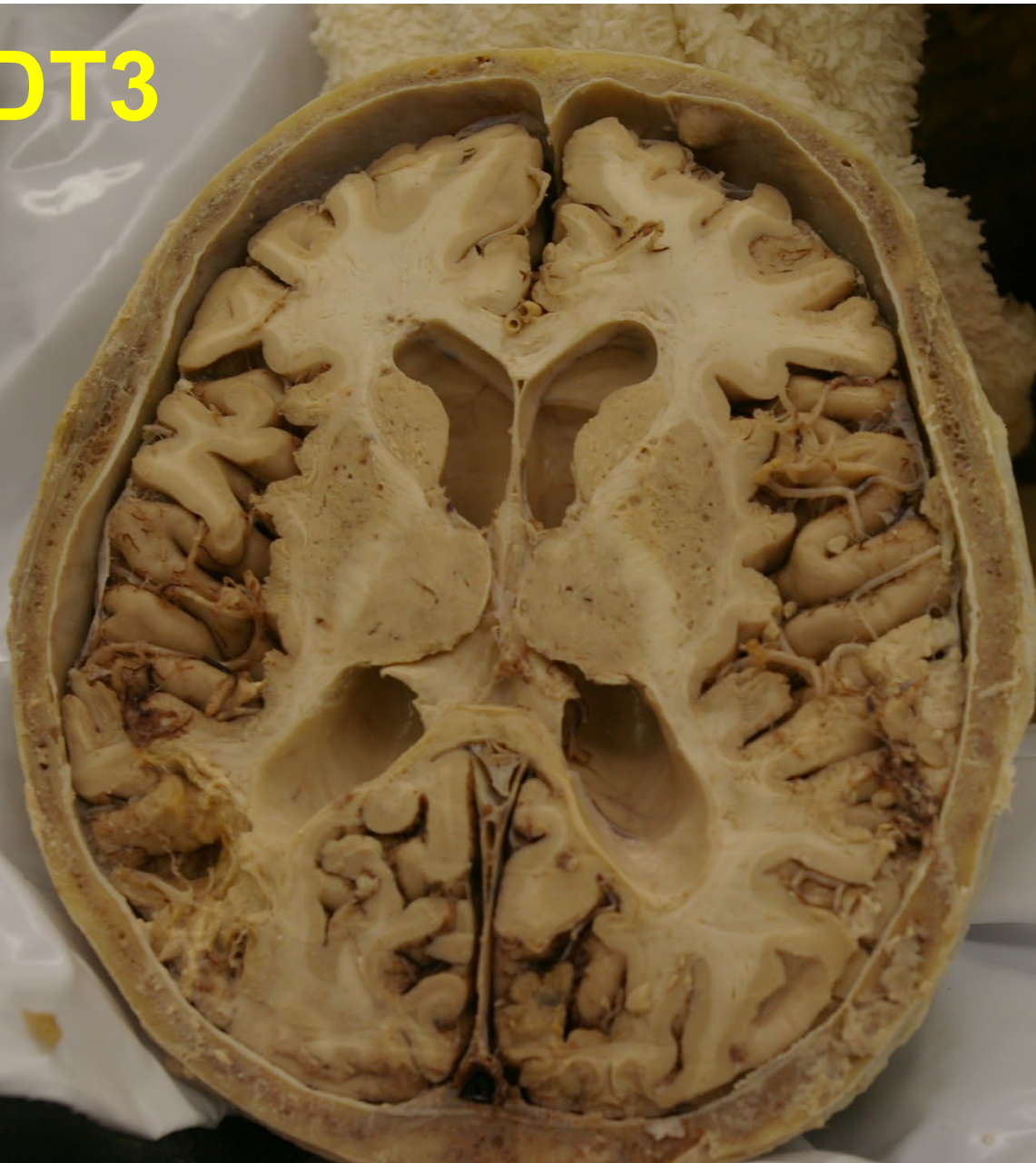
COD: Natural Causes

R

DT3



DT3



DT4

Office DEPOT®

DT 4

Sex: Male

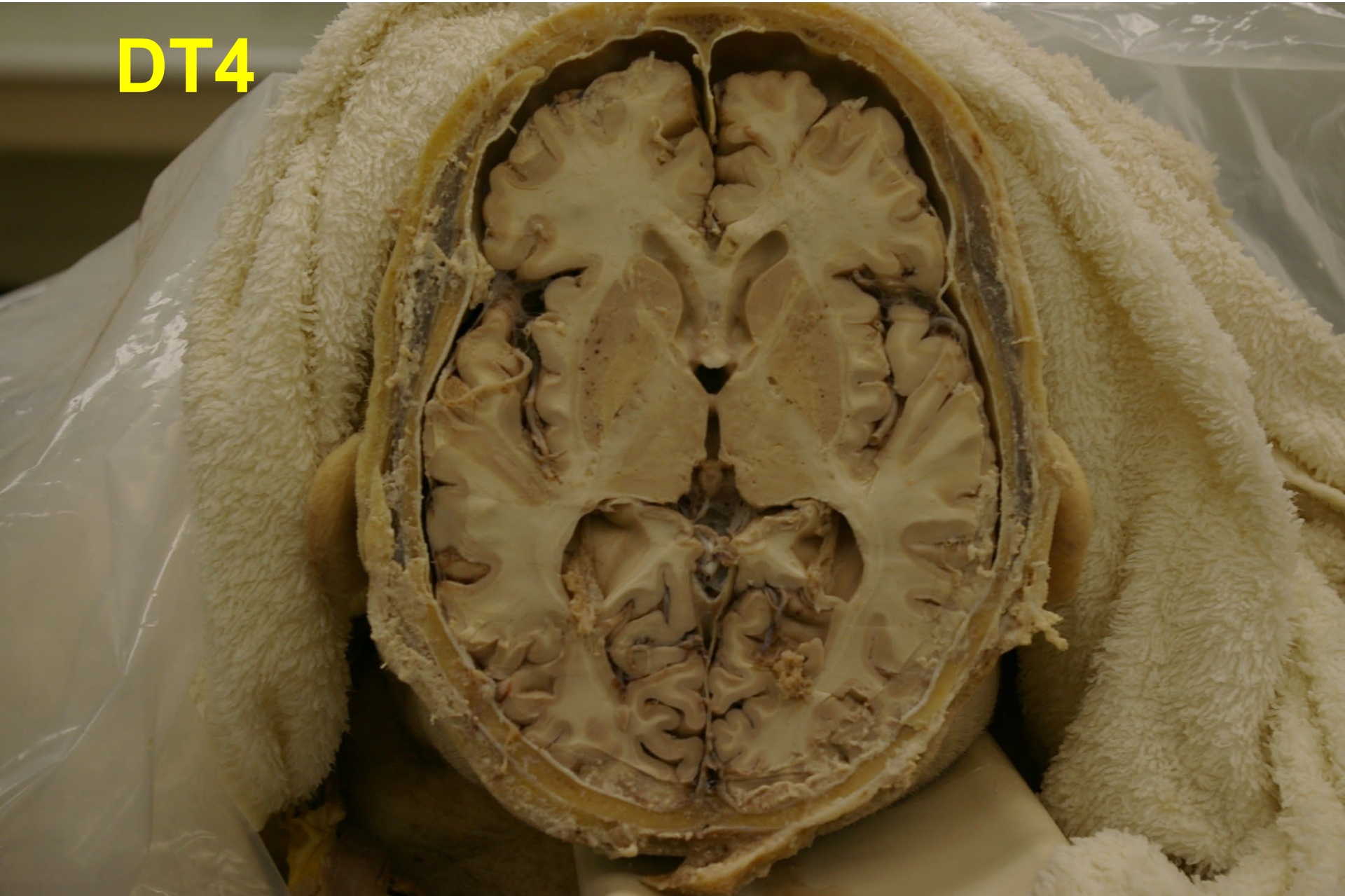Age: 70

SAB: 2023-165

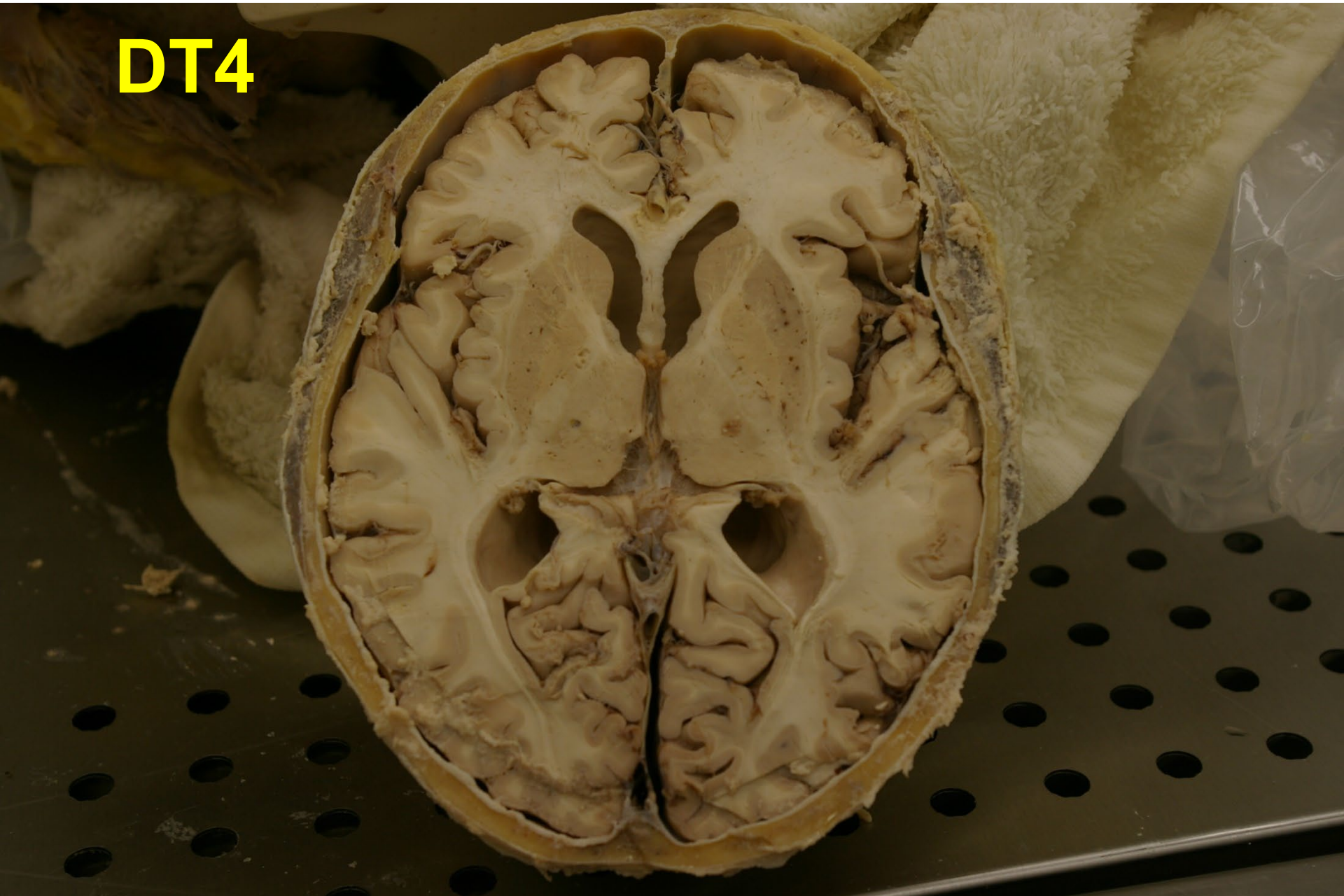
COD: stroke

R

DT4



DT4



DT5

Office DEPOT®

DT 5

Sex: Male

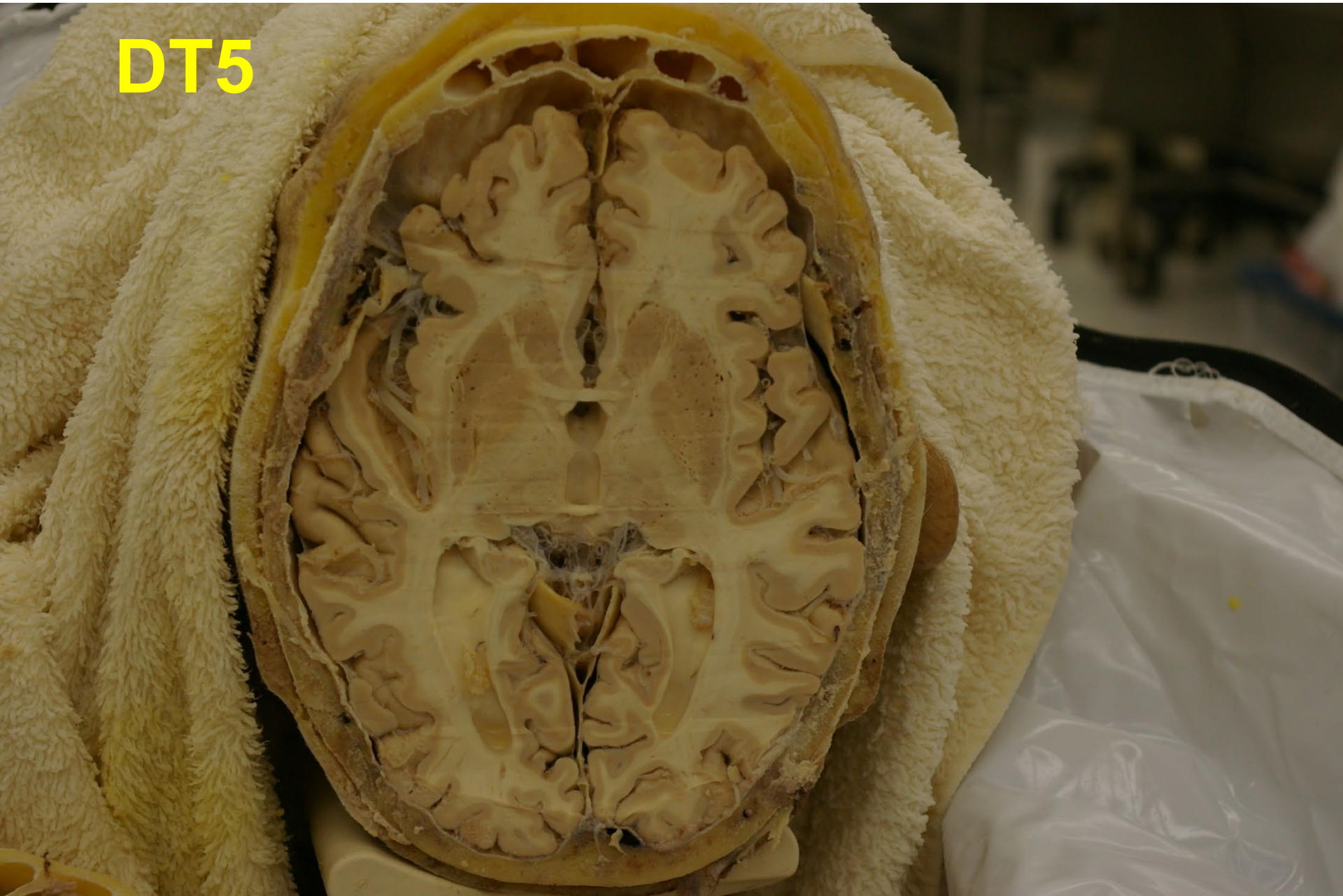Age: >90

SAB: 2023-179

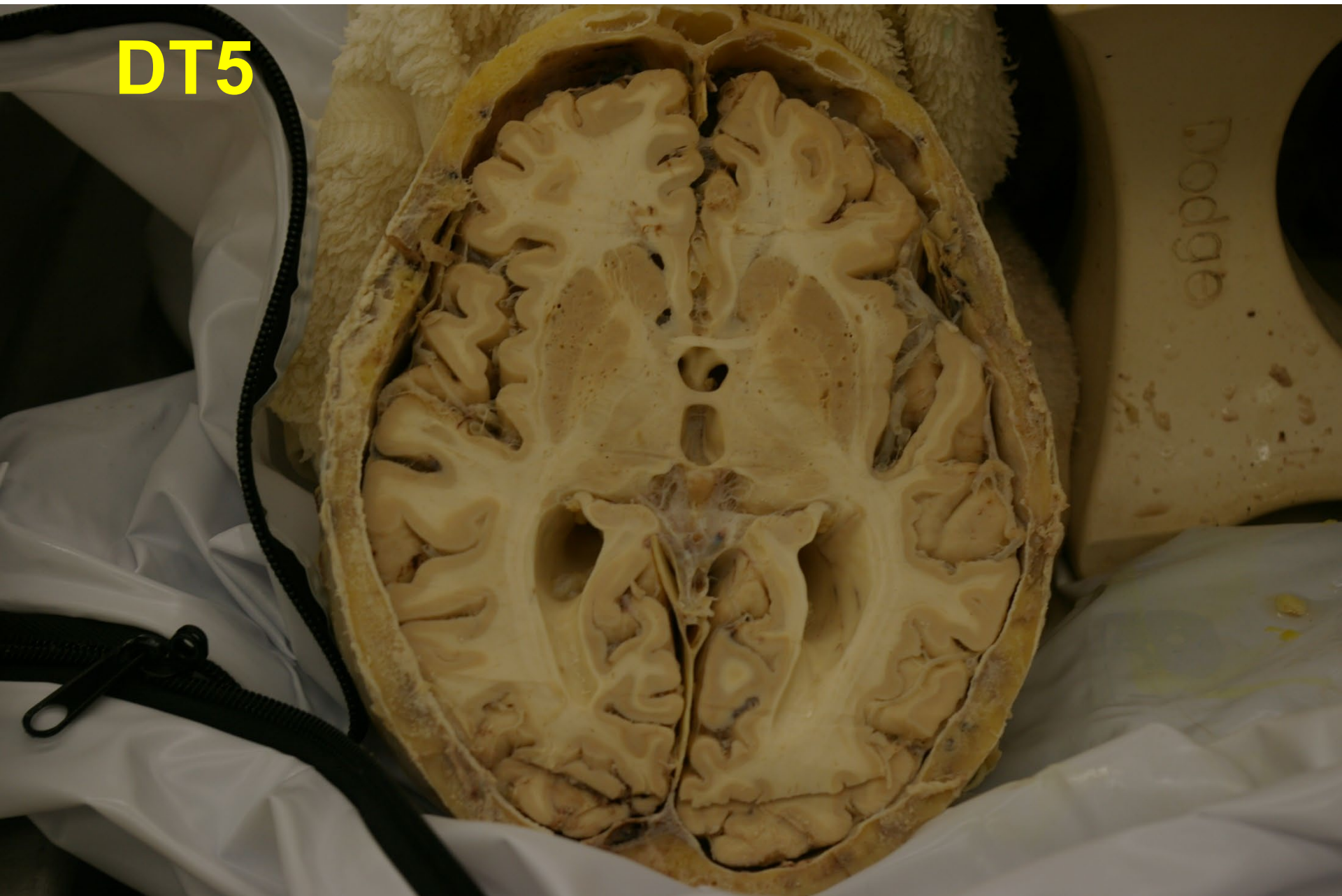**COD: Bilateral Pulmonary Embolism
Inter**

2023

DT5



DT5



DT6

Office DEPOT®

DT 6

Sex: Female

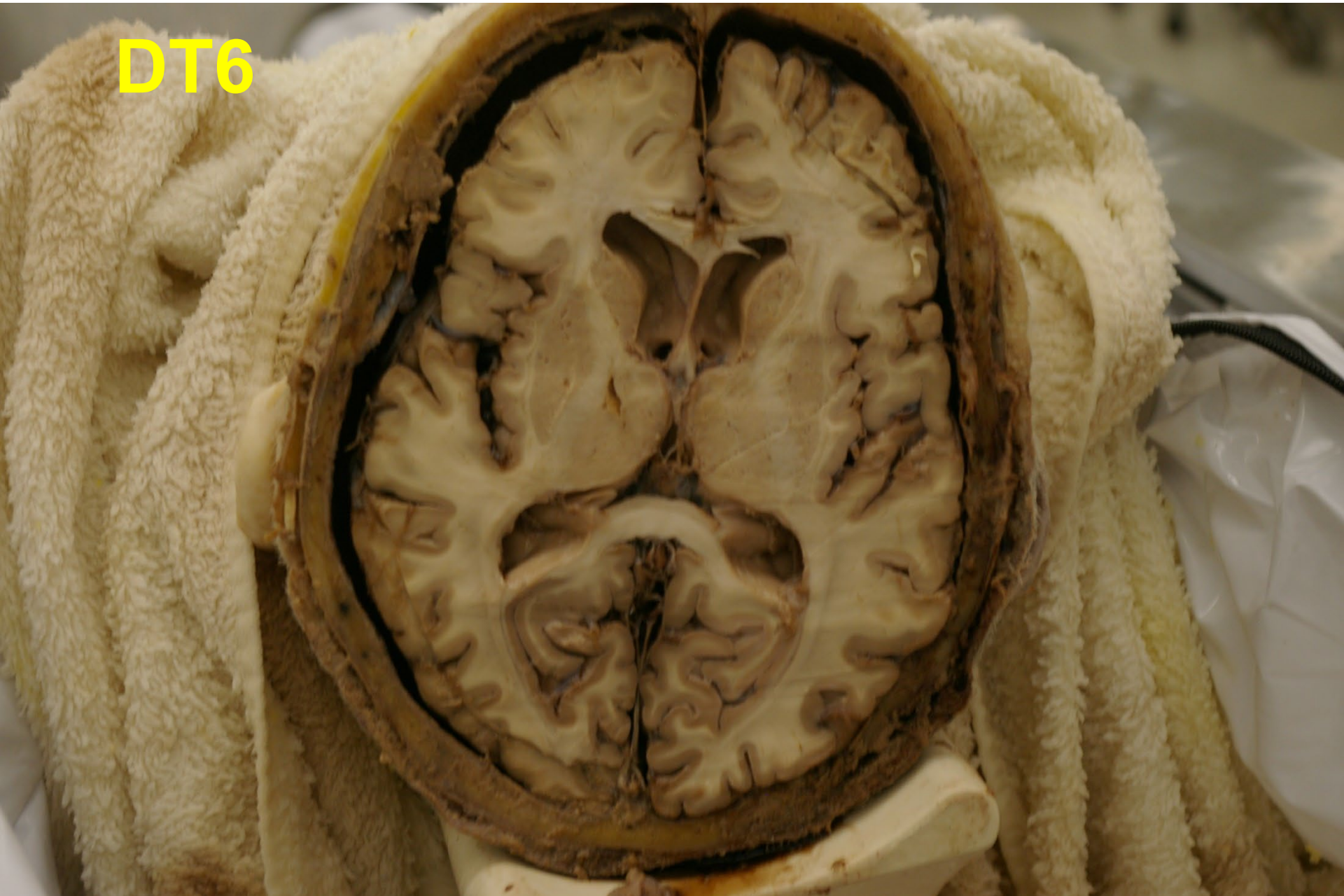Age: >90

SAB: 2023-307

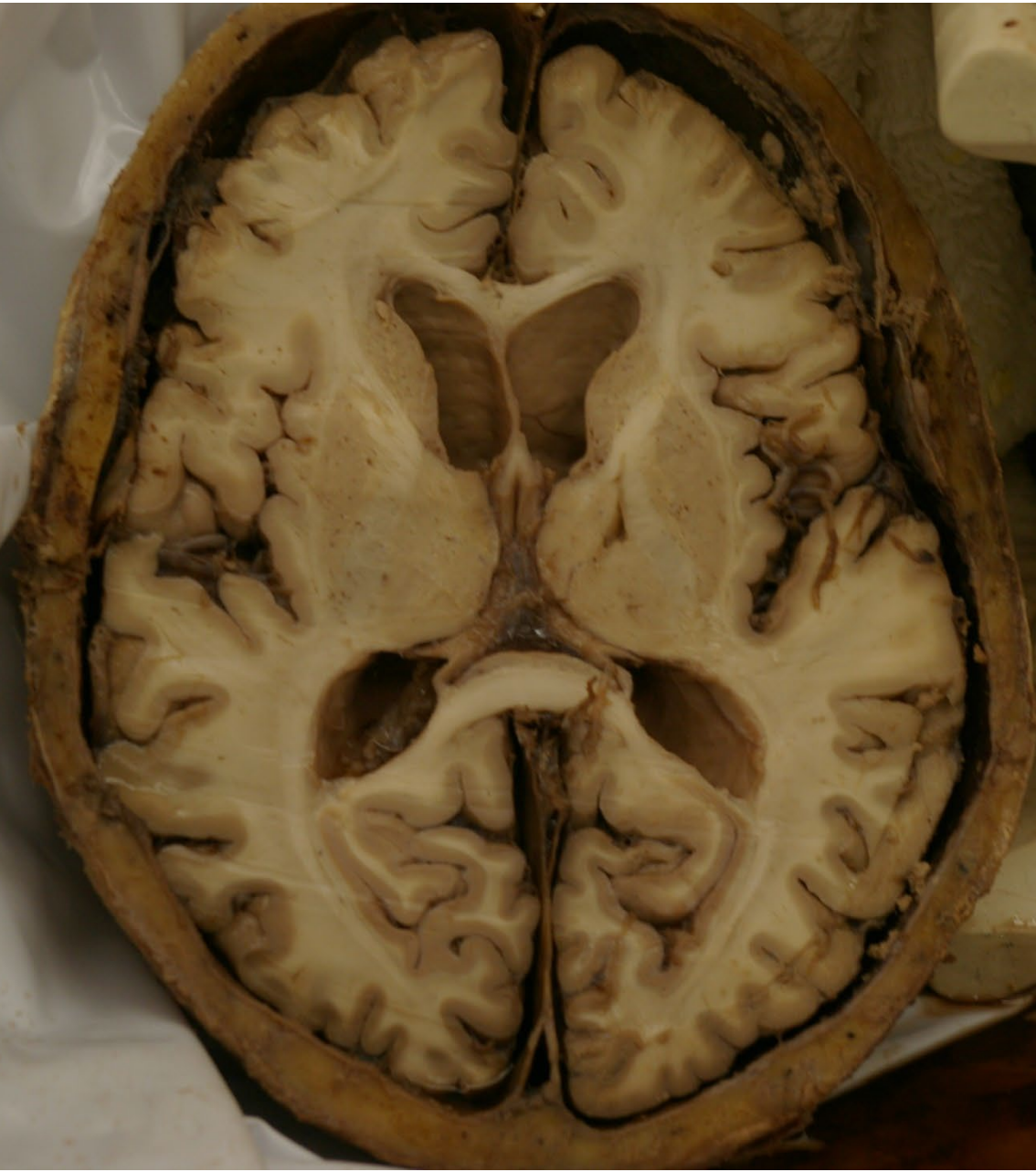
COD: Unknown natural causes

R

DT6



DT6



DT7

Office DEPOT®

DT 7

Sex: Female

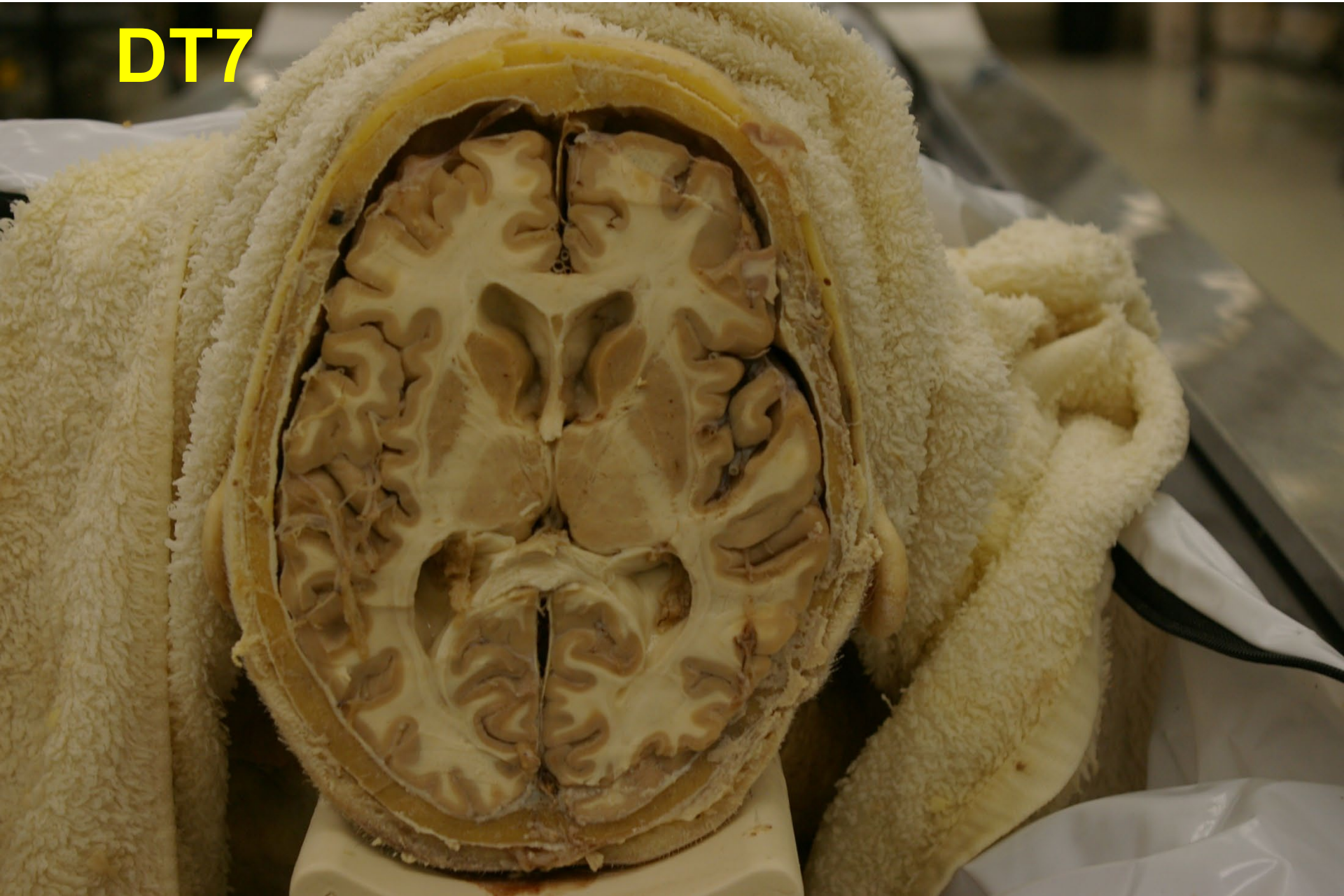Age: > 90

SAB: 2023-259

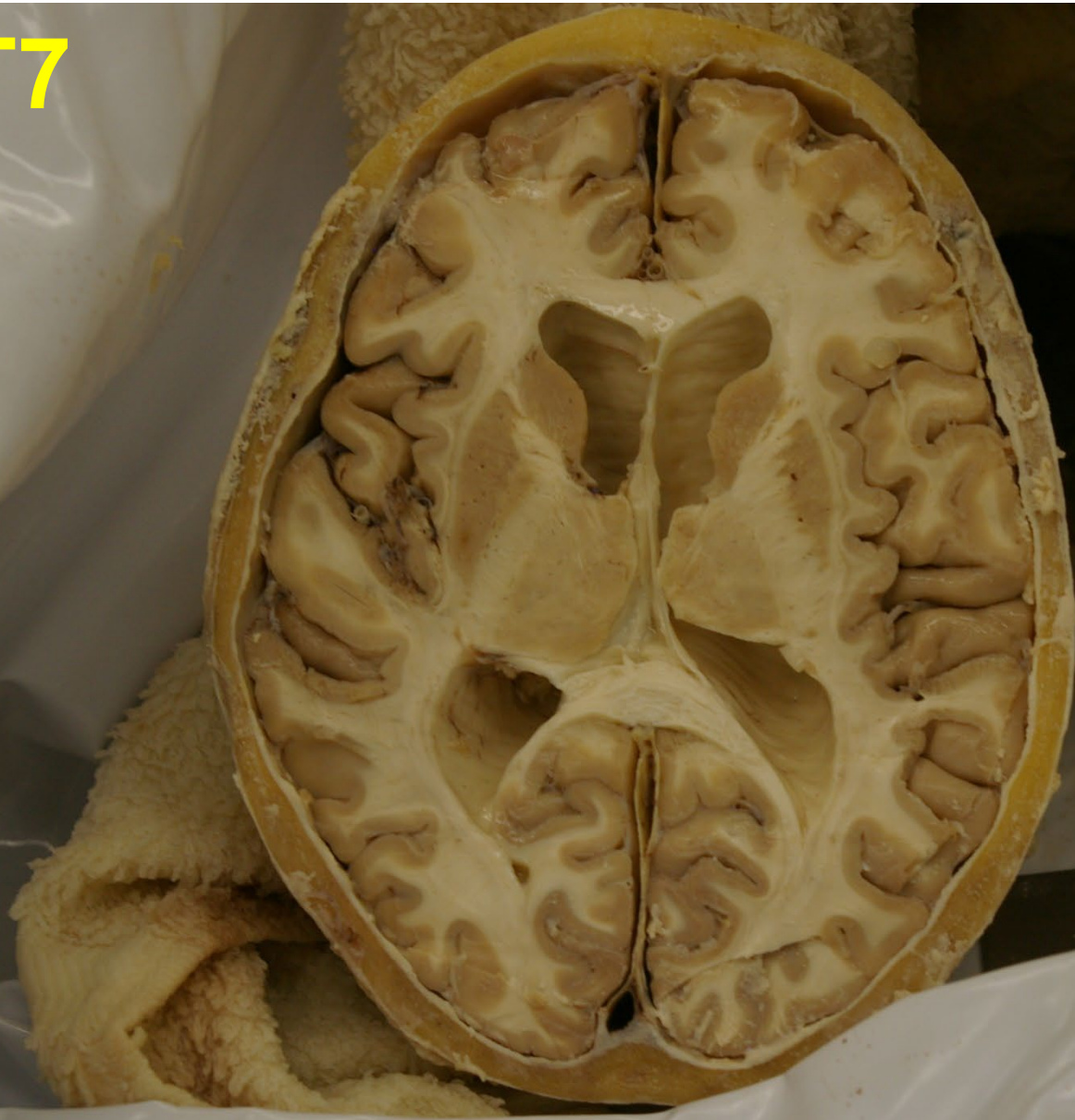COD: Cardiovascular disease

R

DT7



DT7



DT8

Office DEPOT®

DT 8

Sex: Female

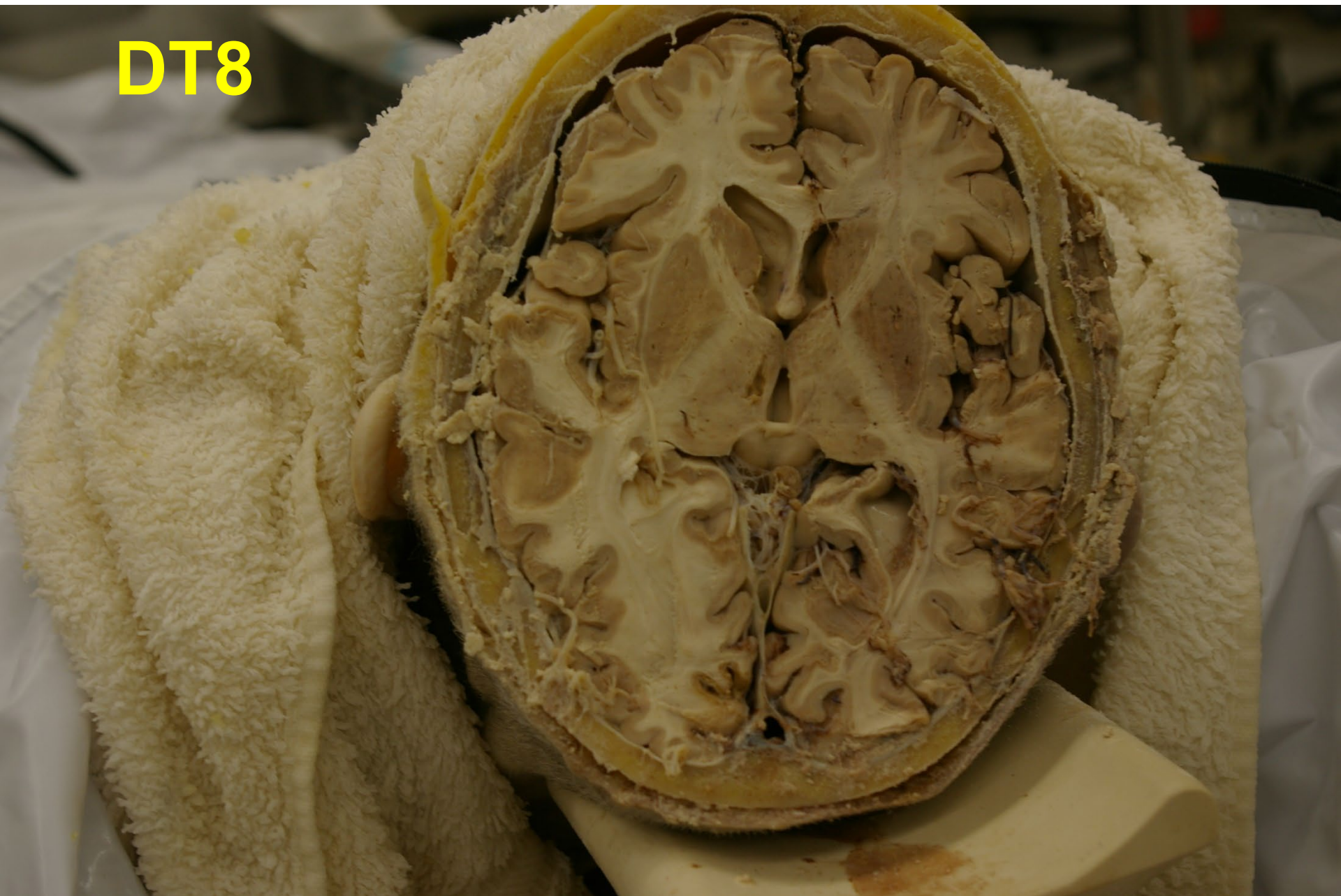
Age: 90

SAB: 2023-280

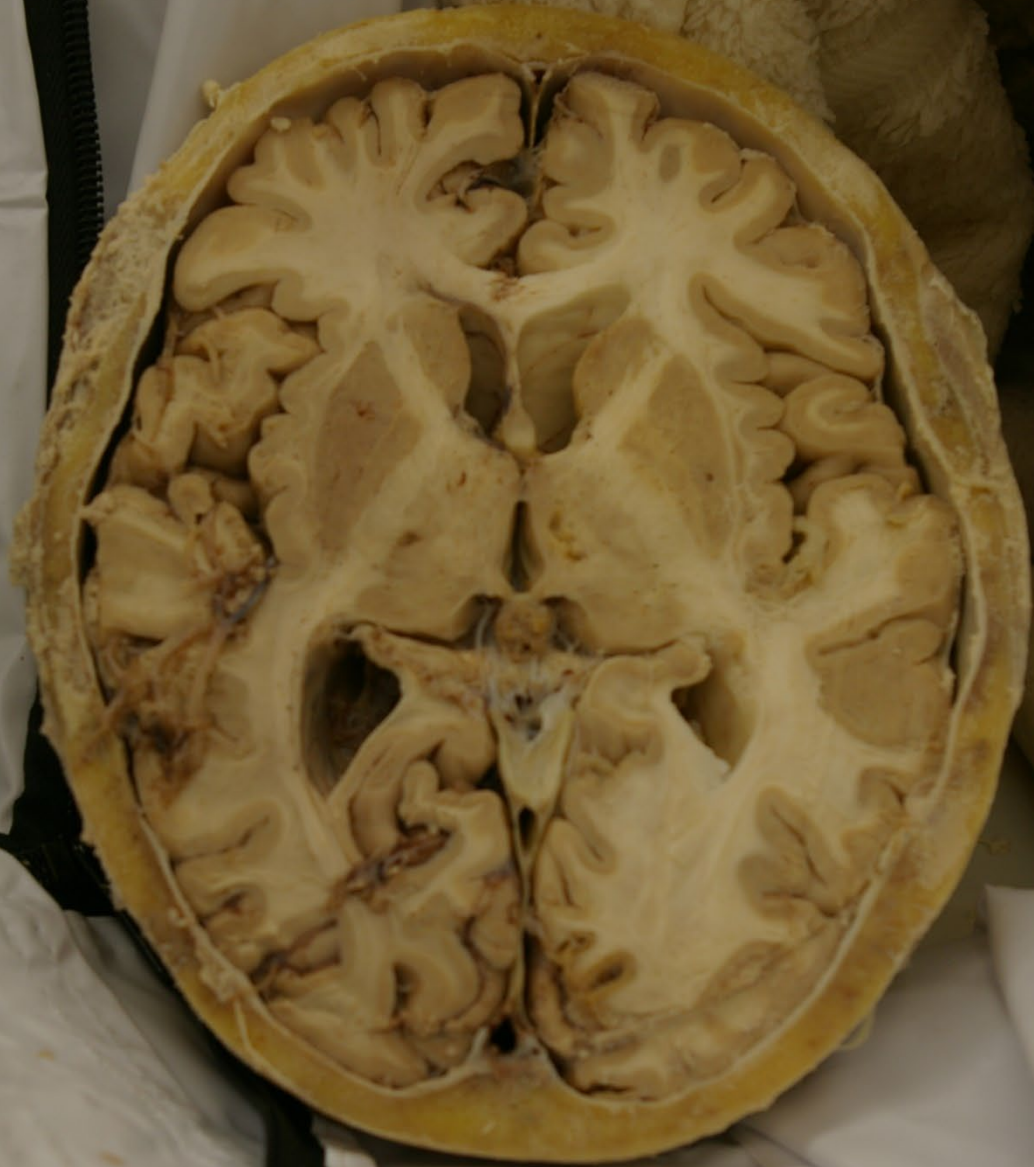COD: Cerebrovascular infarction

I

DT8



DT8



DT9

Office DEPOT®

DT 9

Sex: Female

Age: 88

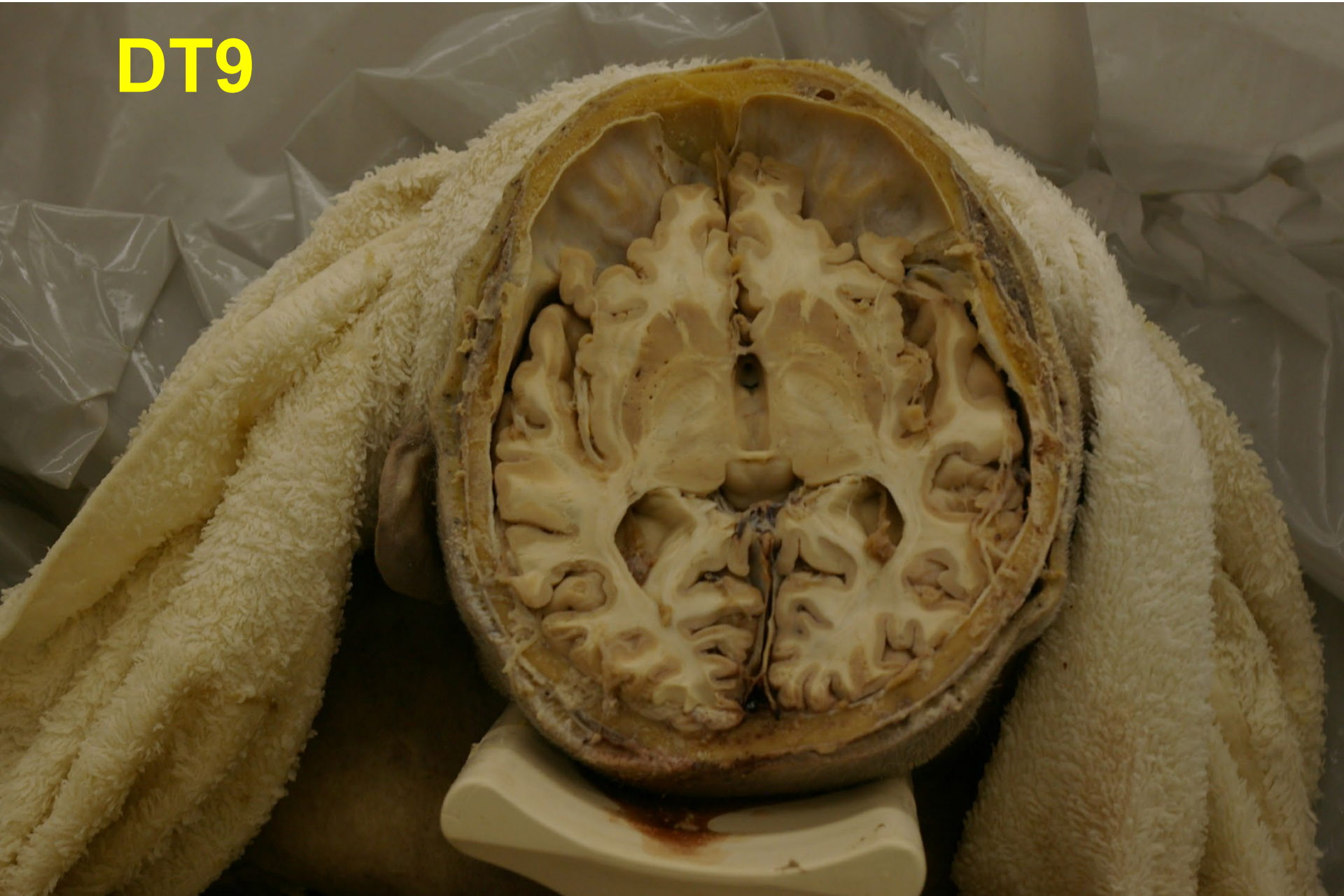SAB: 2023-276

COD: Cardiac Arrhythmia

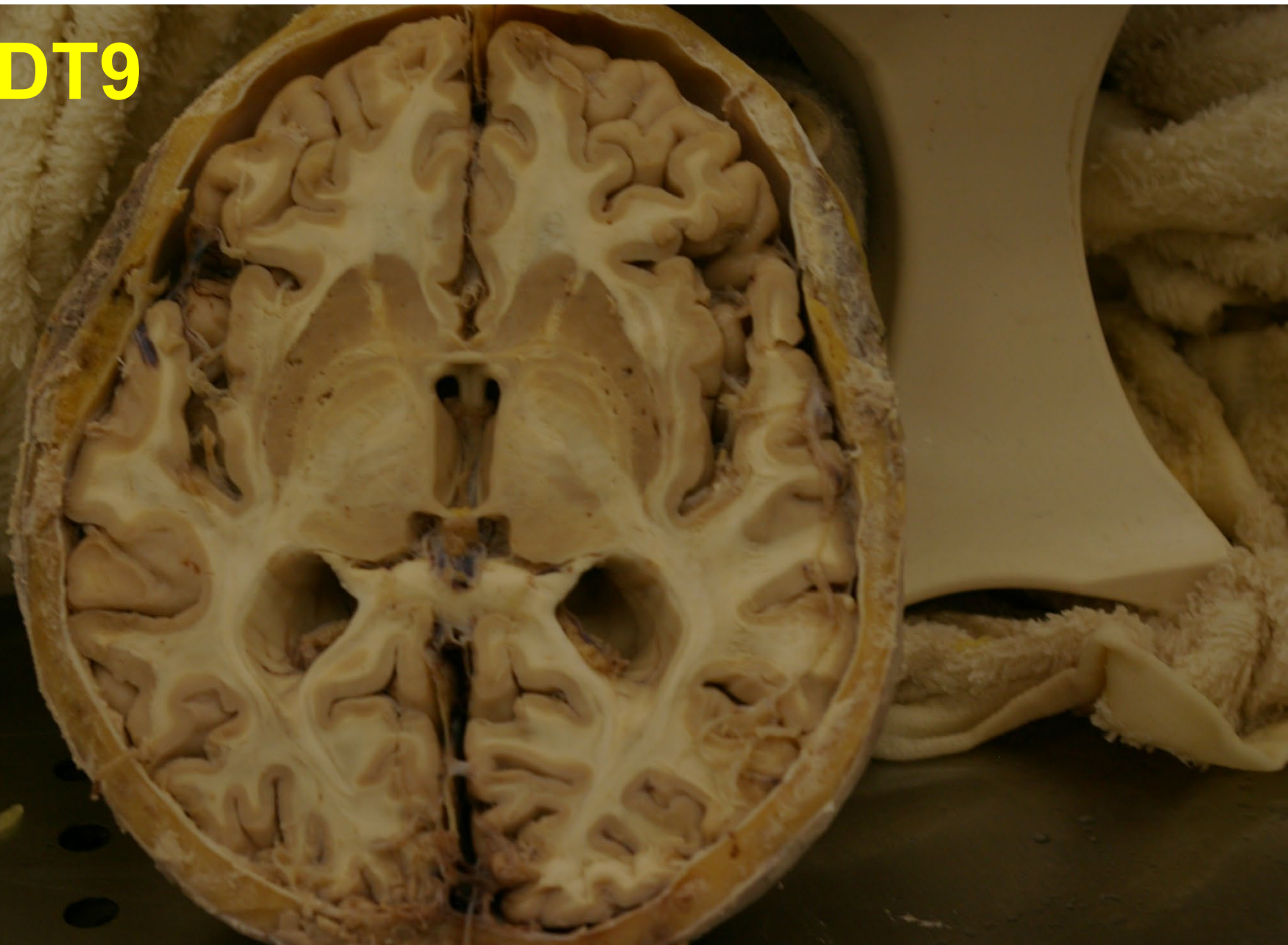
R

CAUTION

DT9



DT9



DT10

Office DEPOT®

DT 10

Sex: Male

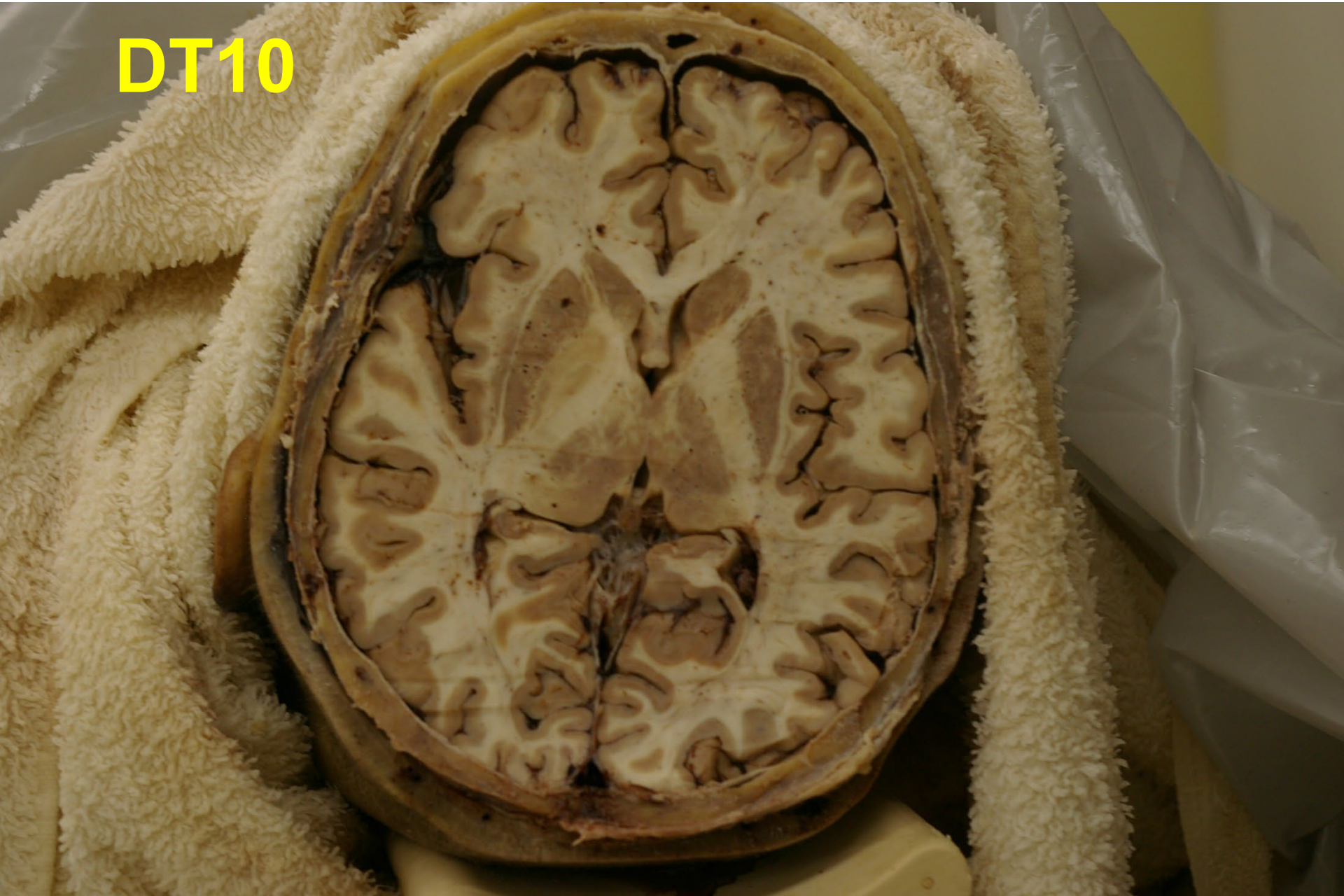Age: 68

SAB: 2023-137

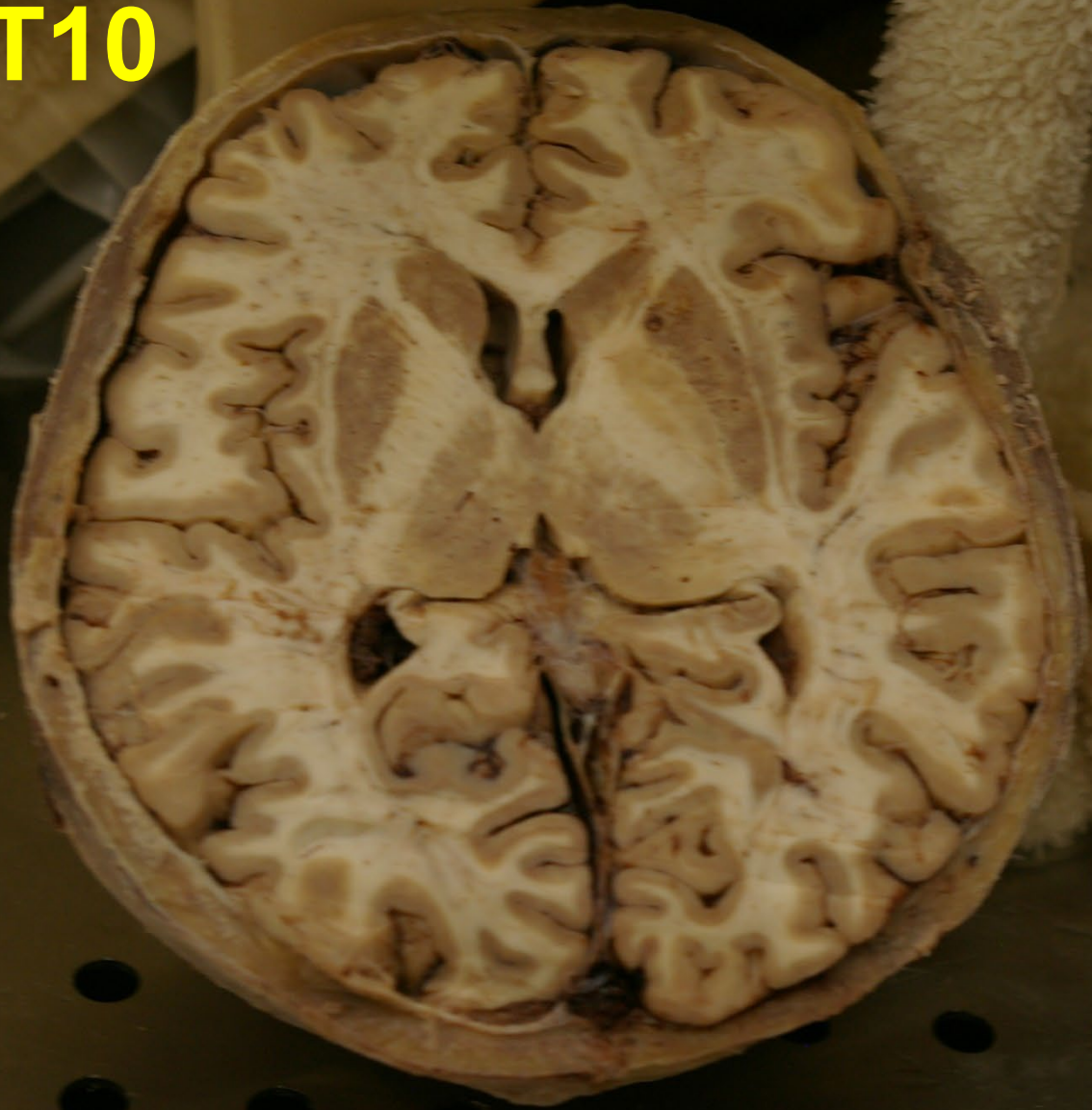COD: sudden cardiac arrest

I

DT10



DT10



DT11

Office DEPOT®

DT 11

Sex: Female

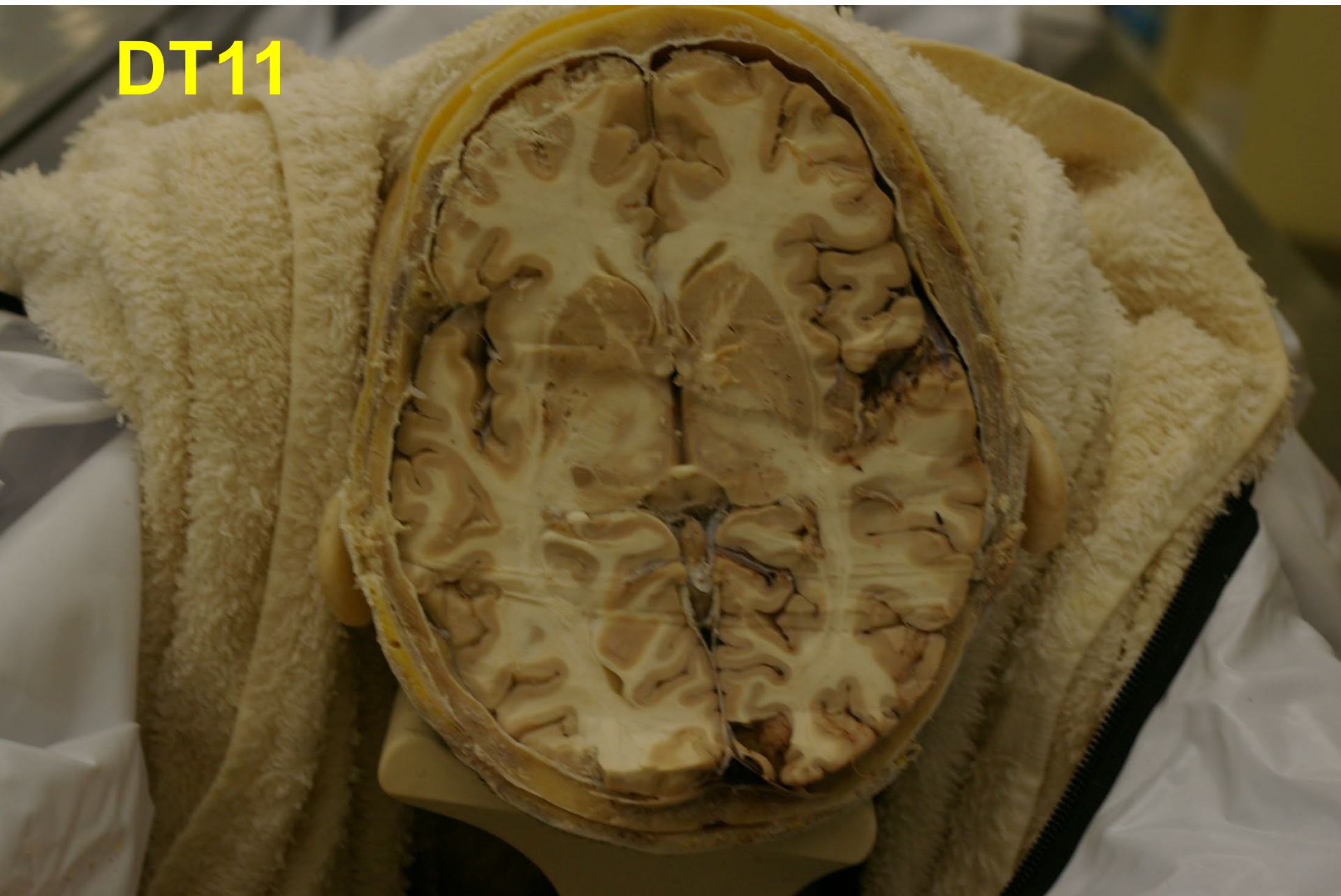Age: 72

SAB: 2023-341

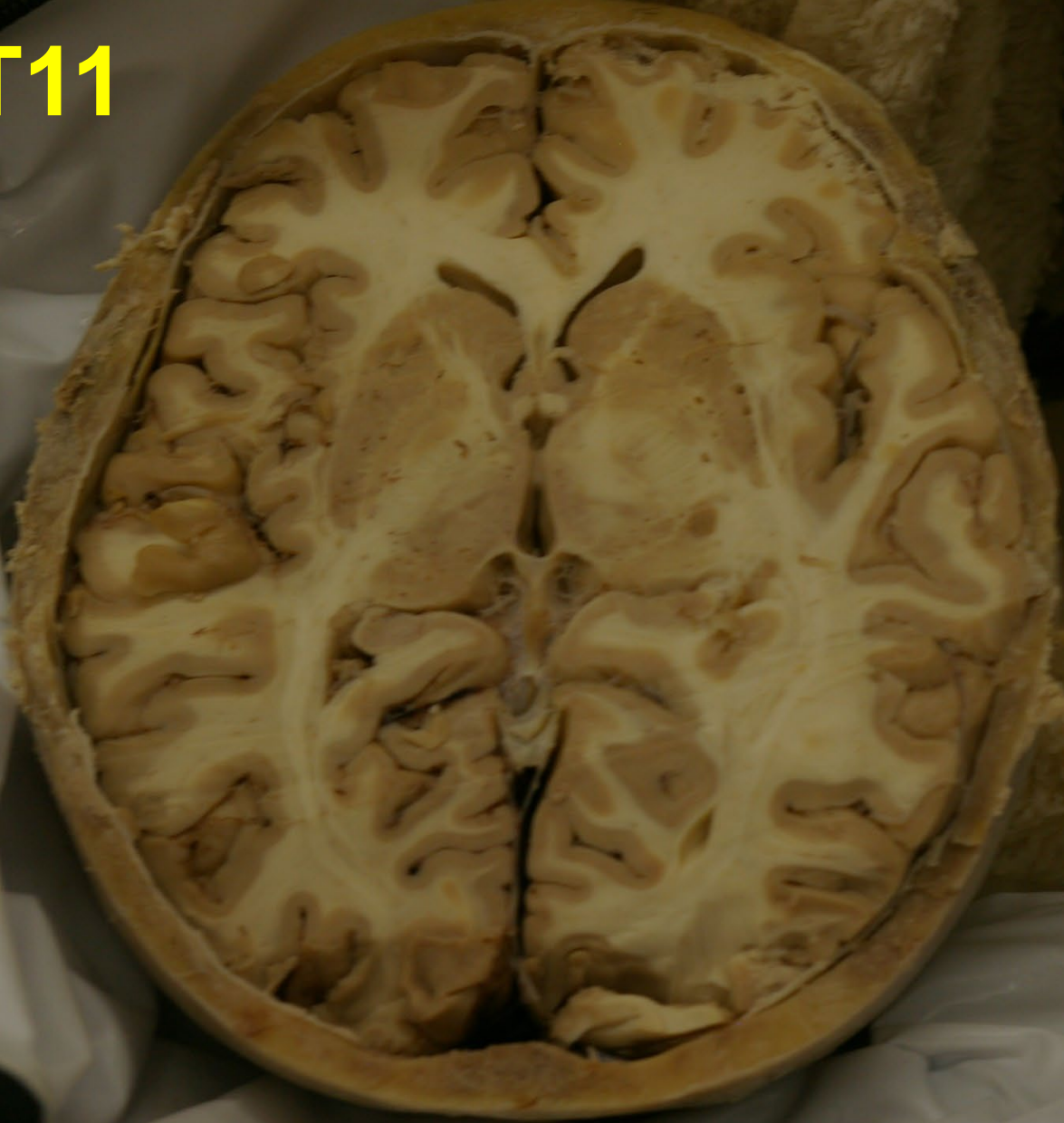COD: nonalcoholic steatohepatitis

I

DT11



DT11



DT12

Office DEPOT®

DT 12

Sex:

Male

Age:

68

SAB:

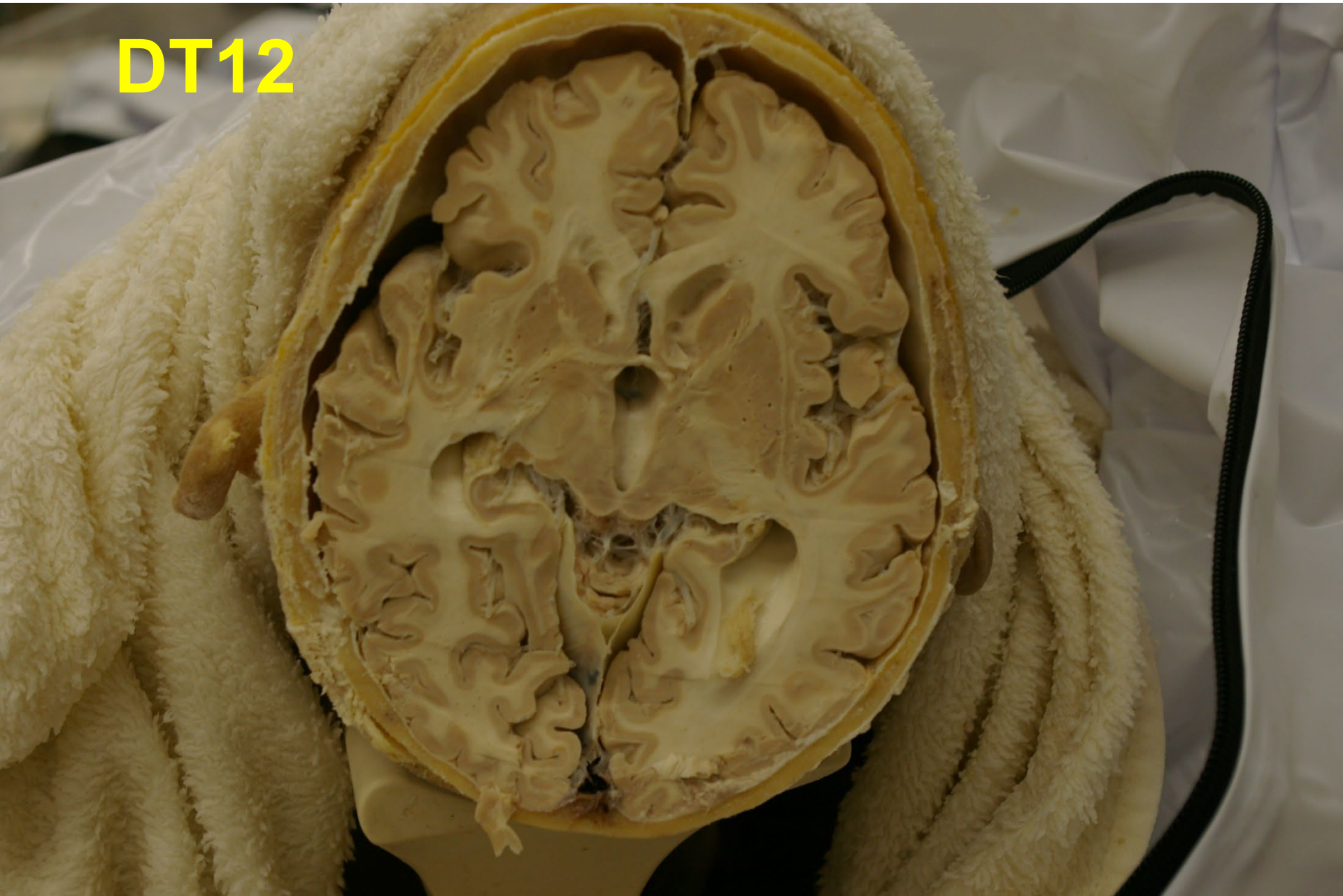
2023-349

COD:

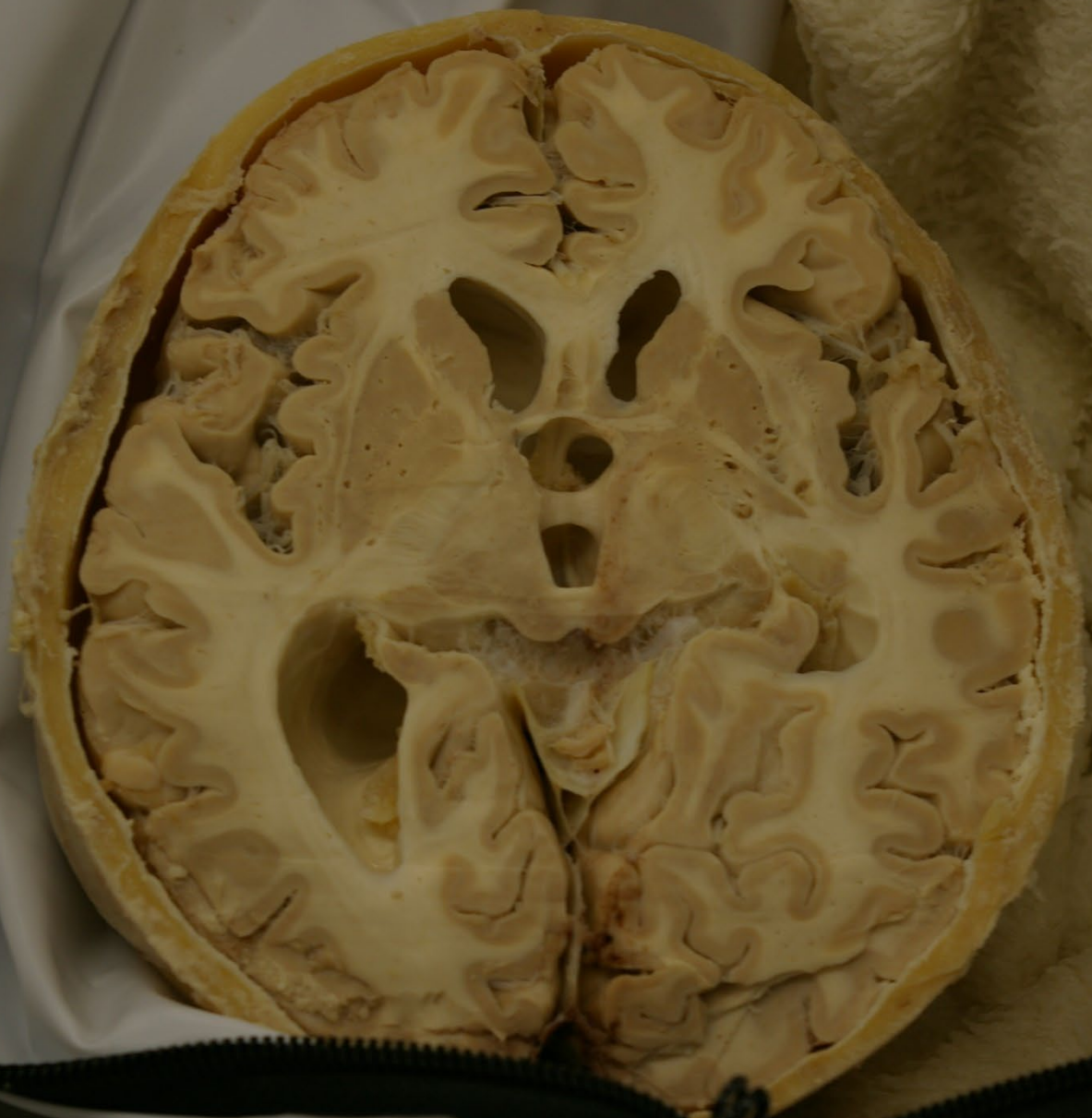
R

Amyotrophic Lateral Sclerosis

DT12



DT12



DT13

Office DEPOT®

DT 13

Sex: Male

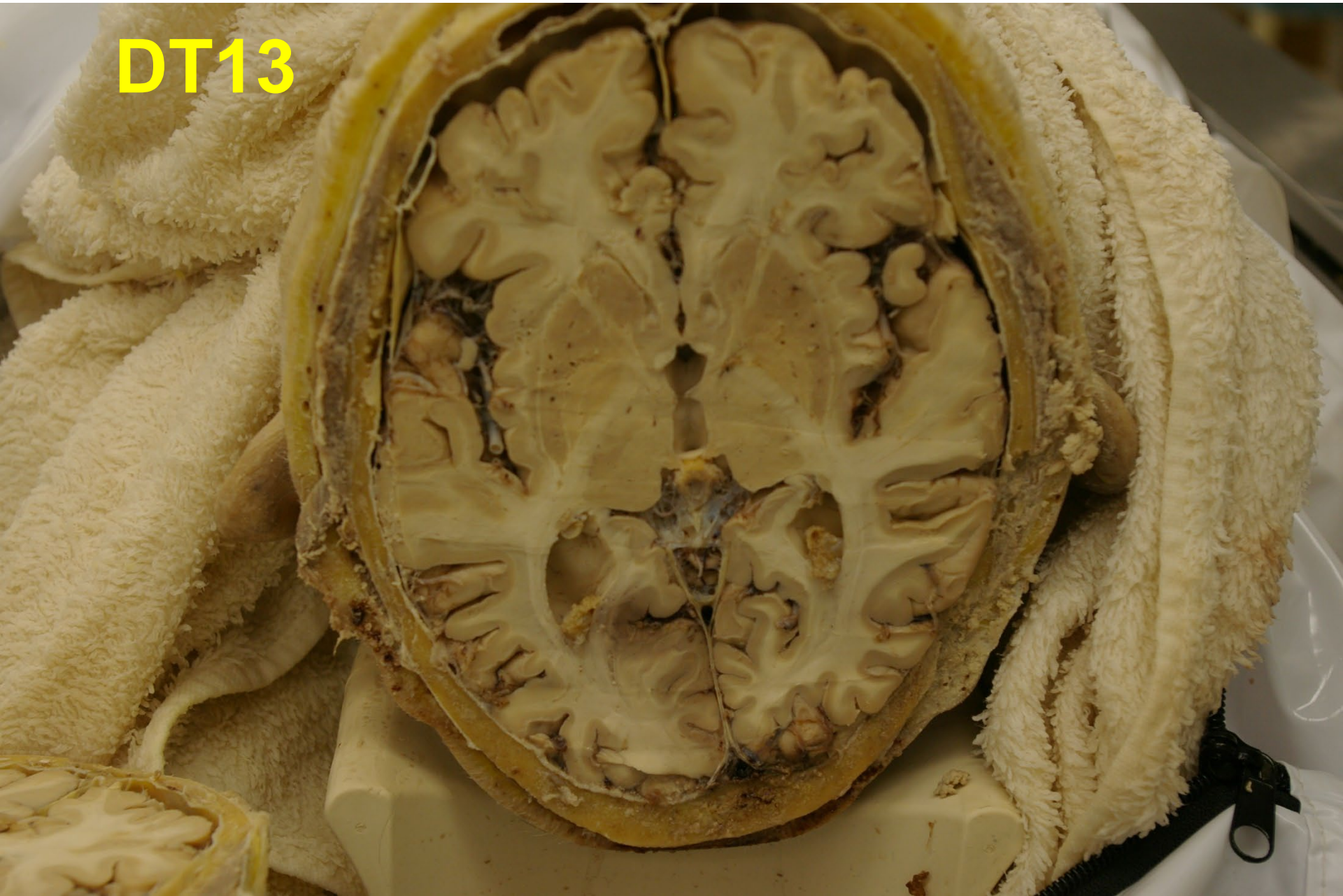
Age: 86

SAB: 2023-356

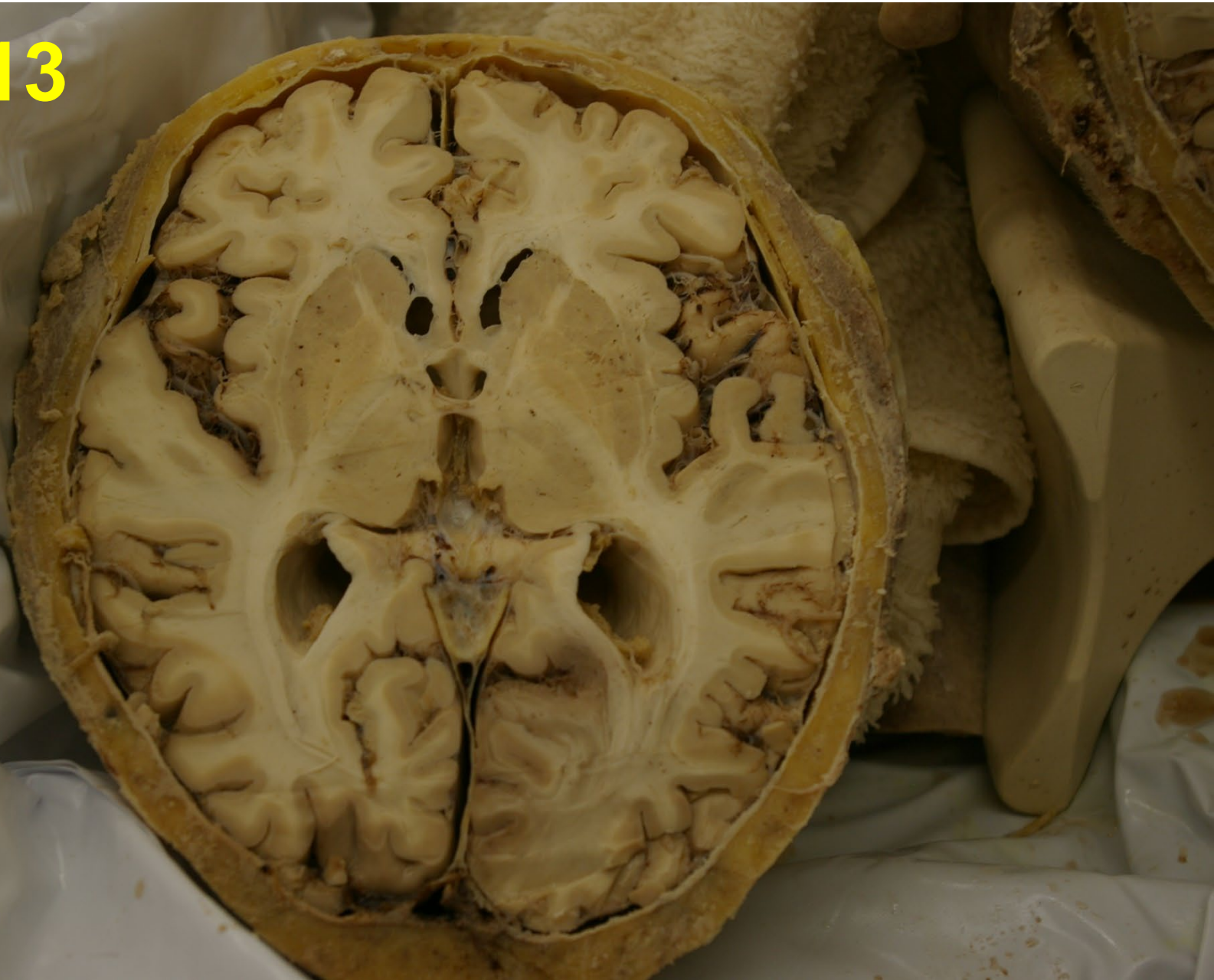COD: Acute Cerebrovascular Accident

I

DT13



DT13



DT14

Office DEPOT®

DT 14

Sex: Male

Age: 70

SAB: 2023-361

COD: Septic Shock due to pneumonia/
Acute Respiratory Failure

R

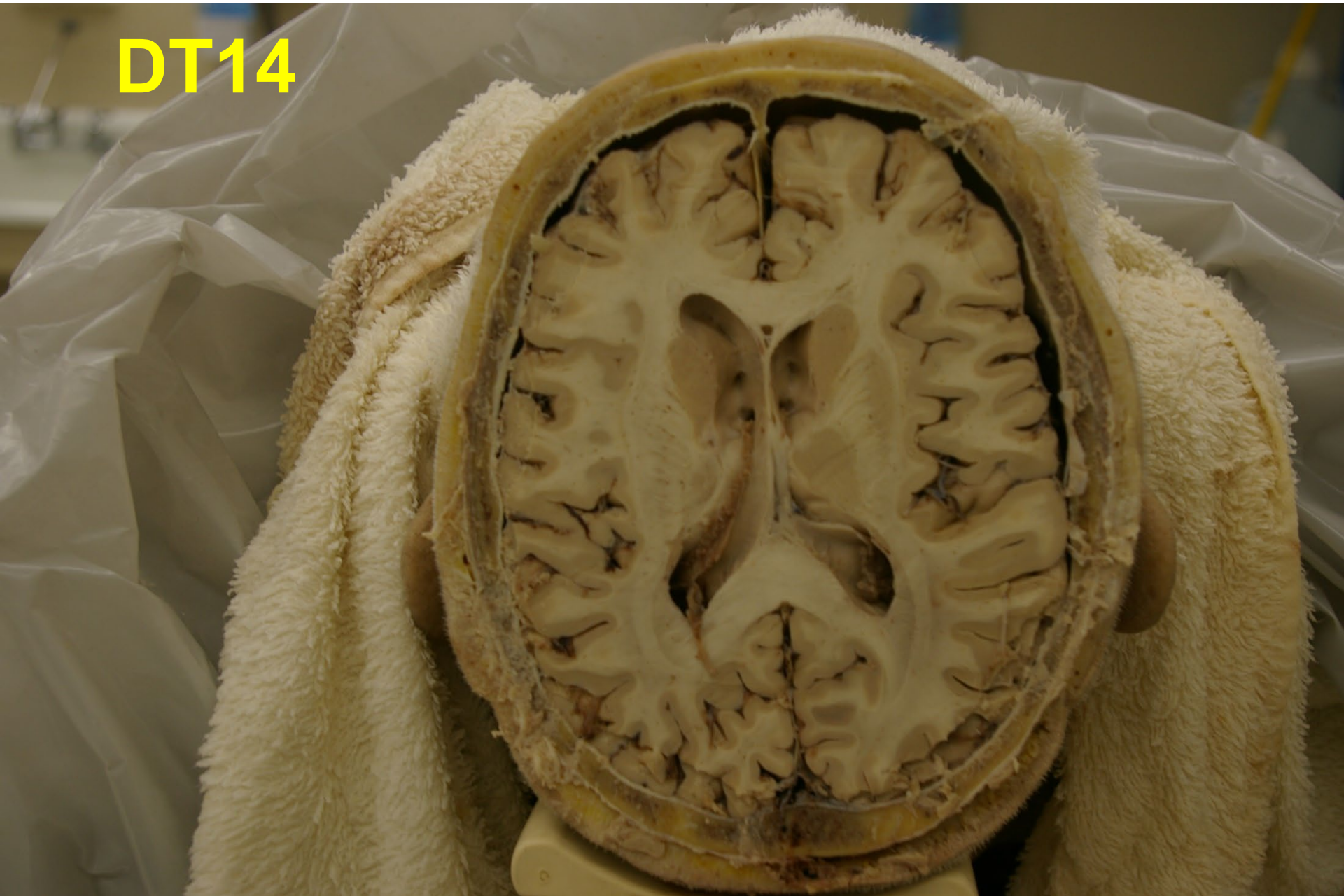CAUTION

HOLD HOOD FIRMLY WHEN
RELEASING LATCH.
FAILURE TO DO SO MAY
RESULT IN INJURY.

CAUTION

HOLD HOOD FIRMLY WHEN
RELEASING LATCH.
FAILURE TO DO SO MAY
RESULT IN INJURY.

DT14



DT14

