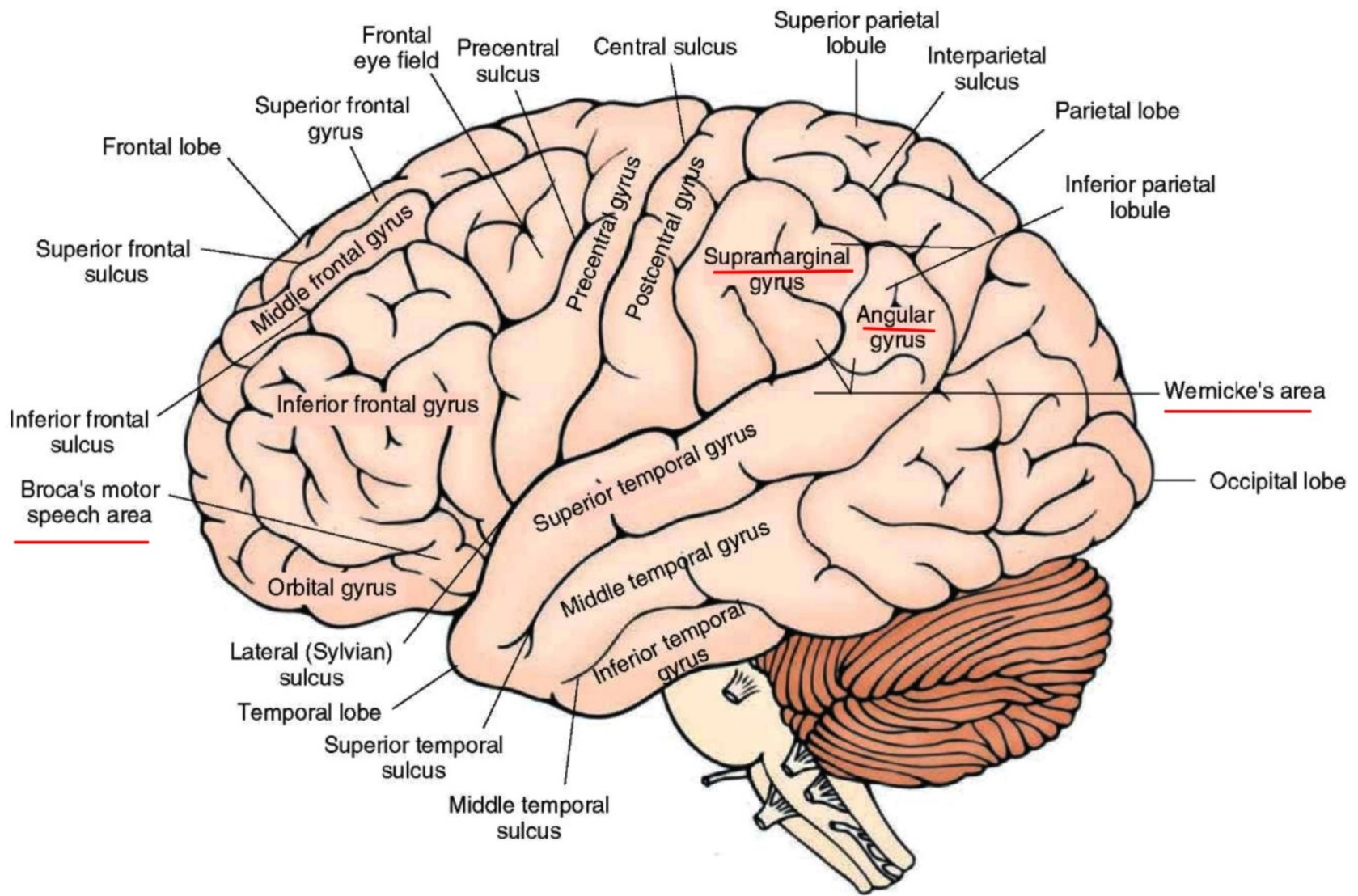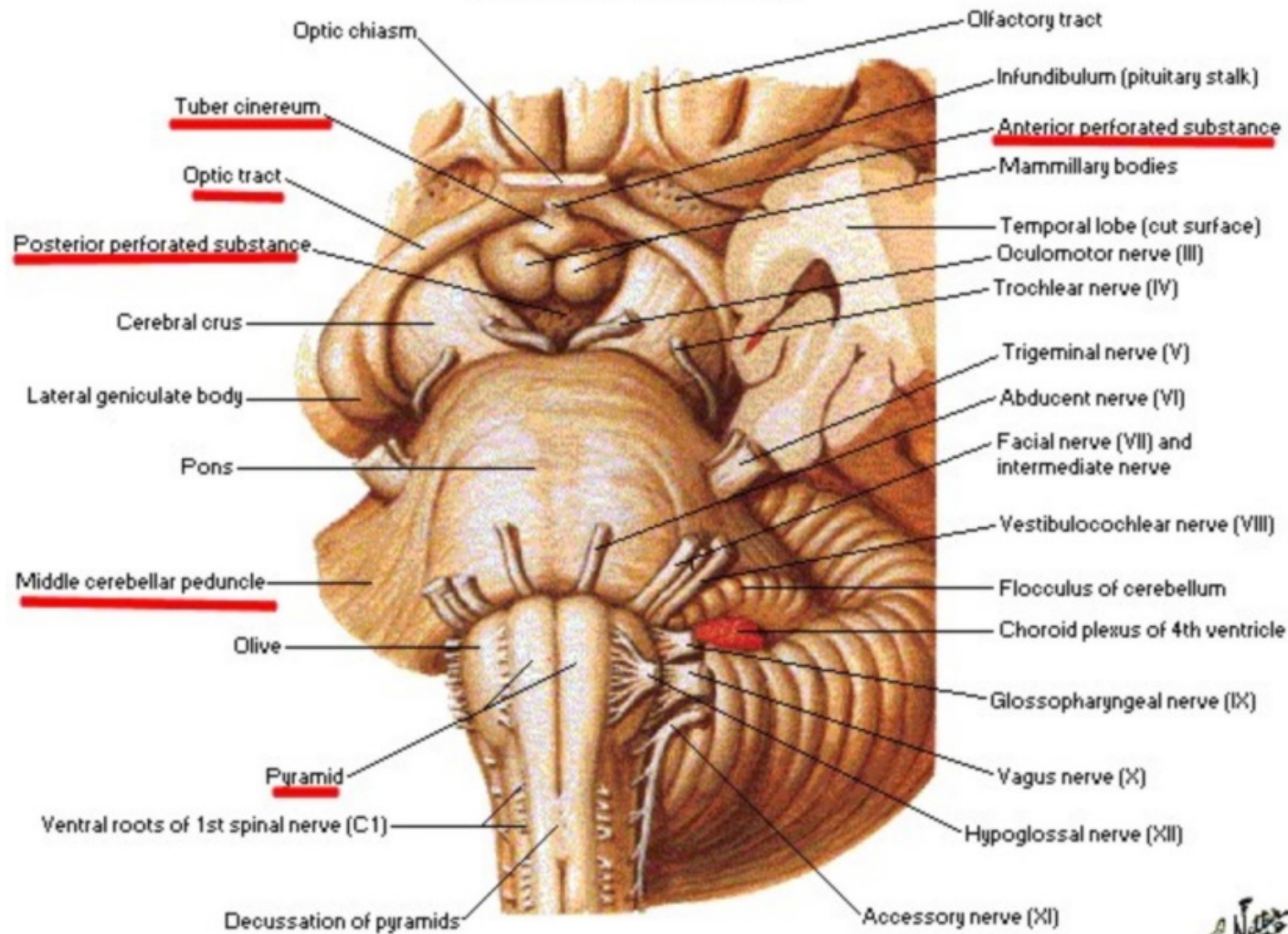
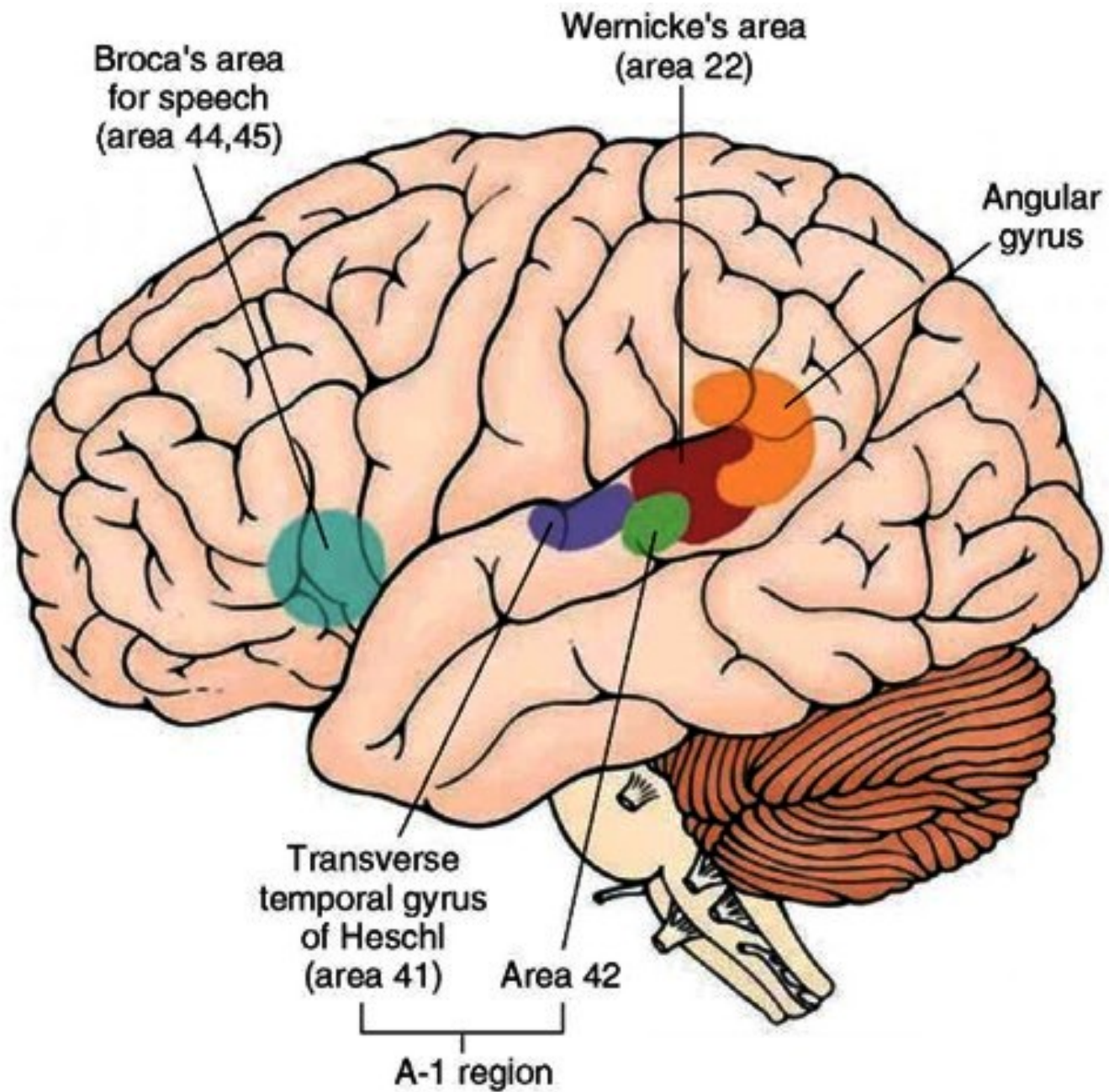
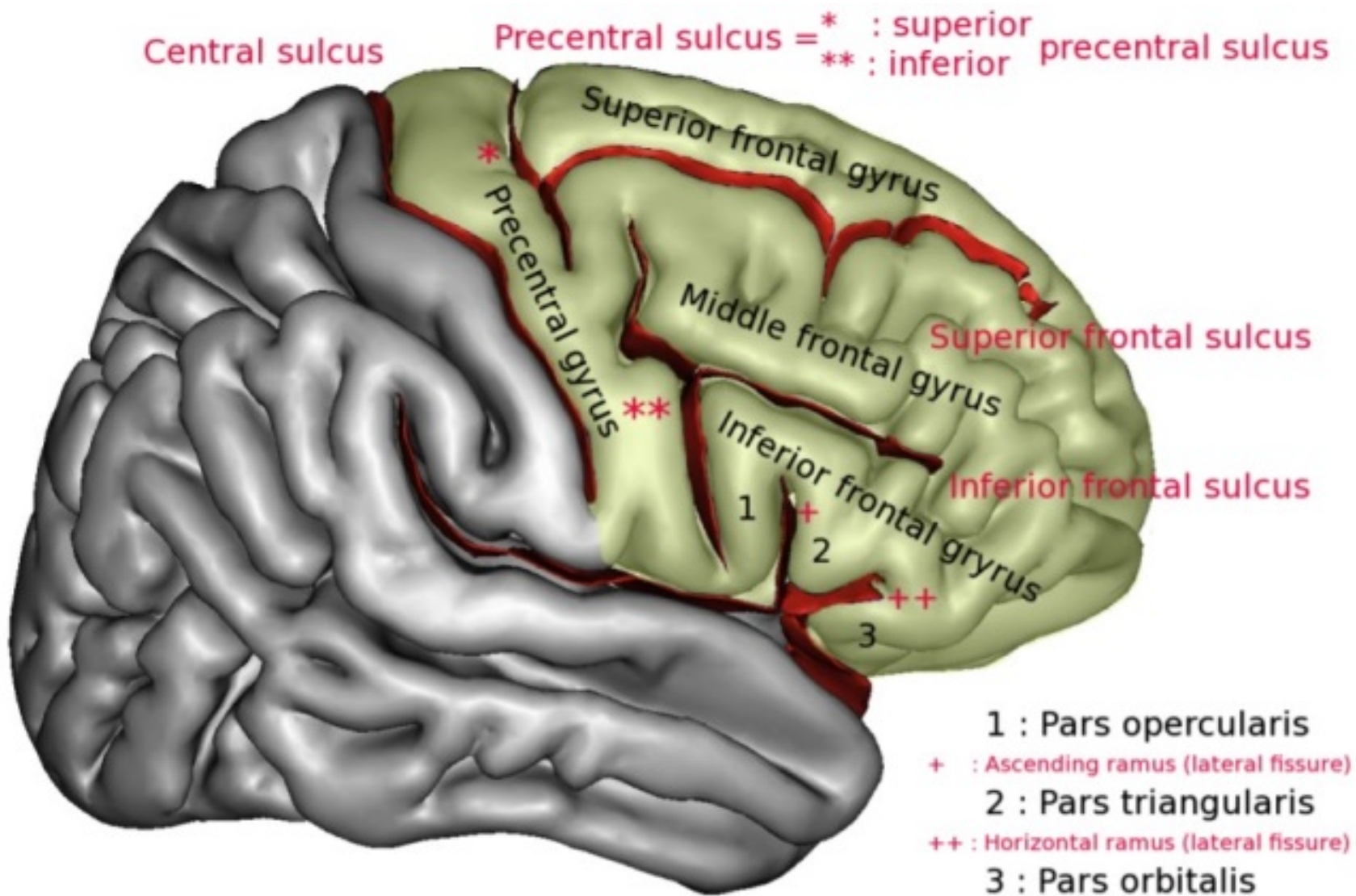


Brainstem

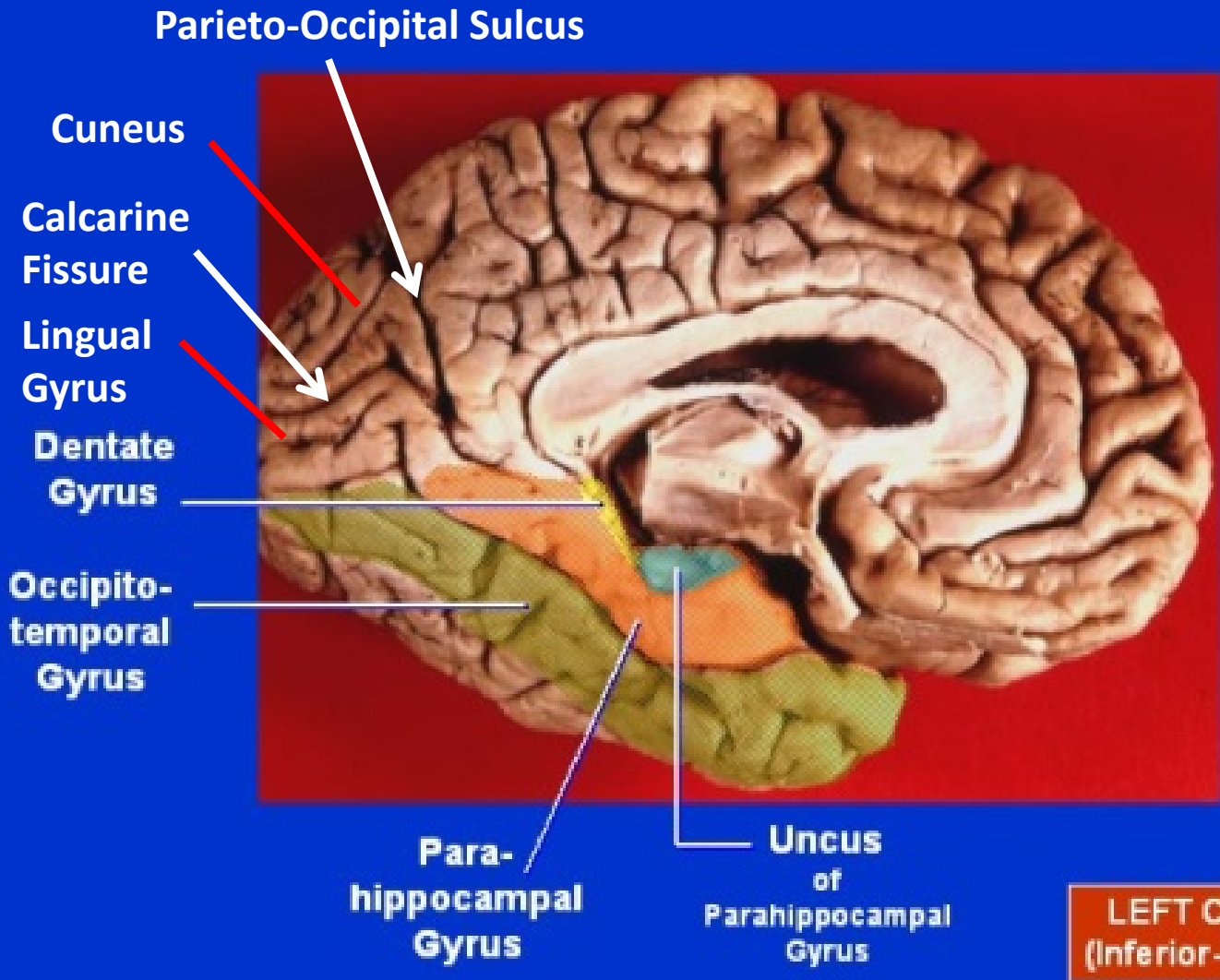
Anteroinferior View

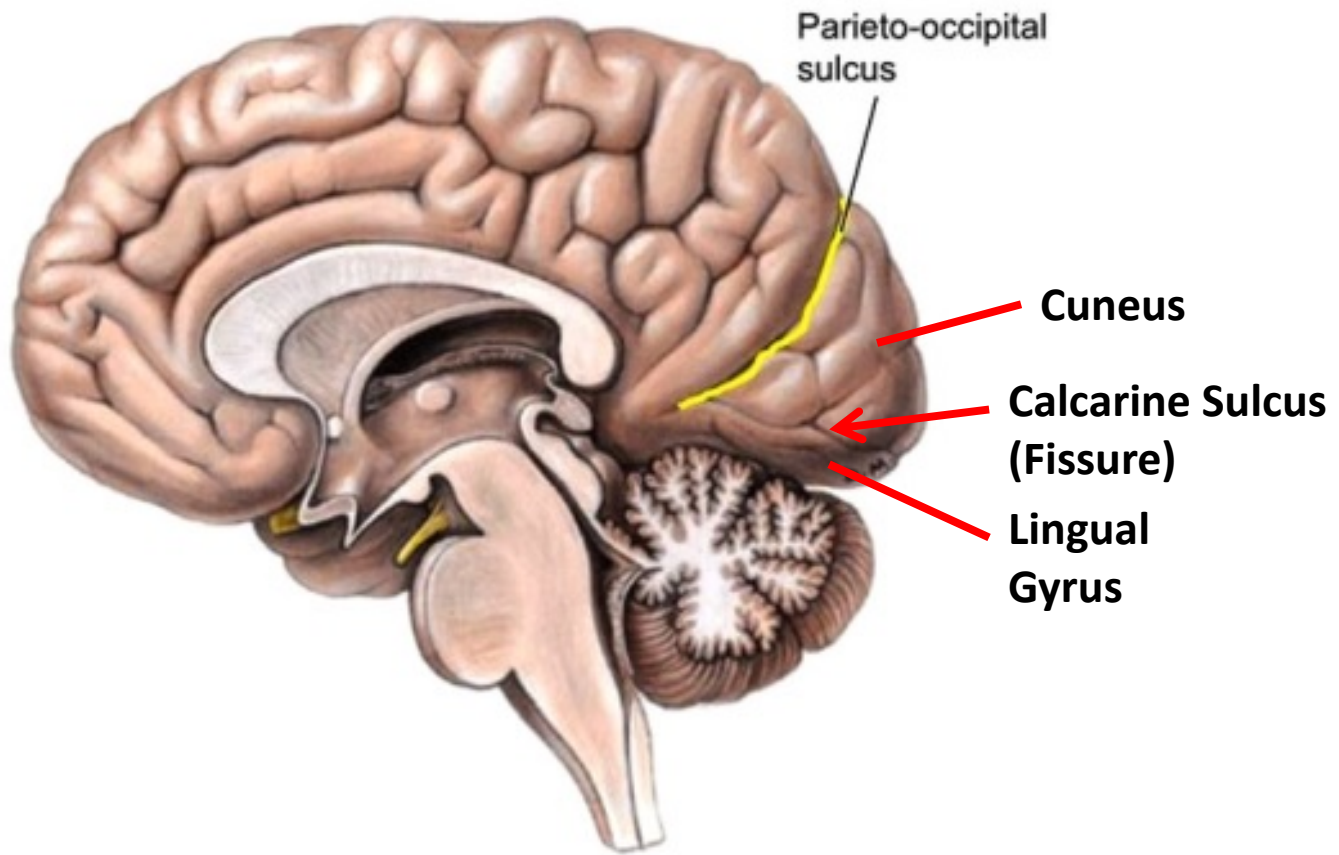


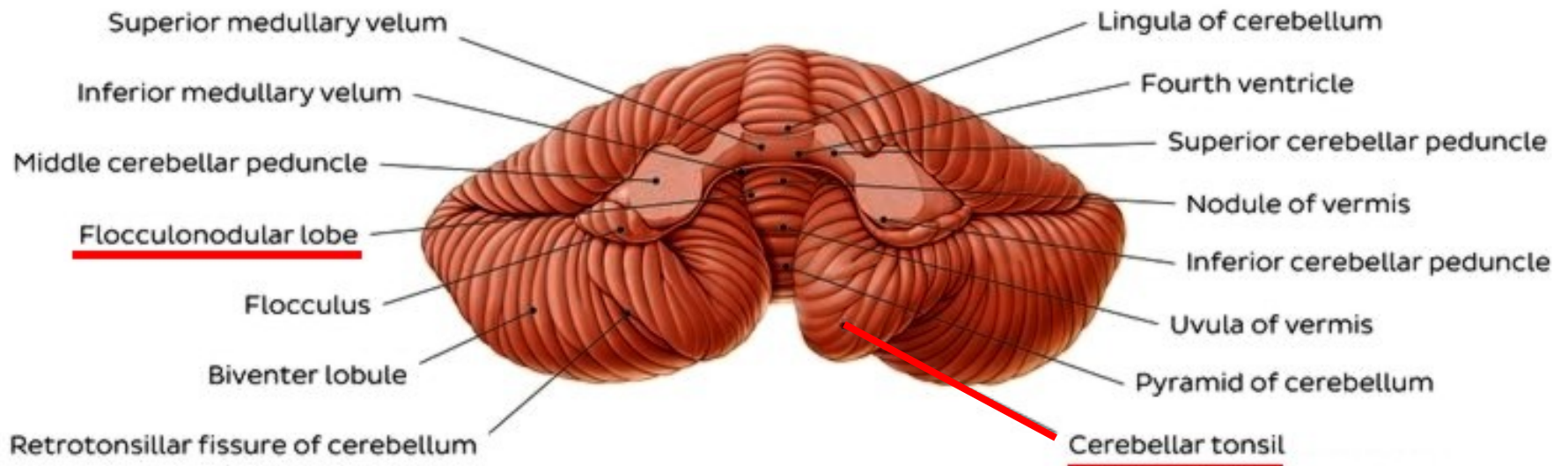
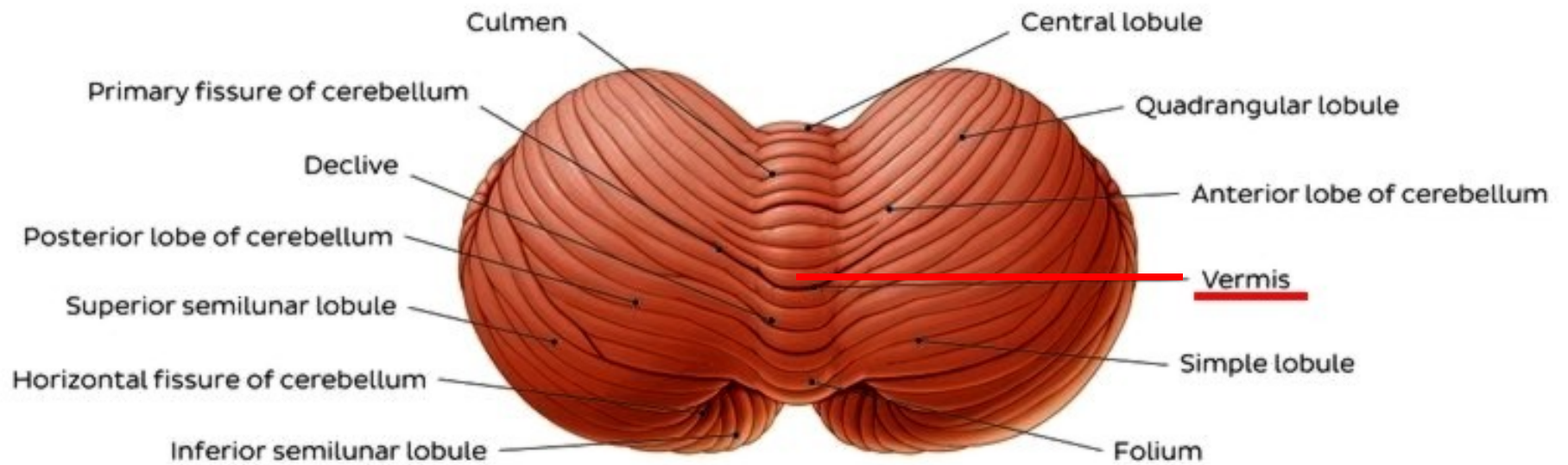


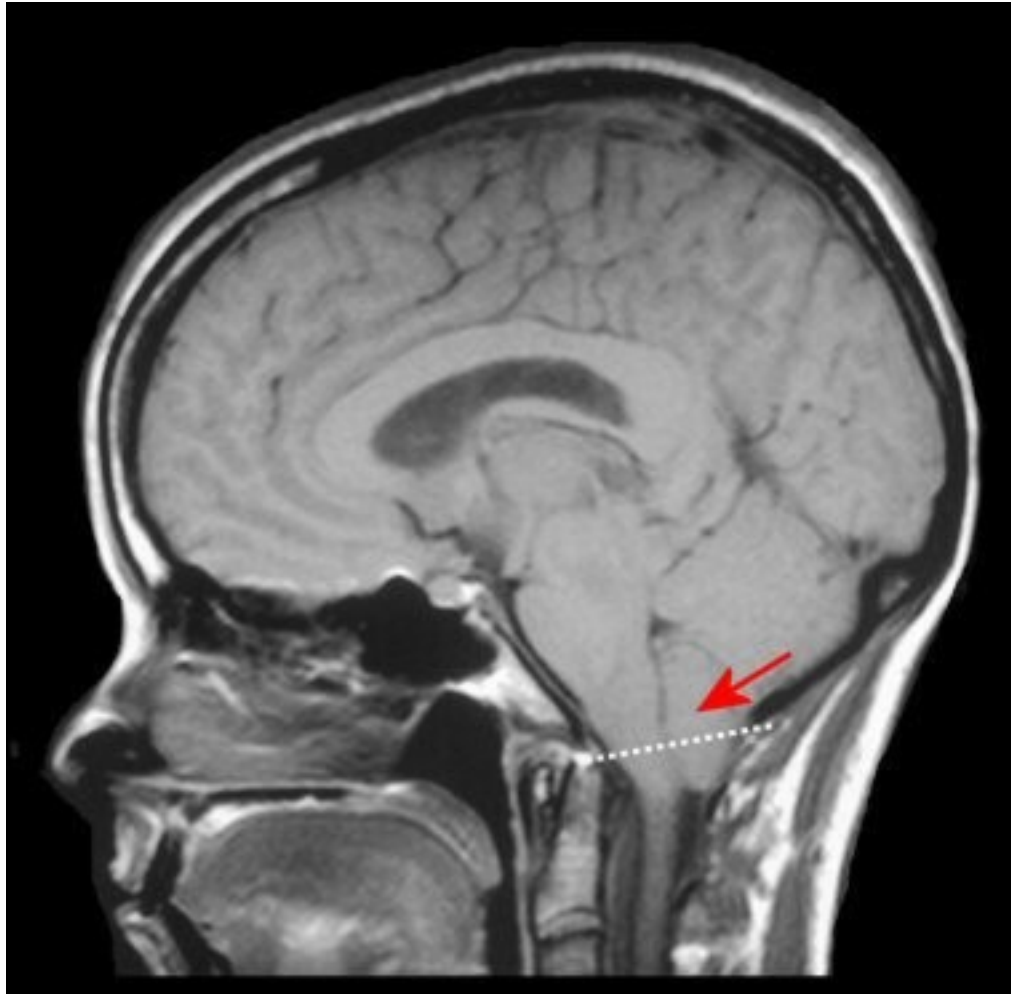

CEREBRAL GYRI









**tonsillar
herniation**

