CLINICAL ANATOMY OF HEAD AND NECK

Clinical	Anatomy	Cause	Sign/Symptom
Anterior Cranial Fossa - Cranial nerve I, Nasal Cavity			
Fracture of cribriform plate of ethmoid bone	Nasal septum continuous with crista galli of ethmoid bone; Olfactory nerve passes through cribriform plate of ethmoid bone	Blow to nose; fracture produces **continuity between subarachnoid space and nasal cavity**	**Leakage of CSF from nose** ('runny nose'); **Decreased sense of smell** (hyposmia)
Middle Cranial Fossa - Cranial nerves II-VI Orbit, Eye Movements, Face			
Rapid loss of vision in one eye	Central artery of retina (branch of Ophthalmic artery from Int. Carotid) is an normally an end artery with no functional anastomoses (exception: Chorioretinal anatomoses)	**Occlusion of Central Artery of Retina**	Sudden onset blindness in one eye (one eye only, sign: artery occlusion visible through ophthalmoscope)
Slow loss of vision in one eye	Dura mater and subarachnoid continue over optic nerve; **Optic nerve function affected by CSF pressure**	**Communicating hydrocephalus** (many causes)	Decreased visual function both eyes; sign: **papilledema** in ophthalmoscope view; also other signs of increased intracranial pressure (headache, etc.)
Abducens nerve palsy	Abducens nerve innervates only Lateral Rectus muscle (action: abduction of eye)	Damage Abducens nerve VI (causes ex. increased intracranial pressure, Cavernous sinus thrombosis)	**Diplopia and Medial strabismus**
Trochlear nerve palsy	Trochlear nerve innervates only Superior Oblique muscle (action: abduct, depress and medially rotate eye)	Damage Trochlear nerve (ex. trauma)	**Inability to look down and out** (difficulty walking down stairs); **Head tilted toward side opposite lesion**
Oculomotor nerve palsy	Oculomotor nerve innervates Superior, Medial and Inferior Rectus and Inferior Oblique; part of Levator palpebrae superioris; also provides parasympathetics to pupillary constrictor, ciliary muscles	Damage Oculomotor nerve (frequently idiopathic)	**Lateral strabismus, dilated pupil, ptosis; also loss of accommodation (near vision) due to paralysis of ciliary muscles**

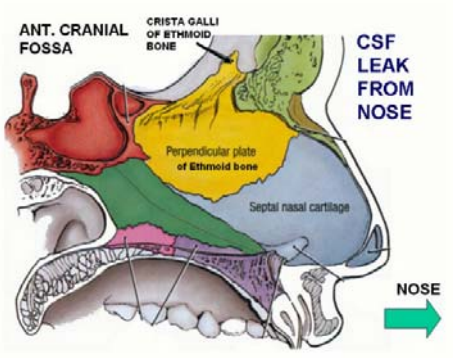

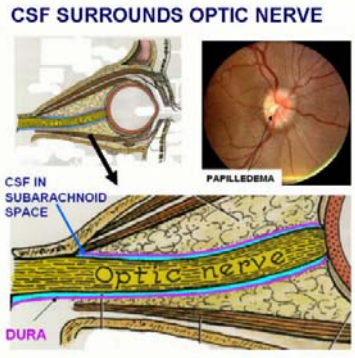

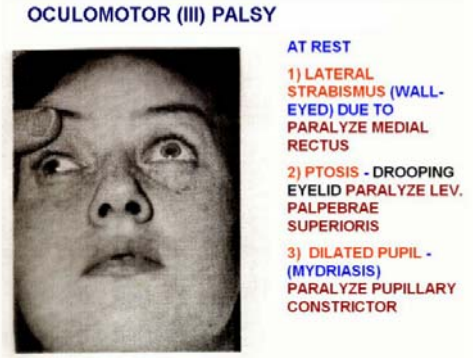

Clinical	Anatomy	Cause	Sign/Symptom
Middle Cranial Fossa - Cranial nerves II-VI Orbit, Eye Movements, Face (cont.)			
Horner's Syndrome	Sympathetics in head innervate smooth muscle part of Levator Palpebrae Superioris; Pupillary Dilator muscle; sweat glands of skin; **Pathway**: pre-ganglionic neurons out cord at T1,2; ascend in chain; post-ganglionics in Sup. Cerv. Ganglion; distributed with arteries (ex. Ophthalmic A.)	Block conduction in Sympathetics to head (tumors, etc)	**Ptosis (**drooping eyelid from smooth muscle part of Levator Palpebrae Superioris); **Constricted pupil** (miosis due to paralyze Dilator pupillae); **Anhydrosis** of forehead (denervate sweat glands)
Cavernous sinus thrombosis	Branches of cranial nerves (III, IV, V1, V2, VI) and Internal Carotid artery pass through wall of Cavernous sinus; Cavernous sinus drains ophthalmic veins which anastomose with branches of Facial Vein; veins have no valves	ex. **Infection in cav. sinus spread from infection of face** (angle of nose or upper lip particularly dangerous)	**Diplopia** (blurred vision) due to disruption of eye movements; increased venous pressure produces **engorgement in veins of retina (view in ophthalmoscope) +other symptoms**
Epidural Hematoma	**Middle Meningeal artery** (branch of Maxillary artery that passes through foramen spinosum) supplies bone of calvarium	**Blow to side of head (fracture skull in region of pterion)**	Patient conscious after accident; loses consciousness within hours; coma, death (Note: **hematoma is lens-shaped** on CT)
Subdural Hematoma	**Bridging veins** link Superficial cerebral veins on surface of brain and Superior Sagittal sinus (also other venous sinuses)	**Blow to head; in elderly can occur without distinct event**	**Slow onset** of neurological symptoms, headache (often hours to days) (Note: **hematoma is crescent-shaped** on CT)
Communicating Hydrocephalus due to decreased CSF reabsorption	CSF produce in choroid plexus; reabsorbed from subarachnoid space at arachnoid villi into venous sinuses	In elderly, **Calcification of arachnoid villi** (arachnoid granulations)	**Headache, papilledema**

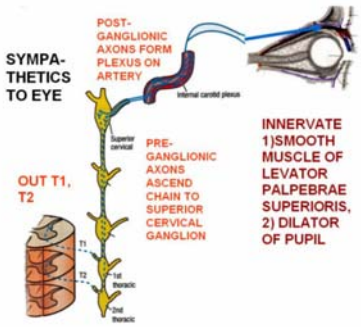

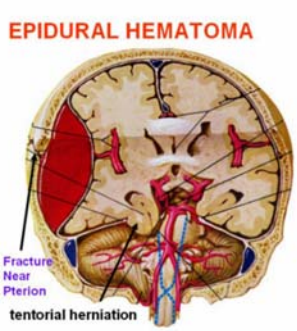

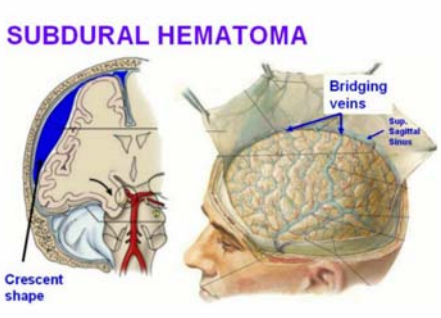

Clinical	Anatomy	Cause	Sign/Symptom
Middle Cranial Fossa - Cranial nerves II-VI Orbit, Eye Movements, Face			
Numbness of regions of face	V is major sensory nerve of face and head; **Sensory neuron cell bodies** are in **Semilunar (Trigeminal) Ganglion**; V1 above lateral margin eyelids; V2 eyelids to upper lip; V3 below lateral margins of lips	Many; ex. Trigeminal Anesthesia	Numbness in specific region can be **correlated with specific division of V**
Pain in external auditory meatus following Facial paralysis	Skin of ear and external auditory meatus receive sensory innervation from V, VII, IX and X	**Bell's palsy**	Ear ache (following or accompanying Facial paralysis)
Weakness of muscles mastication	Muscles mastication innervated by V3; Lateral Pterygoid opens mouth; all other muscles Mastication close mouth	ex. **Tumor at foramen ovale**	When open mouth, **jaw deviates toward paralyzed side**
Posterior Cranial Fossa - Cranial Nerves VII-XII, face, ear, pharynx, tongue			
Facial paralysis (with effect on VIII)	CN VII and VIII exit post. cranial fossa via Internal auditory meatus; VIII ends in temporal bone; VII enters facial canal and gives off branches in temporal bone; 1) parasymp. to Lacrimal gland, mucous glands of nose, palate; 2) Nerve to Stapedius muscle; 3) Chorda tympani - taste to ant. 2/3 of tongue; parasymp. to Submandibular, Sublingual salivary glands	**Acoustic neuroma**	Loss or reduction of hearing in one ear; **Full Facial nerve palsy (Bell's palsy)** symptoms: 1) **Facial paralysis and loss of Corneal reflex** (V1 sensory, VII motor) 2) **Loss of taste to ant. 2/3 of tongue** 3) **Decreased secretion tears and saliva** 4) **Hyperacousia**
Facial paralysis (no effect on VIII)	Facial nerve exits skull via Stylomastoid foramen; only has motor branches after leaving skull	**Parotid tumor**	**Facial paralysis**; Loss of corneal reflex but **no loss of taste or decrease in tears or saliva; no hypercousia**

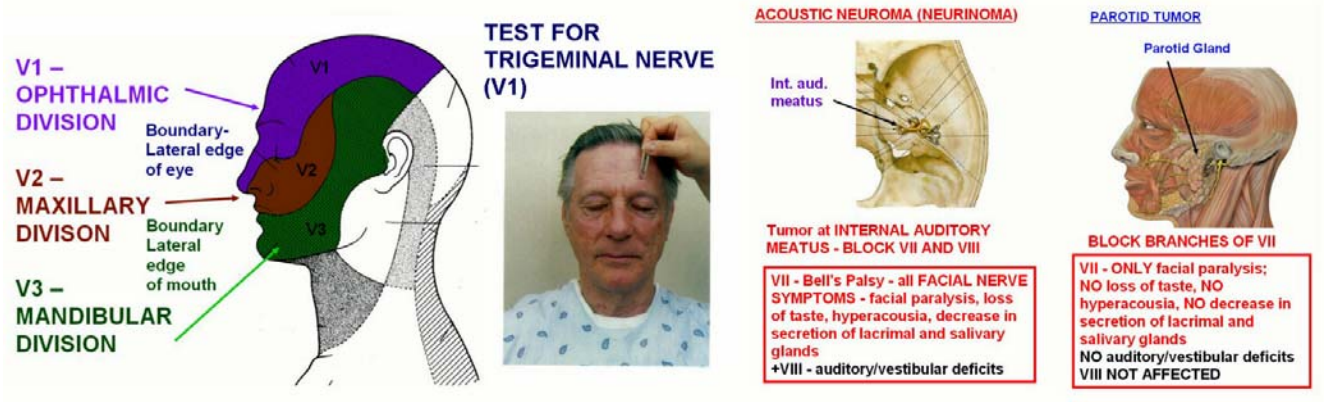

Clinical	Anatomy	Cause	Sign/Symptom
Posterior Cranial Fossa - Cranial Nerves VII-XII, face, ear, pharynx, tongue (cont.)			
Loss of function of IX and X	IX is major sensory nerve to pharynx (oropharynx); X is motor to all muscles of pharynx except Stylopharyngeus; all muscles of palate (except Tensor palati)	**Tumor at Jugular Foramen**	Difficulty in swallowing; **Absence of Gag Reflex**; (Gag reflex - IX sensory, X motor) **Uvula deviates away from side of lesion (Lower Motor Neuron Lesion X)**
Hoarse voice after thyroid surgery	X is motor to all muscles of larynx; also sensory to larynx; Recurrent Laryngeal nerve passes posterior to Thyroid gland with Inf. Thyroid artery; motor to all laryngeal muscles except Cricothyroid	**Damage Recurrent Laryngeal nerve during Thyroid surgery**	Hoarse voice due to **unilateral paralysis of all laryngeal muscles (except Cricothyroid)**
Torticollis	XI innervates Sternocleidomastoid and Trapezius	Torticollis can be congenital or acquired	Contracture of Sternocleidomastoid - head is rotated with face directed to opposite side (Note: **Trapezius - clinical test for XI - shrug shoulders**)
Paralysis of muscles of tongue	XII is motor to all muscles of tongue (no sensory component)	XII hypoglossal nerve palsy	Atrophy of muscles of tongue on one side; **protruded tongue deviates toward side of lesion due to Genioglossus) in Lower Motor Neuron Lesion**

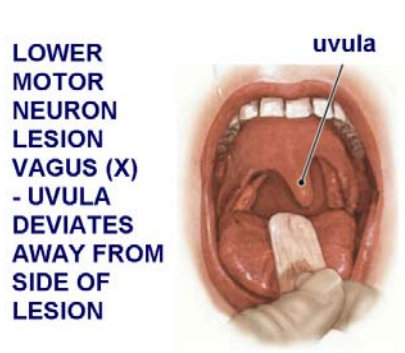

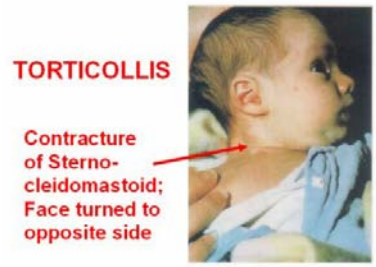

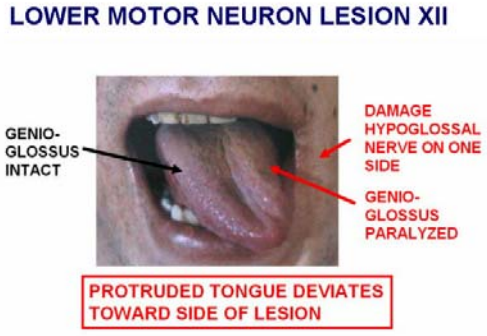

HEAD AND NECK ANATOMY PRACTICE QUESTIONS

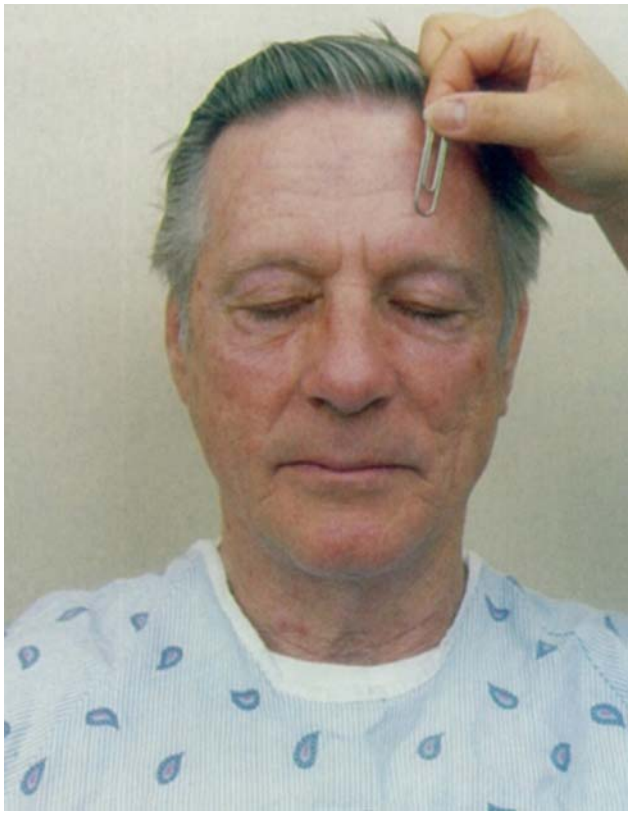

1. _____ A patient complains that he has lost sensation on his face and that the skin of his face feels numb. The physician tests tactile acuity by touching the forehead (see photo above) and finds severe loss of sensation. Which of the following is the location of the sensory neuron cell bodies that innervate this area?

A. Mesencephalic nucleus of V
B. Semilunar (Trigeminal) ganglion
C. Geniculate ganglion
D. Ciliary ganglion
E. Pterygopalatine ganglion

A person is in an automobile accident and gets struck on the side of the head. The patient refuses to be taken to the hospital and instead demands to simply go home and lie down for a while. Within hours, the person is rushed to the hospital after losing consciousness. The image above is a CT scan section at the level of the cranial cavity.

2. _____ The physician suspects that this is a hematoma that has resulted from tear of a vascular structure. Which of the following describes the type of hematoma and the vascular structure that was damaged?

A. Subdural hematoma, ophthalmic artery
B. Subdural hematoma, middle meningeal artery
C. Epidural hematoma, ophthalmic artery
D. Epidural hematoma, middle meningeal artery
E. Epidural hematoma, deep temporal artery

3. _____ This artery is a branch of the

A. Internal Carotid Artery
B. Superficial Temporal Artery
C. Occipital Artery
D. Maxillary Artery
E. Facial Artery

A patient sees a physician because the eyelid of her left eye is drooping and she is having double vision. Examination of the patient (photo above) shows ptosis of the left eyelid and deviation of the left eye when the patient is told to look straight ahead. Further examination demonstrates that pupil is dilated in the left eye.

4. _____ Which of the following nerves is likely to have been damaged?

A. Trochlear
B. Abducens
C. Oculomotor
D. Facial
E. Ophthalmic division of the Trigeminal (V1).

5. _____ The ptosis is likely to be due to partial paralysis of which of the following muscles?

A. Superior oblique
B. Levator Palpebrae Superioris
C. Frontalis
D. Superior Rectus
E. Orbicularis Oculi

6. _____ The pupil is dilated because the action of the dilator pupillae muscle is unopposed. Which of the following is the innervation of the dilator pupillae muscle?

A. Sympathetic fibers
B. Facial nerve
C. Infraorbital nerve (V2)
D. Trochlear nerve
E. Optic nerve

A teenager patient develops a pimple on the face lateral to the nose and scratches the sore. In time, the sore becomes infected but remains untreated. The patient then develops neurological symptoms and has the major complaint of ‘blurred vision’ which is diagnosed as Diplopia.

7. _____ The physician suspects that the infection has spread to a structure inside the cranial cavity. Which of the following is likely to be the structure and the route by which the infection has spread?

A. Superior Sagittal sinus, 'bridging' veins
B. Inferior Petrosal sinus, middle meningeal vein
C. Cavernous sinus, ophthalmic veins
D. Transverse sinus, mastoid veins
E. Cavernous sinus, retromandibular veins

8. _____ The blurred vision is likely result from compromised function of which of the following?

A. optic nerve (II)
B. optic chiasm
C. long ciliary nerves
D. short ciliary nerves
E. nerves to eye muscles (III, IV, VI)

9. _____ A 35-year-old male is referred to a neurologist because of hearing loss. The patient also states that he has begun experiencing episodes of facial weakness and drooping at the corner of the mouth. An MRI (imaged above) shows a mass in the posterior cranial fossa at the cerebellopontine angle. Further testing demonstrated that the patient had a number of other neurological and physical deficits. Which of the following would NOT be likely to be shown by this patient?

A. decreased salivation
B. facial paralysis
C. loss of taste to the anterior 2/3 of the tongue
D. decreased secretion of the lacrimal gland
E. dilated pupil of the eye

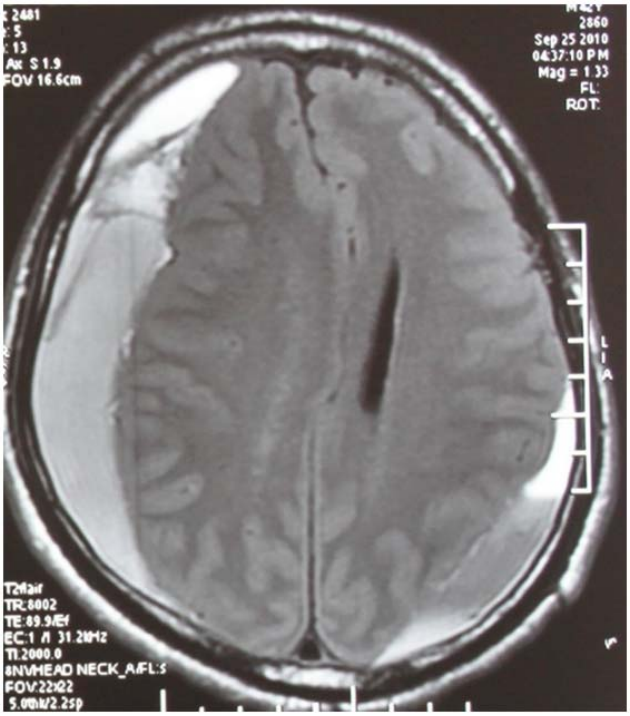

10. _____ A 63-year-old aging rock musician fell off the stage during a concert tour and his head struck a large speaker in front of the stage. While he felt fine but bruised on the day of the fall, within the next week he developed a bad headache and was more verbally incoherent than usual. X rays taken at the hospital showed no fractures of the skull but there was evidence of papilledema. The image above is an MRI image from a series that was subsequently ordered. Damage to which of the following vessels is most likely to account for the symptoms?

A. Internal Carotid Artery
B. Internal Jugular Vein
C. Vertebral Artery
D. Superficial Temporal Artery
E. 'Bridging' Vein or Venous Sinus

11. _____ A patient chronically suffers from excess production of mucous in the nasal cavity. He also complains that he often has tears in his eye. These symptoms could result from damage to the parasympathetic innervation of the mucous glands of the nose and the lacrimal gland. Damage to which of the following cranial nerves and associated ganglion could produce these symptoms?

A. CN VII, Pterygopalatine ganglion
B. CN IX, Otic ganglion
C. CN III, Ciliary ganglion
D. CN V, Semilunar ganglion
E. CN VII, Submandibular ganglion

12. _____ Access to the circulatory system may be obtained in neonates by a needle placed into the skull at the Anterior fontanelle. Which of the following is the vascular structure that would be accessed in this procedure?

A. Superior Sagittal sinus
B. Inferior Sagittal sinus
C. Sigmoid sinus
D. Middle Meningeal vein.
E. Cavernous sinus

13._____ A patient complains that he has difficulty chewing and that part of his face feels numb. When asked to open his mouth, the jaw is observed to deviate toward the right. Damage to which of the following nerves could produced the jaw deviation?

A. right Facial nerve
B. left Trigeminal nerve
C. right Trigeminal nerve
D. left Facial nerve
E. left Glossopharyngeal nerve

14. _____ A 64 year-old female is in the back seat of car that suddenly decelerates in an accident. She shows no acute injury but in the following days she begins having double vision. Examination of the patient shows that she is holding her head tilted (see photo above). Cranial nerve examination finds that she has difficulty moving her right eye downward, particularly from an adducted position. A head MRI is ordered to specifically image which the following cranial nerves?

A. right cranial nerve III
B. left cranial nerve IV
C. right cranial nerve IV
D. left cranial nerve III
E. right cranial nerve VI

15. _____ A patient has difficulty in swallowing. Neurological tests show that the Vagus and Glossopharyngeal nerves are normal. Which other nerve that should be tested, as it also innervates a muscle of the soft palate and could produce the difficulty in swallowing?

A. Transverse cervical nerve
B. V (Trigeminal)
C. XI (Accessory)
D. VII (Facial)
E. XII (Hypoglossal)

16.____ A 19 year old suffers a violent blow to the nose during a fist fight. Over the following week. the person notices that a clear fluid persists in dripping from the nose. and goes to the local hospital emergency room. The physician orders a CT scan (image above) and finds a defect (arrow) in the floor of anterior cranial fossa. This defect is likely a fracture of which of the following bones?

A. Maxillary bone
B. Vomer
C. Horizontal process of the frontal bone
D. Greater wing of the sphenoid bone
E. Cribriform plate of the ethmoid bone

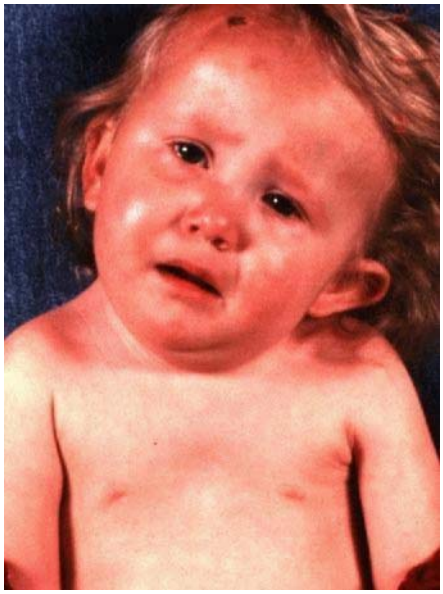

17. _____ The parents of a small child notice that she appears to have a 'twisted' neck. When the child is brought to the pediatrician's office, the head is held so that the face is directed partially toward one shoulder (she photo above). The physician suspects that the child has a torticollis resulting from the contracture of a neck muscle. Contracture of which of the following muscles could cause this condition?

A. Left Sternocleidomastoid muscle
B. Right Sternocleidomastoid muscle
C. Left Omohyoid muscle
D. Left Sternothyroid muscle
E. Left Digastric muscle

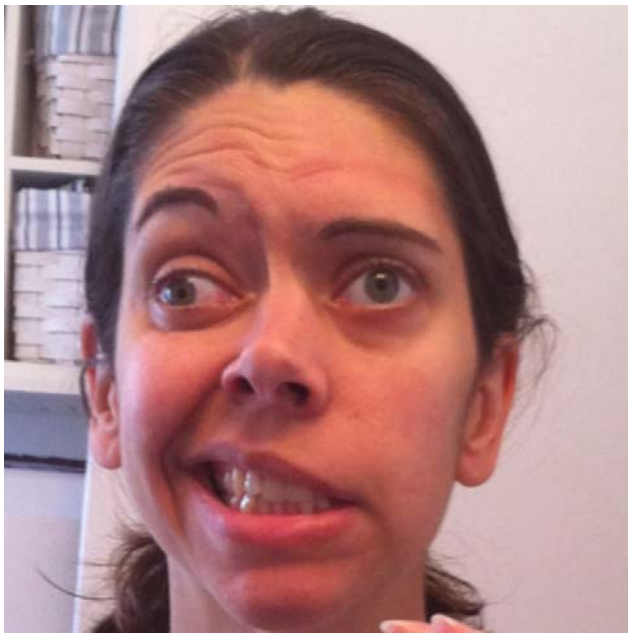

18. This is a photo a person posted on the web in which they are attempting to smile and raise their eyebrows. Which of the following would be an additional symptom shown by this person?

A. Pain (ear ache) in person's right ear
B. Sounds seem too loud in person's left ear
C. Decreased taste sensation on right side
D. Pupillary constriction in left eye
E. Loss of sensation to skin of forehead on left side

19. An 18-year-old female sees a physician because one of her eyes 'won't stay open' (photo above). Tests show that the patient's visual acuity and eye movements are normal. However, further tests show that pupil of the left eye is constricted (relative to right eye). These symptoms could be caused by a tumor at which of the following locations?

A. at the Superior Orbital Fissure compressing the Oculomotor nerve.
B. at the Internal Auditory meatus compressing the Facial nerve
C. in the neck compressing the Sympathetic chain.
D. at the Supraorbital foramen compressing the Supraorbital nerve.
E. at the Inferior Orbital fissure compressing Infraorbital nerve.

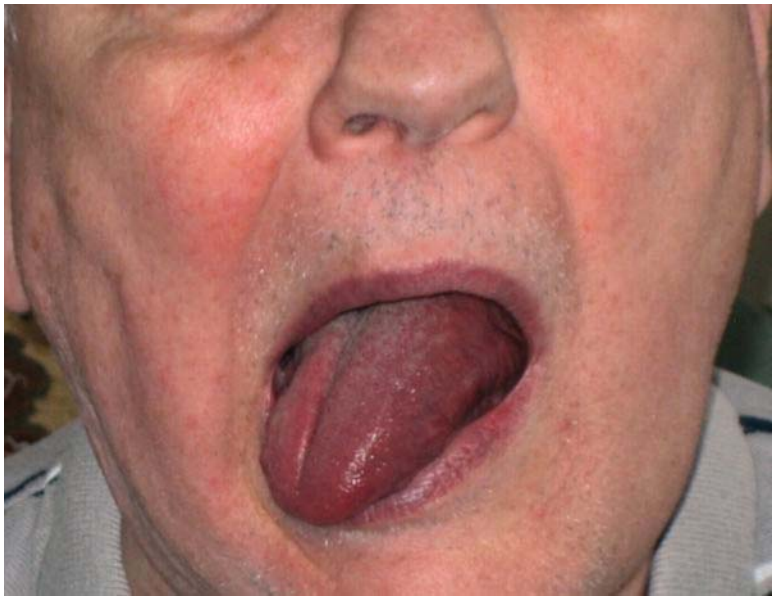

20. A patient complains that he is having difficulty speaking and that he is biting his tongue when chewing his food. The physician asks the patient to protrude his tongue (photo above). Other tests show that there is no loss of taste or touch sensation in the tongue. Damage to which of the following nerves could produce these symptoms?

A. Right Lingual nerve
B. Right Hypoglossal nerve
C. Left Lingual nerve
D. Left Hypoglossal nerve
E. Left Glossopharyngeal nerve

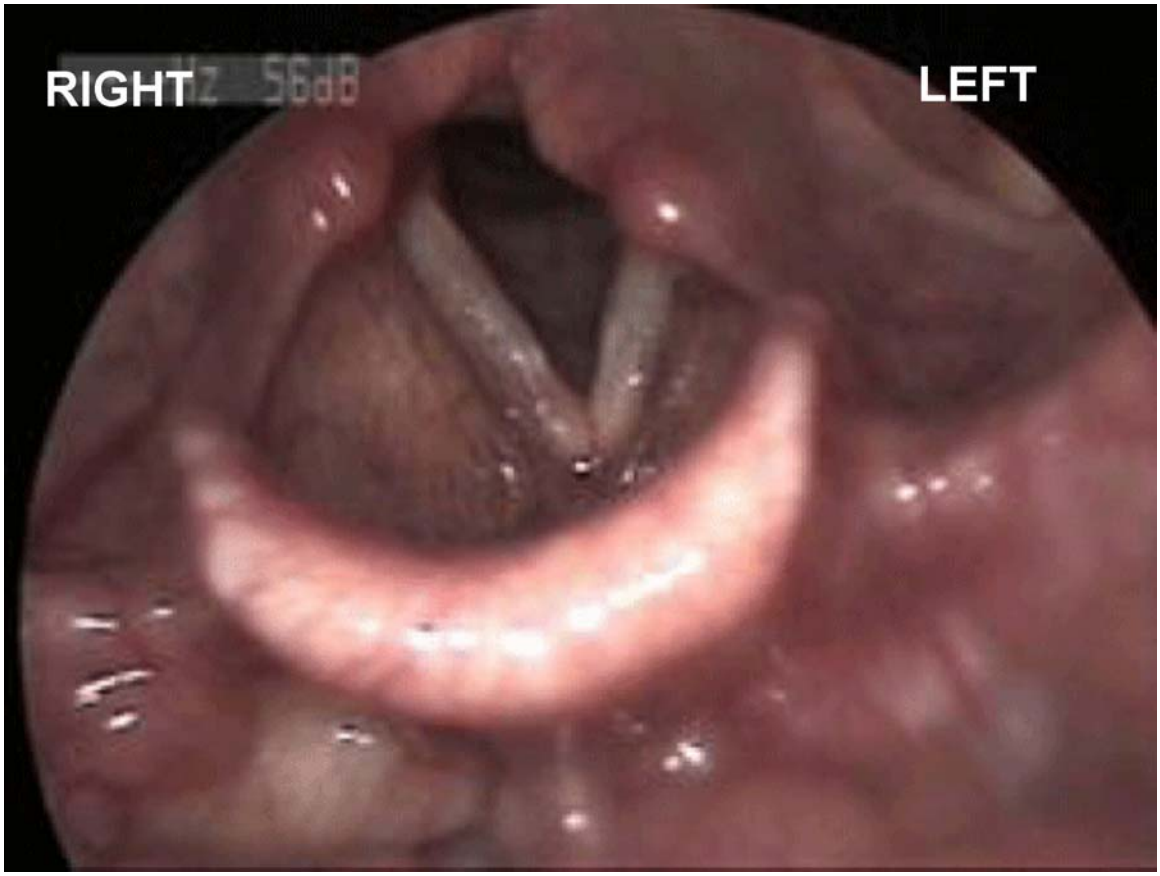

21. A patient undergoes surgery for removal of thyroid nodules. The nodules are found to be noncancerous but post-operatively the patient has a 'hoarse' voice. Laryngoscopic examination (photo above) shows asymmetry in position of the vocal folds when the patient is told to breathe deeply. The physician suspects that this is due to damage of which of the following structures?

A. Right Superior Laryngeal nerve
B. Right Recurrent Laryngeal nerve
C. Left Superior Laryngeal nerve
D. Left Recurrent Laryngeal nerve
E. Right Sympathetic chain

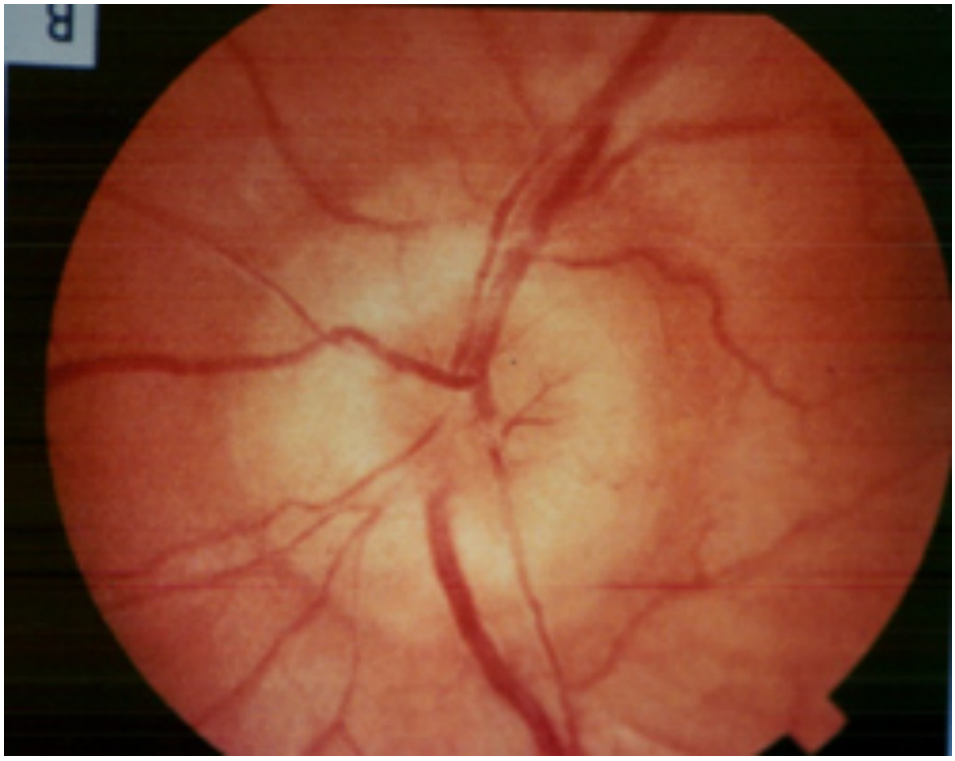

22. 49. An 85 year old woman complains of persistent headaches. Examination of the optic nerve with an ophthalmoscope (image above) shows bulging consistent with the occurrence of papilledema. The appearance is similar in both eyes. The physician suspects that this may be cause by increased intracranial pressure. Calcification of which of the following structures could cause this condition?

A. choroid plexus
B. pterygoid venous plexus
C. denticulate ligaments
D. emissary veins
E. arachnoid villi

HEAD AND NECK SAMPLE QUESTIONS KEY

1. B
2. D
3. D
4. C
5. B
6. A
7. C
8. E
9. E
10. E
11. A
12. A
13. C
14. C
15. B
16. E
17. A
18. B
19. C
20. B
21. B
22. E

REVIEW OF HEAD AND NECK: CRANIAL NERVES, ETC.

OUTLINE: USE SKULL AND CRANIAL NERVES AS BASIS FOR REVIEW

1. INTRODUCTION: SKULL, DURA, VENOUS SINUSES

2. CRANIAL NERVES AND AREAS SUPPLIED

BONES OF SKULL: OVERVIEW

ADULT - BONES RIGIDLY LINKED BY SUTURES

BIRTH - BONES LINKED BY FLEXIBLE CT, FONTANELLES

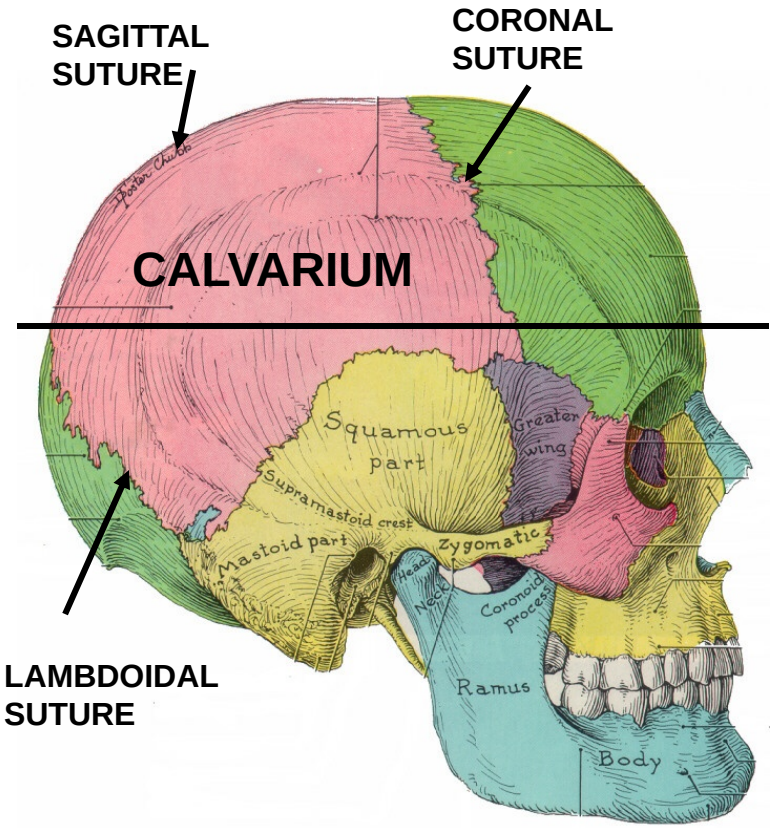

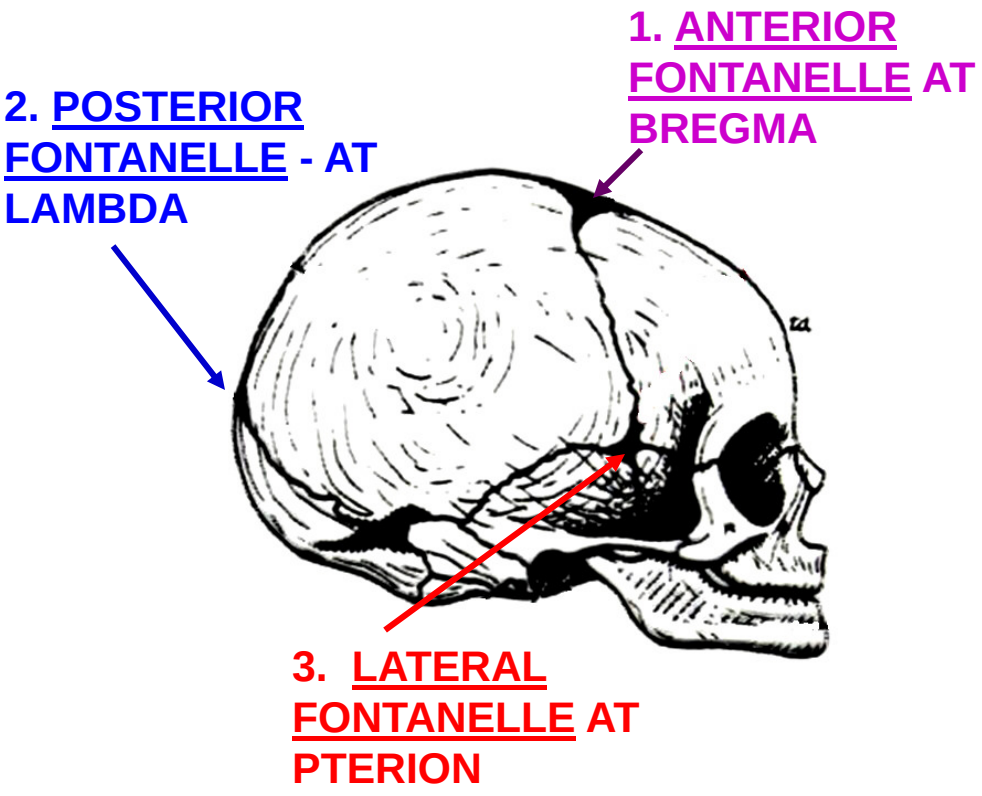

VENOUS SINUSES CAN BE ACCESSED IN NEONATES THROUGH FONTANELLES; SUPERIOR SAGITTAL VENOUS SINUS VIA ANTERIOR FONTANELLE

MENINGES OF BRAIN: OVERVIEW

3 layers, like spinal cord:
Dura Mater – tough mother;
Arachnoid = spiderlike;
Pia Mater = tender mother;
- arrangement different: NO EPIDURAL SPACE

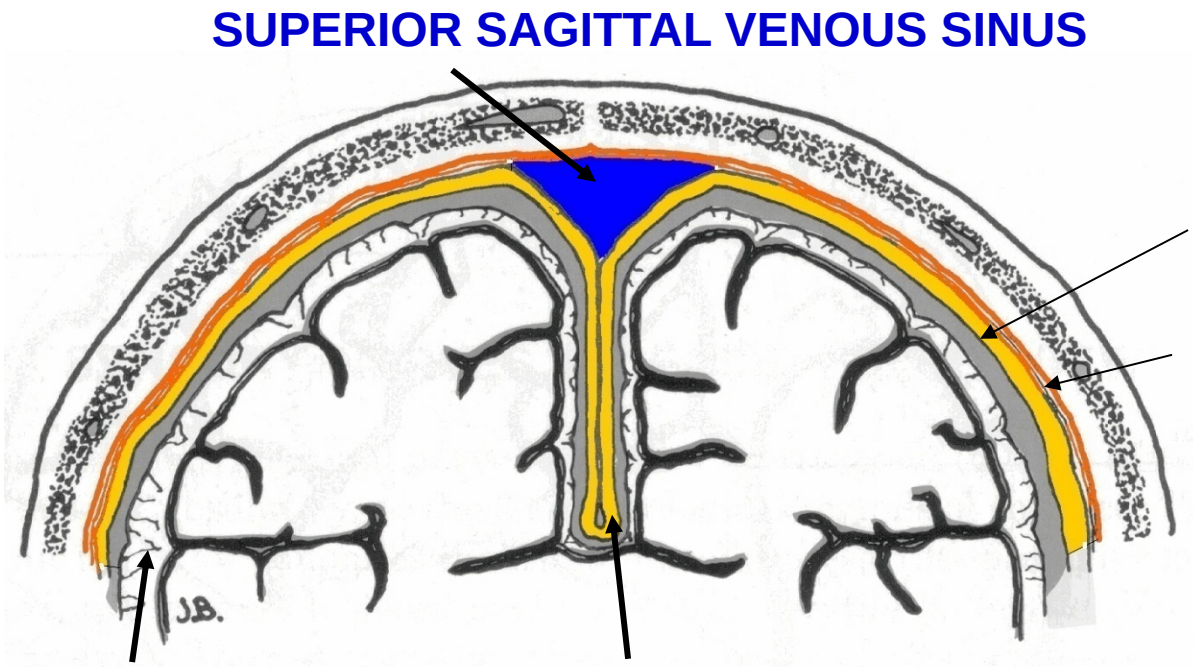

DURA MATER - tough connective tissue layer, composed of two layers -

1) INNER MEMBRANE LAYER (true dura)

2) OUTER ENDOSTEAL LAYER - periosteum on inner side of calvarium

Two layers - fused in most places - separate to form DURAL REFLECTIONS

VENOUS SINUSES OF BRAIN: OVERVIEW

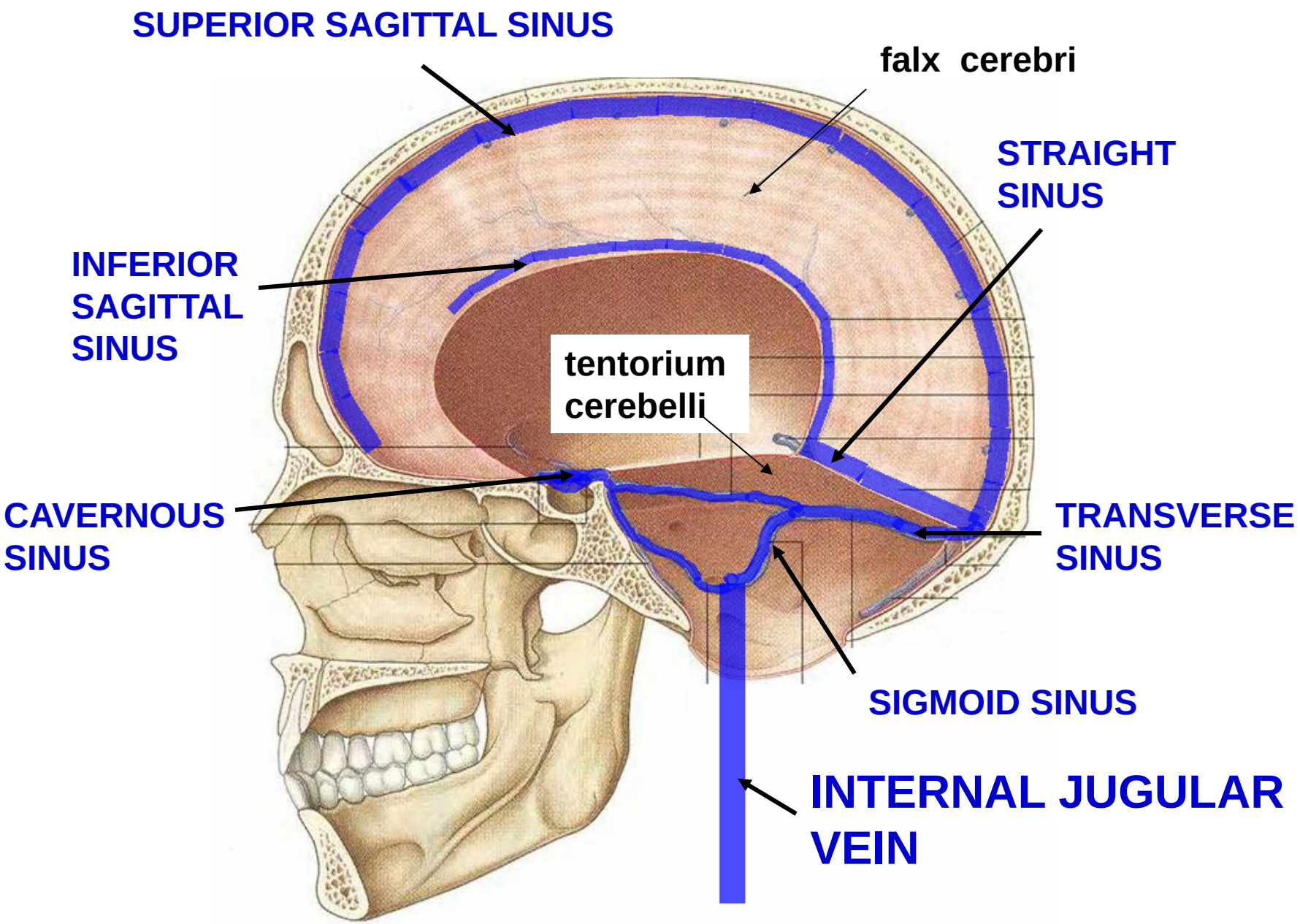

INTERIOR OF SKULL - Calvarium removed

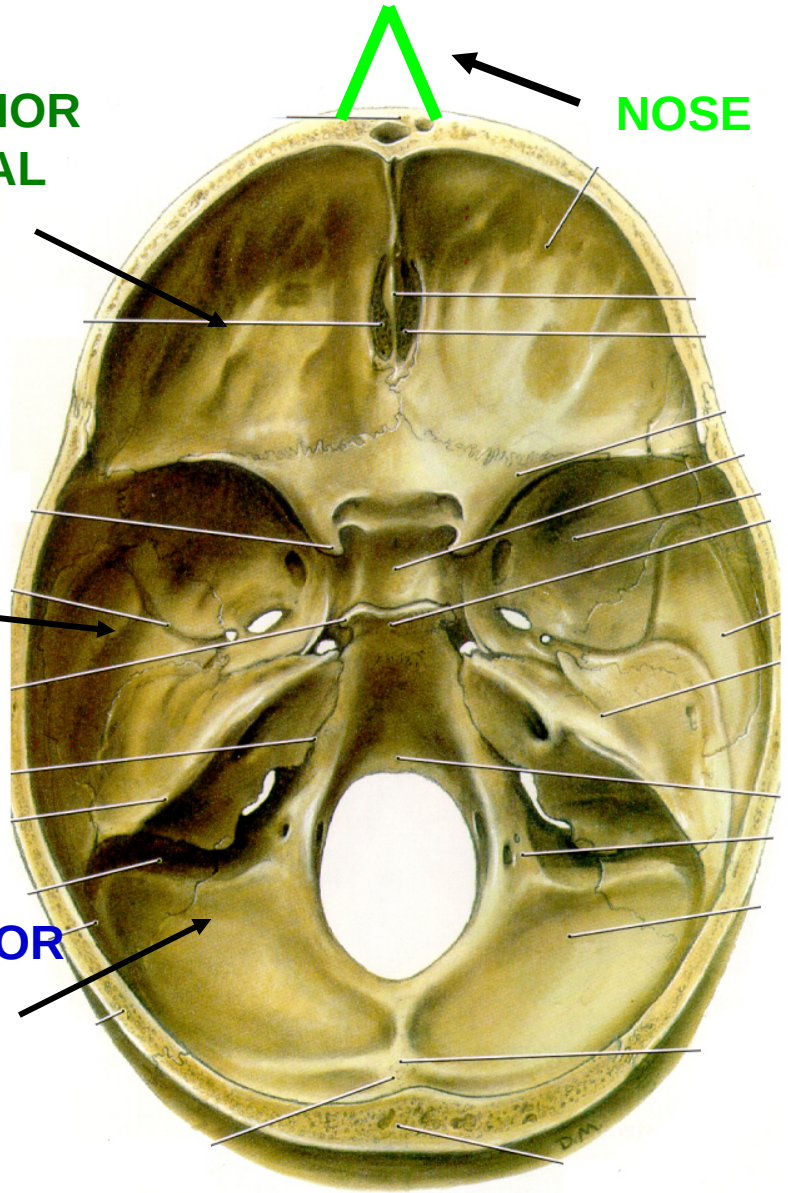

CRANIAL NERVES

I. Olfactory
II. Optic
III. Oculomotor
IV. Trochlear
V. Trigeminal
VI. Abducens
VII. Facial
VIII. Vestibulo-cochlear
IX. Glossopharyngeal
X. Vagus
XI. Accessory
XII. Hypoglossal

ANTERIOR CRANIAL FOSSA -

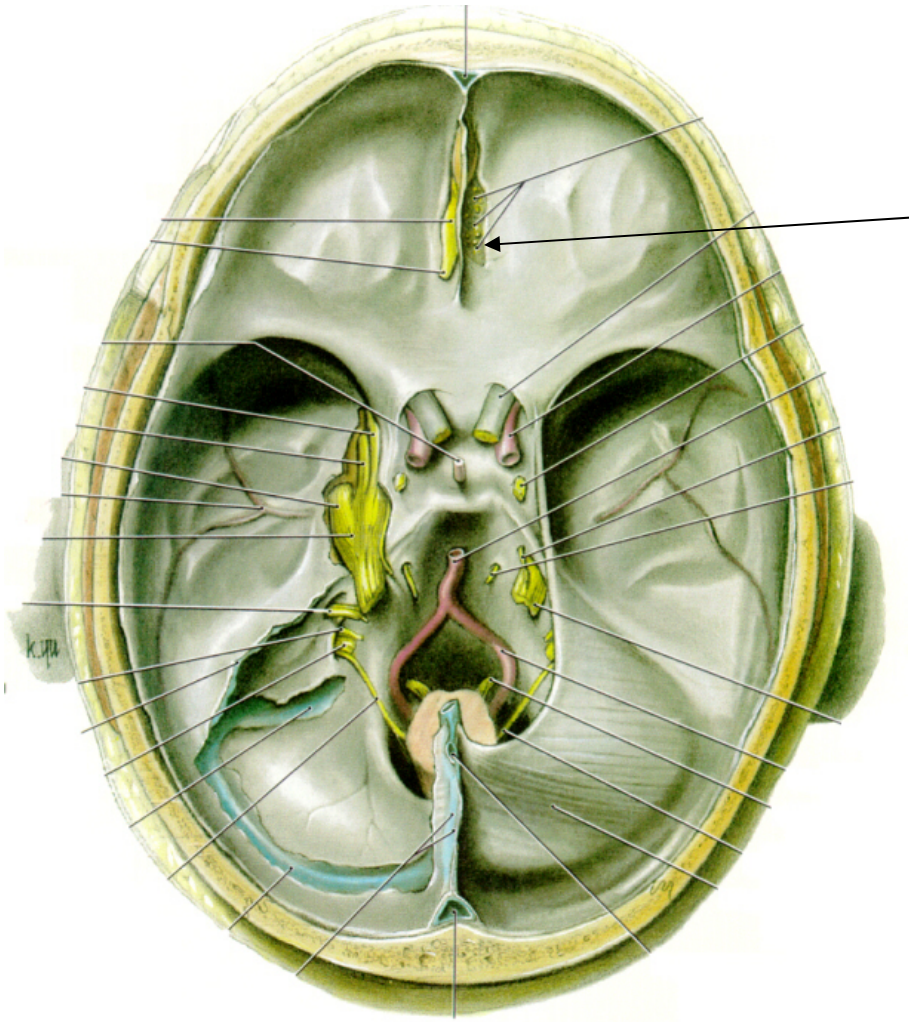

I. Olfactory Nerve/ Nasal Cavity -

1) Fracture of Cribriform plate of ethmoid bone

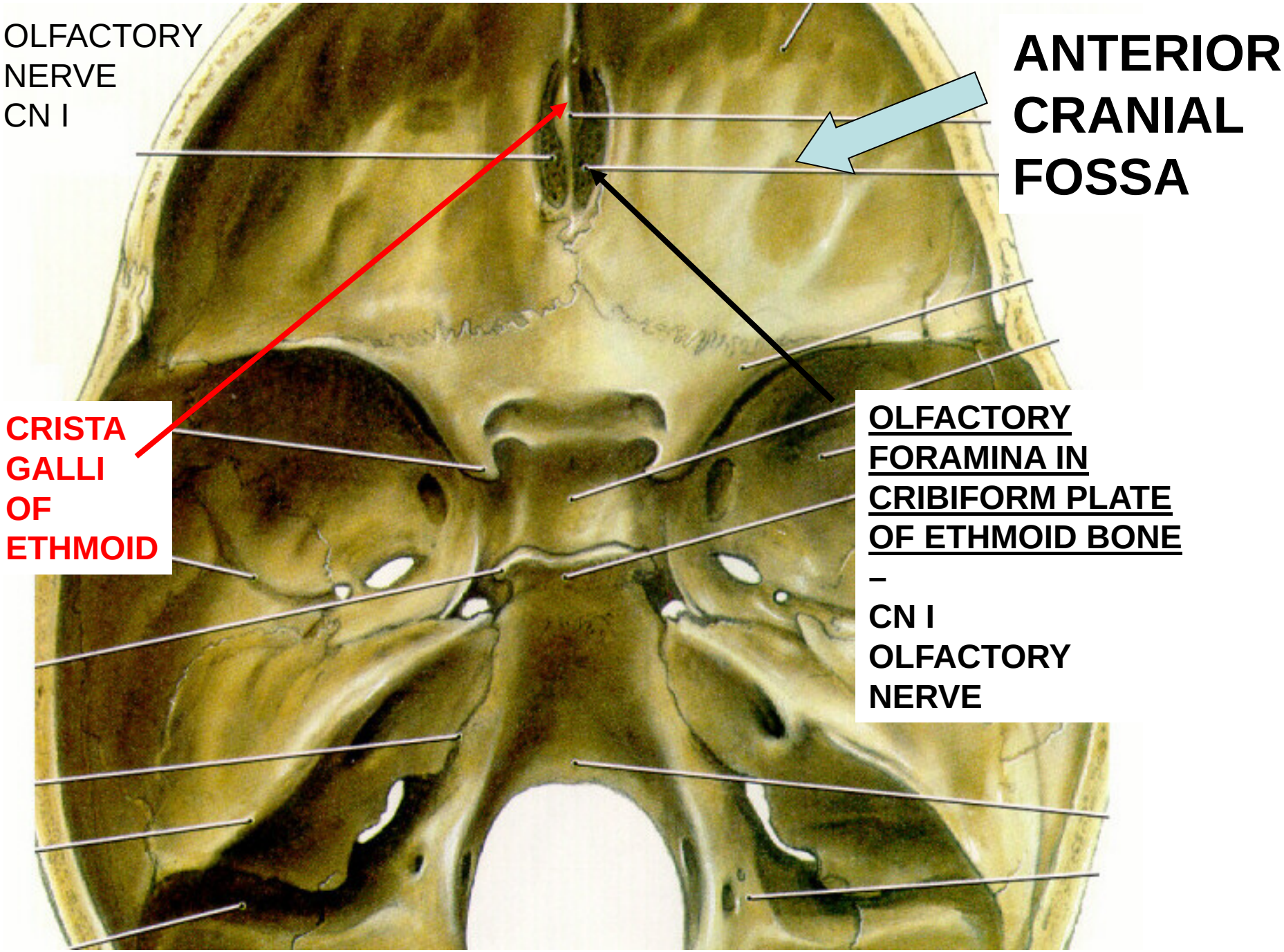
OLFACTORY NERVE CN I
ANTERIOR CRANIAL FOSSA
CRISTA GALLI OF ETHMOID
OLFACTORY FORAMINA IN CRIBIFORM PLATE OF ETHMOID BONE – CN I OLFACTORY NERVE

I - OLFACTORY NERVE

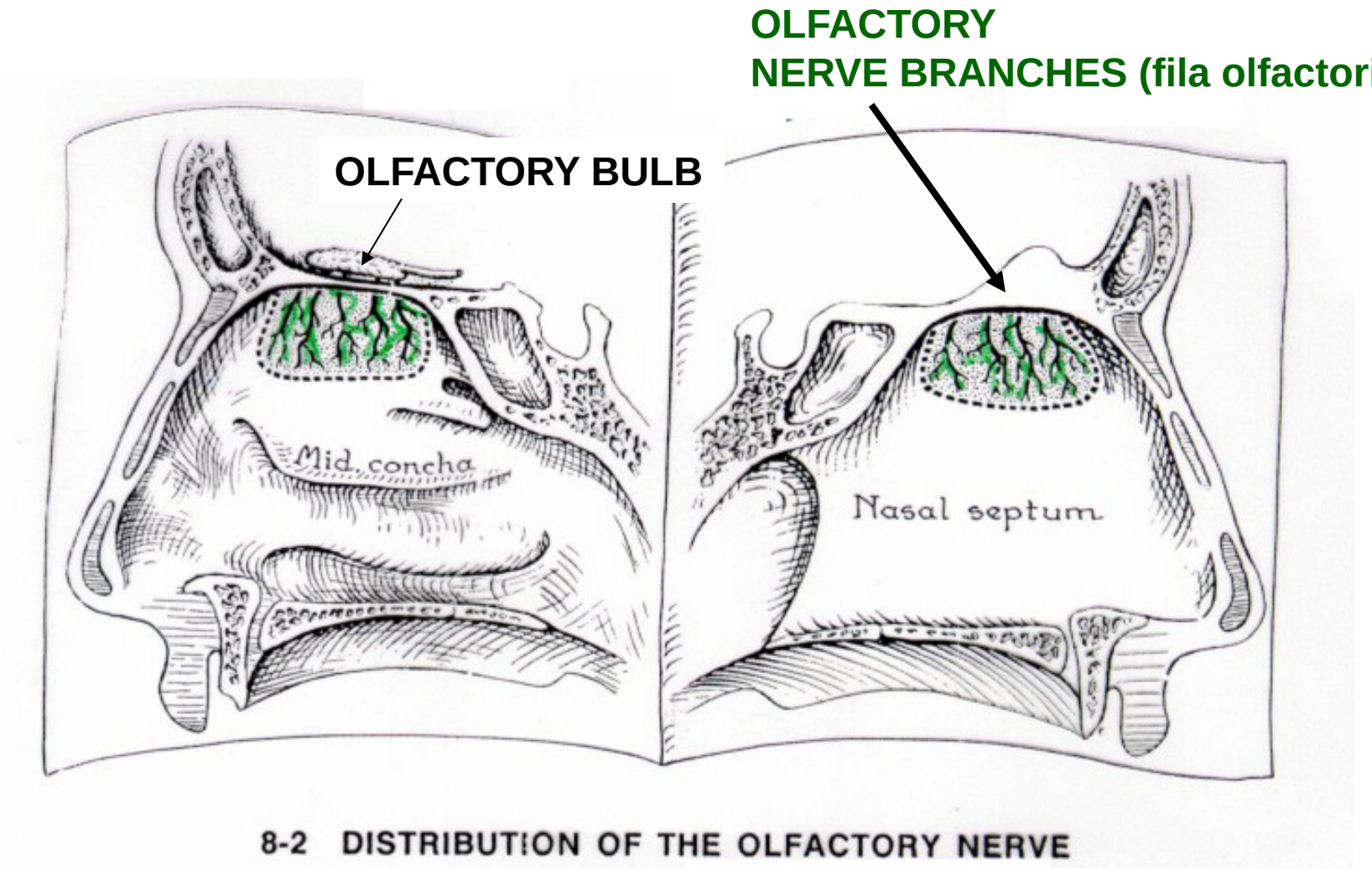

DAMAGE - loss of sense of smell

CT CORONAL PLANE OF HEAD

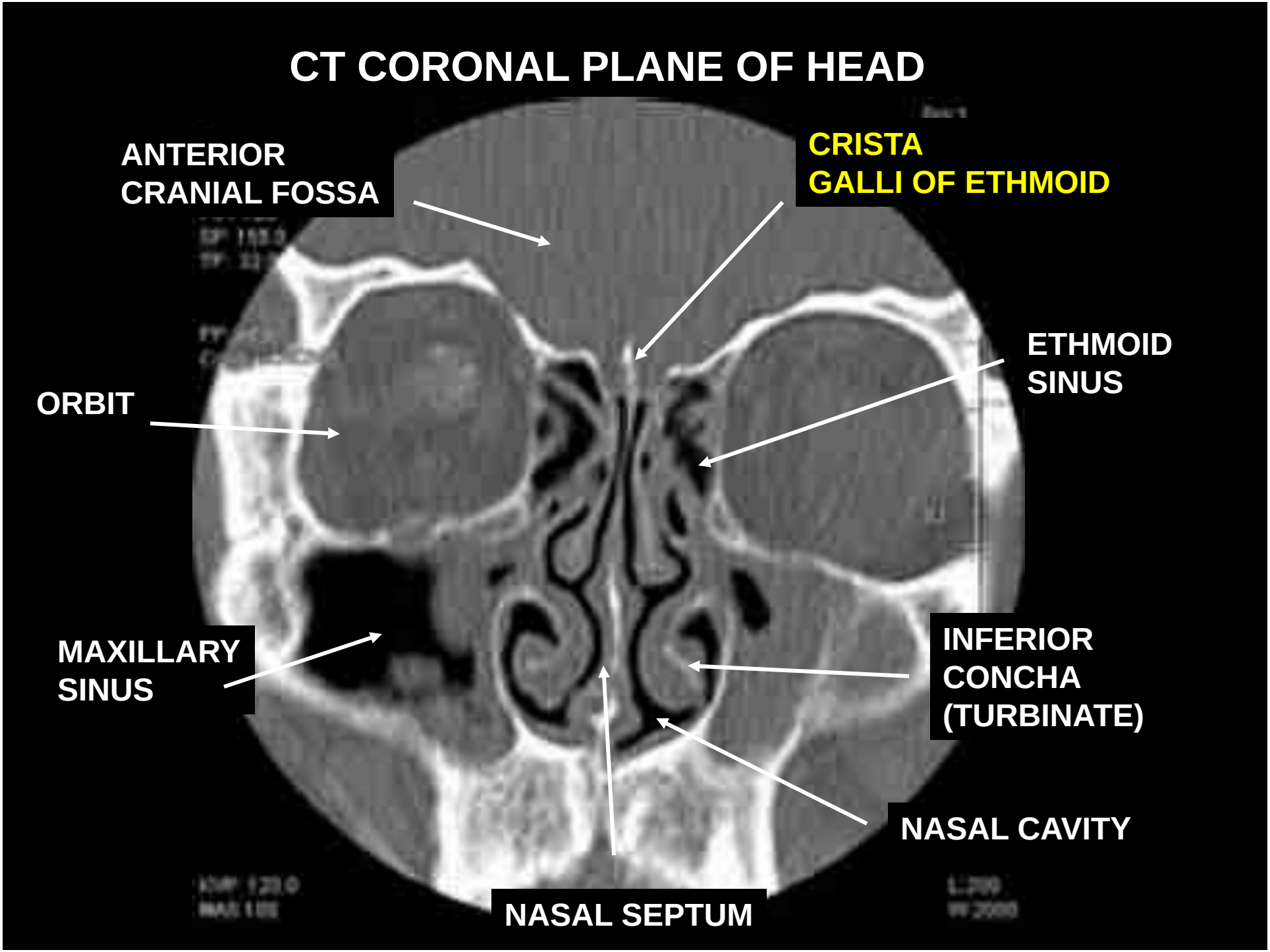

CLINICAL QUESTION: BLOW TO NOSE PRODUCES LEAKAGE OF FLUID FROM NOSE; FRACTURE CRIBRIFORM PLATE OF ETHMOID

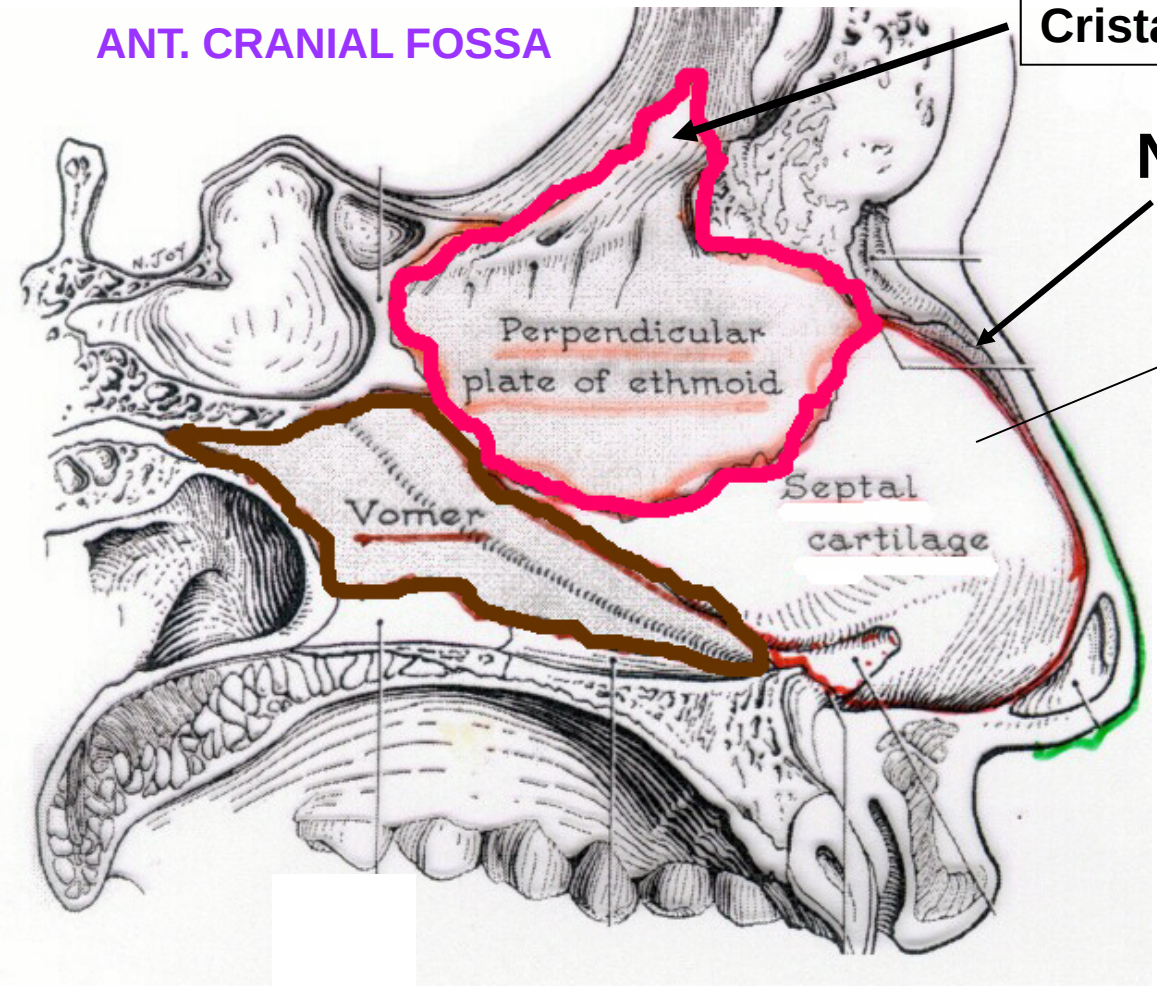

FRACTURE OF NOSE - can break cribriform plate of ethmoid bone, floor of Ant. Cranial fossa - leak CSF from nose; spread of infection

OVERVIEW: NERVES of NASAL CAVITY

Nerves

1.Olfactory N. - smell; Olfactory Area

2.General Sensation - touch, pain, etc.

- V1 Anterior Ethmoidal N.

- V2 Nasal Branches

- V2 Nasopalatine N.

3. Mucous Glands of nose - Parasympathetics - VII - Facial N. by Pterygopalatine Ganglion (hitchhike with branches of V)

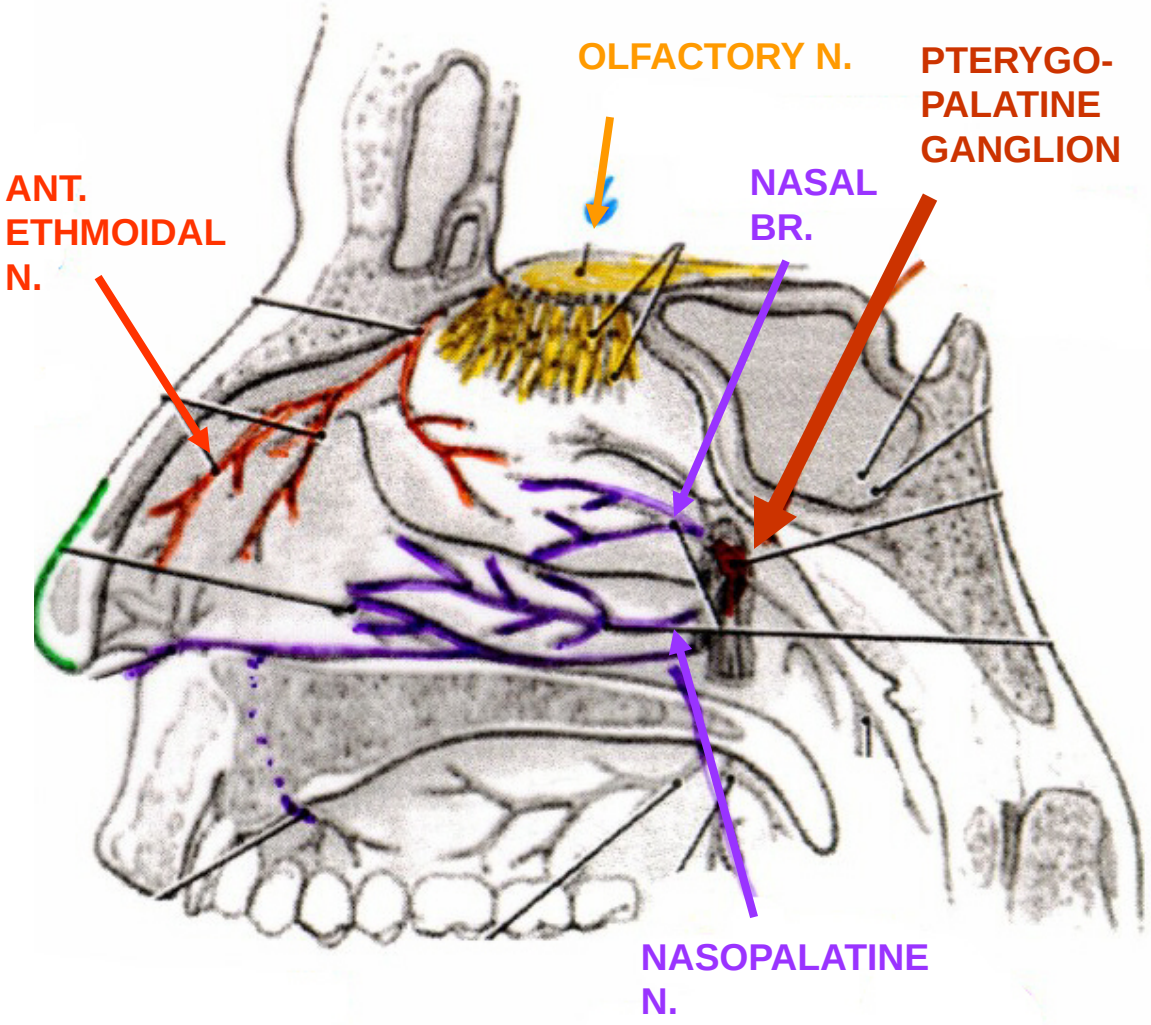

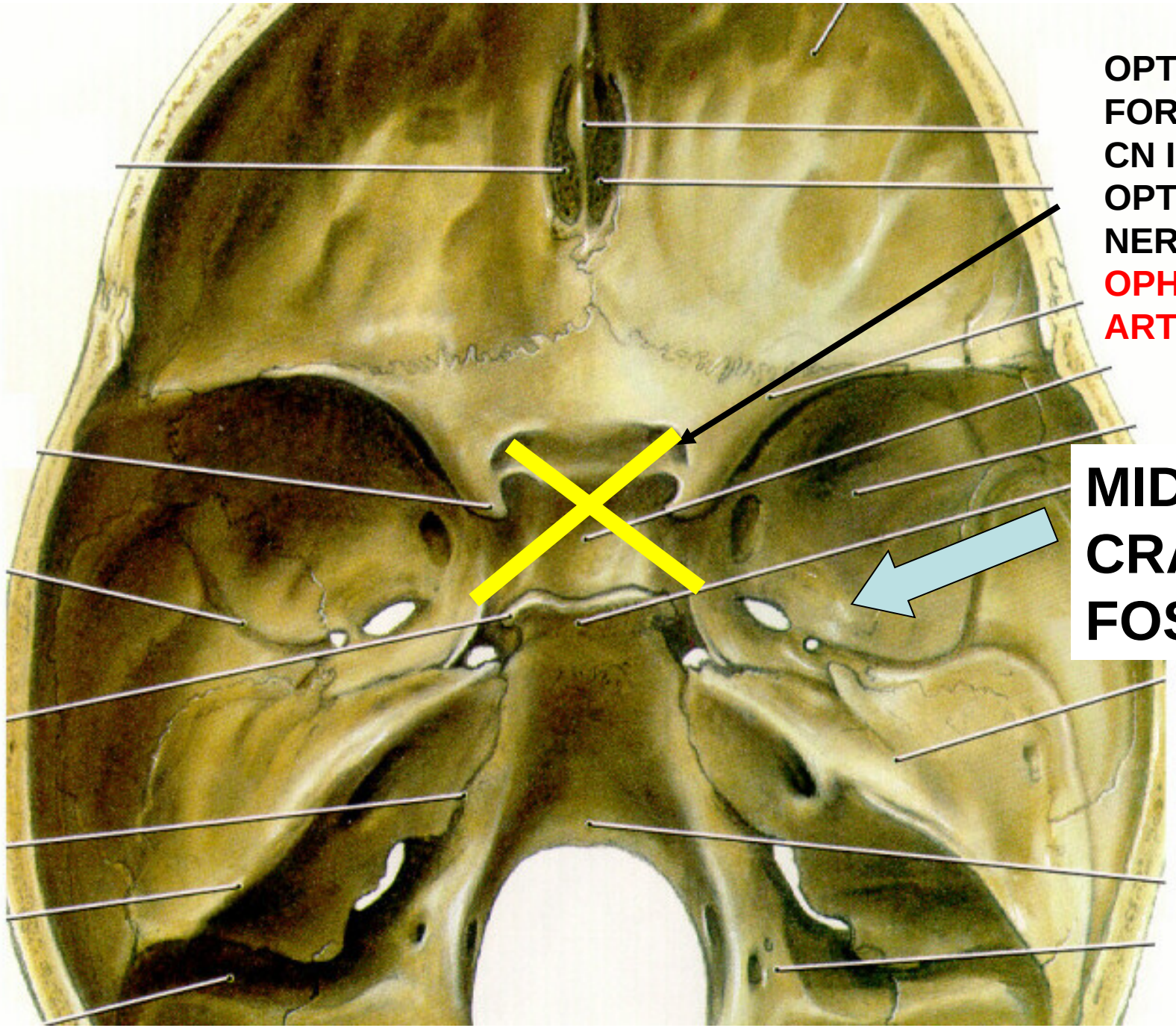
OPTIC FORAMEN
CN II
OPTIC NERVE,
OPHTHALMIC ARTERY
MIDDLE CRANIAL FOSSA

II - OPTIC NERVE

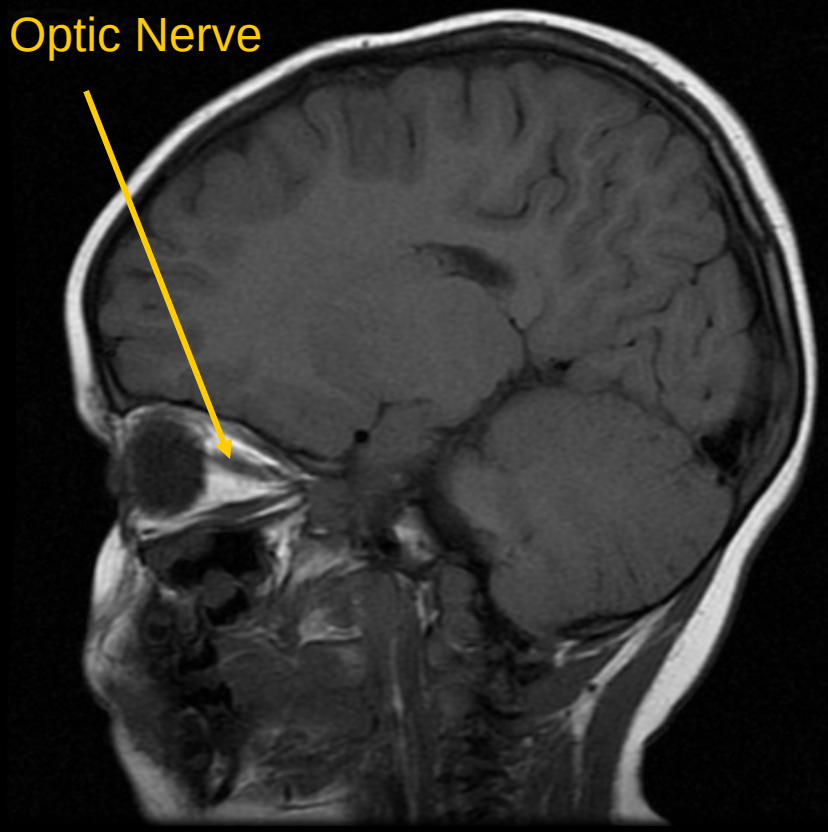

OPHTHALMIC ARTERY ENTERS ORBIT WITH OPTIC NERVE

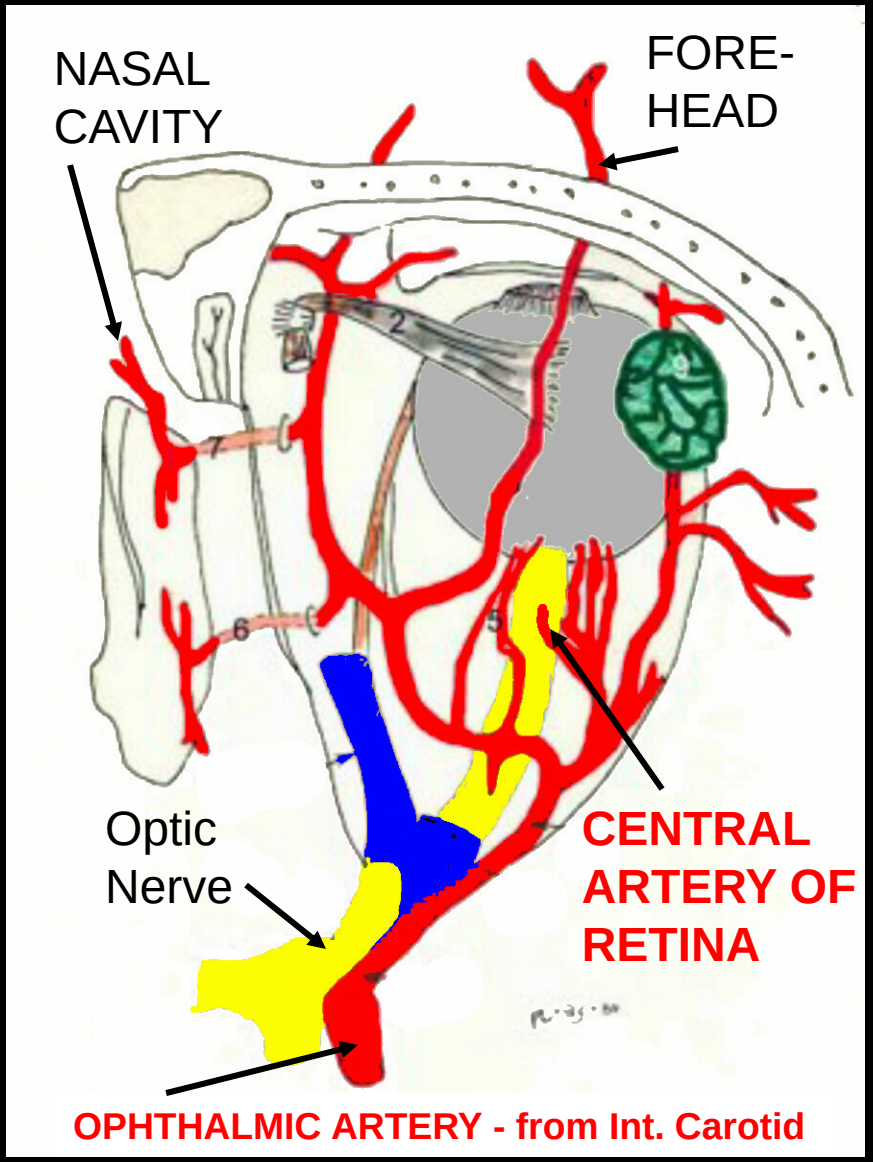

CLINICAL QUESTION: SUDDEN ONSET OF BLINDNESS IN ONE EYE

OPHTHALMOSCOPE VIEW →

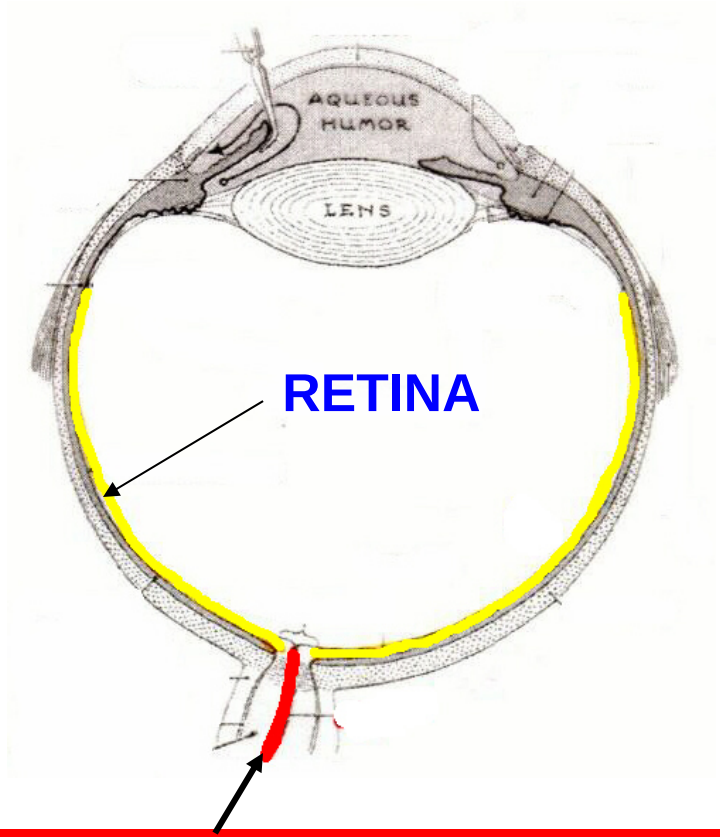

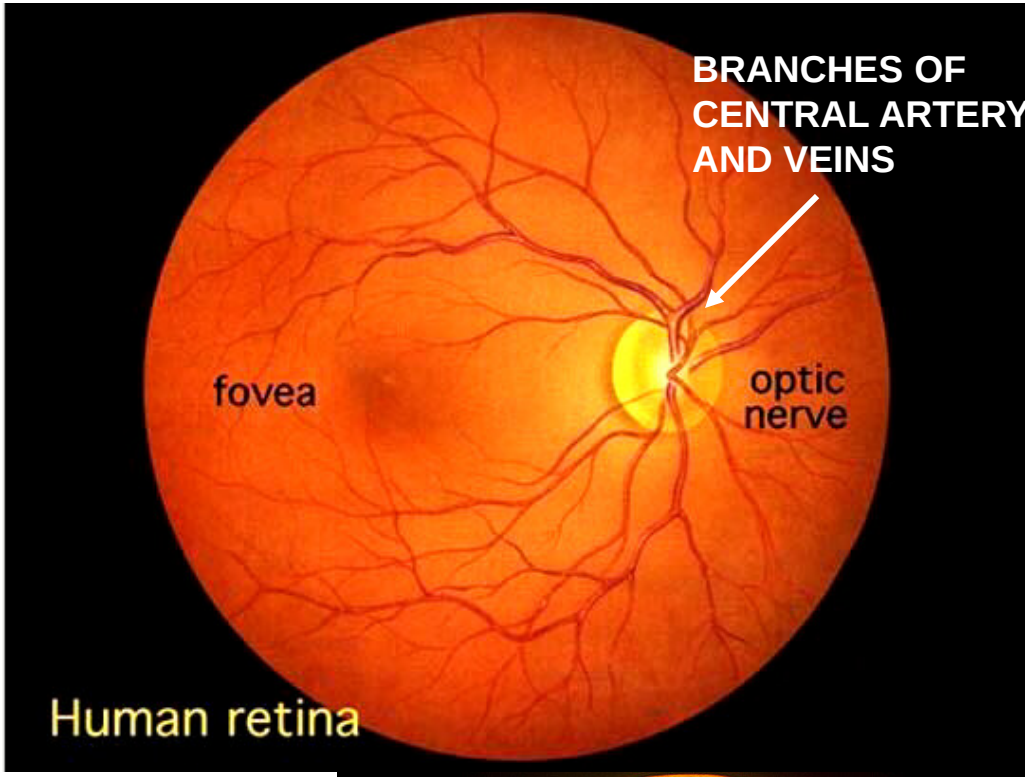

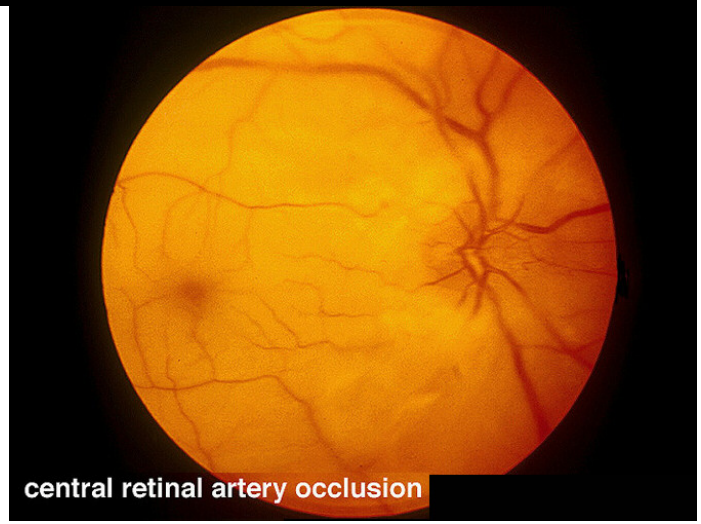

CENTRAL ARTERY OF RETINA - BRANCH OF OPTHALMIC ART. NO ANASTOMOSES; OCCLUSION RESULTS IN BLINDNESS

OPTIC NERVE FUNCTION COMPROMISED BY INCREASED CSF PRESSURE

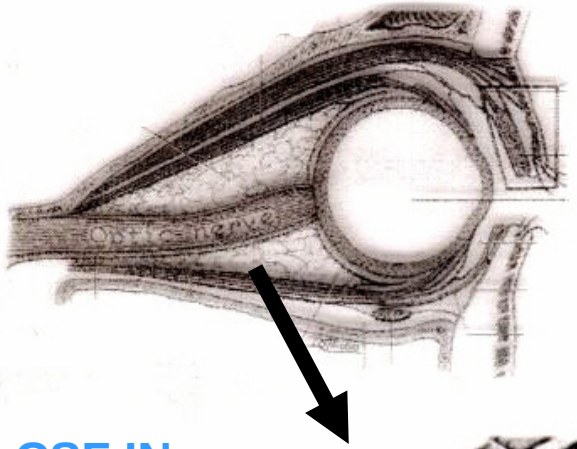

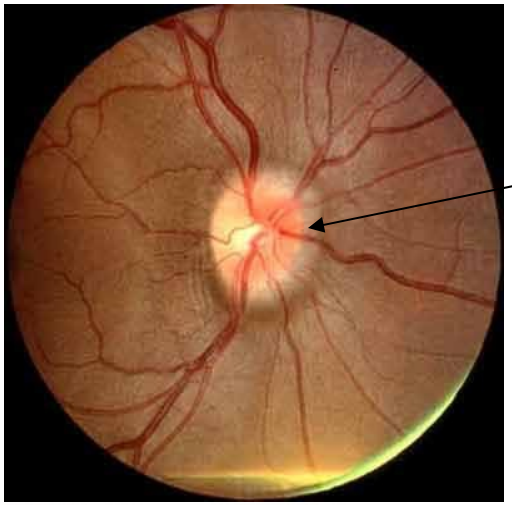

PAPILLEDEMA - engorgement of retinal veins (correspond to branches of central artery)

CSF IN SUBARACH SPACE

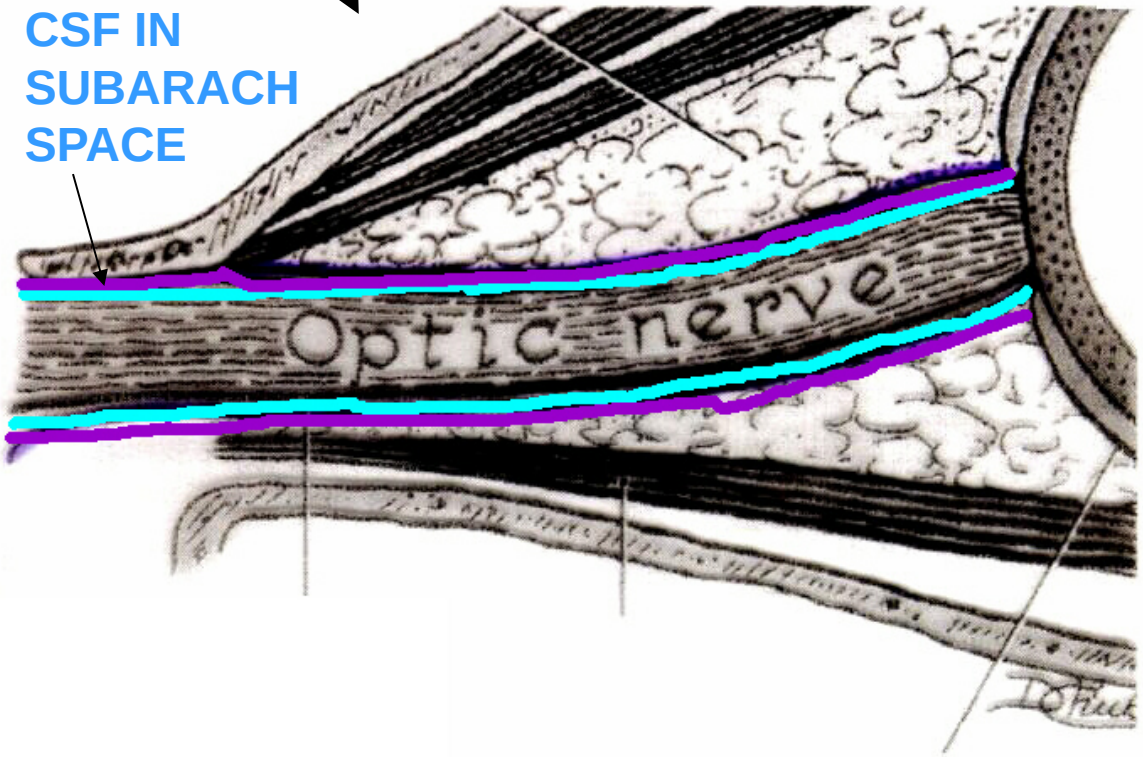

DURA & SUBARACHNOID SPACE (CSF) EXTEND AROUND OPTIC NERVE;

COMMUNICATING HYDROCEPHALUS - INCREASE IN CSF PRESSURE CAN PRODUCE VISUAL DEFICITS; slow onset; headaches

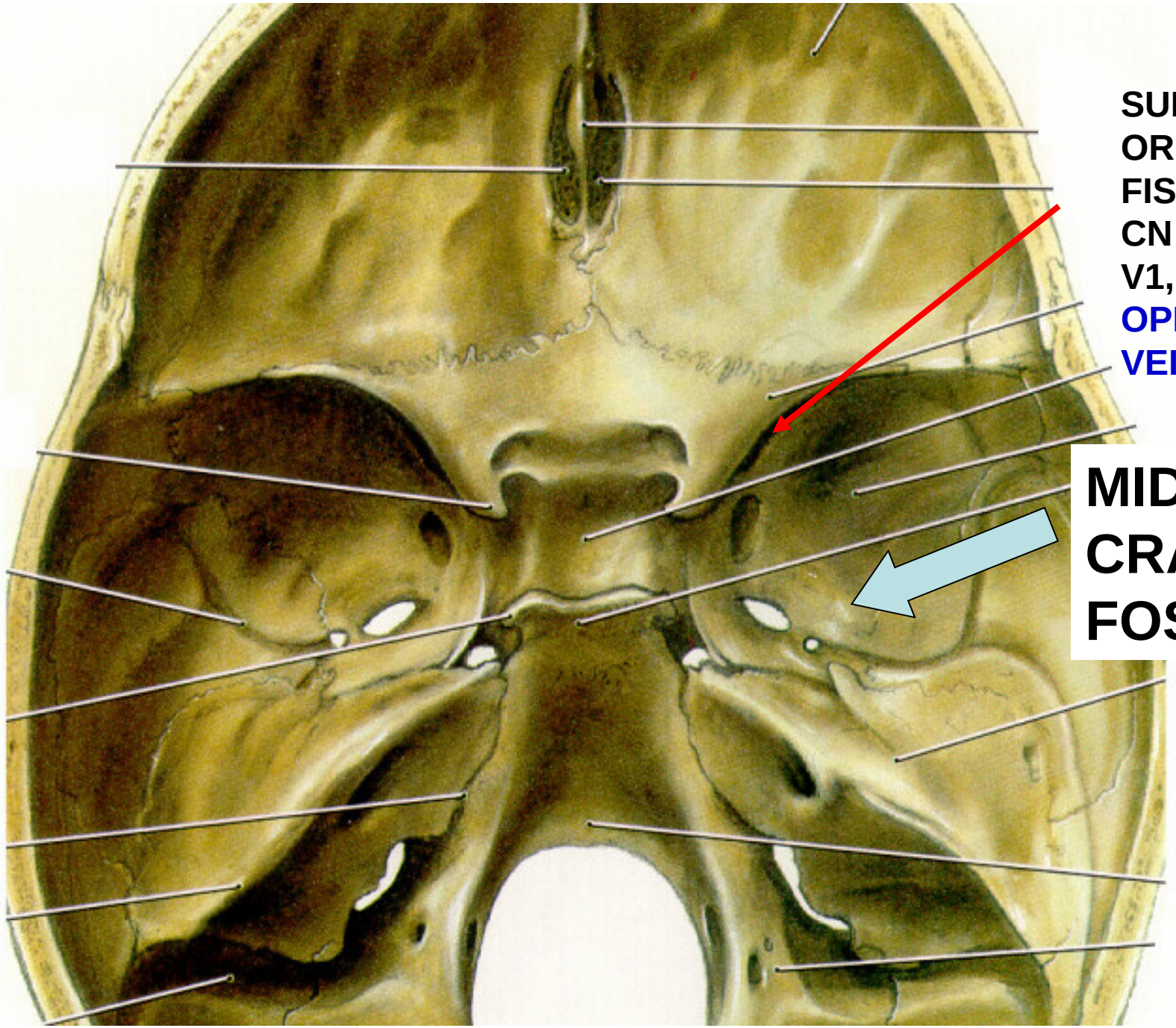
SUPERIOR ORBITAL FISSURE – CN III, IV V1, VI, OPHTHALMIC VEINS
MIDDLE CRANIAL FOSSA

EYE MOVEMENTS DIAGRAM

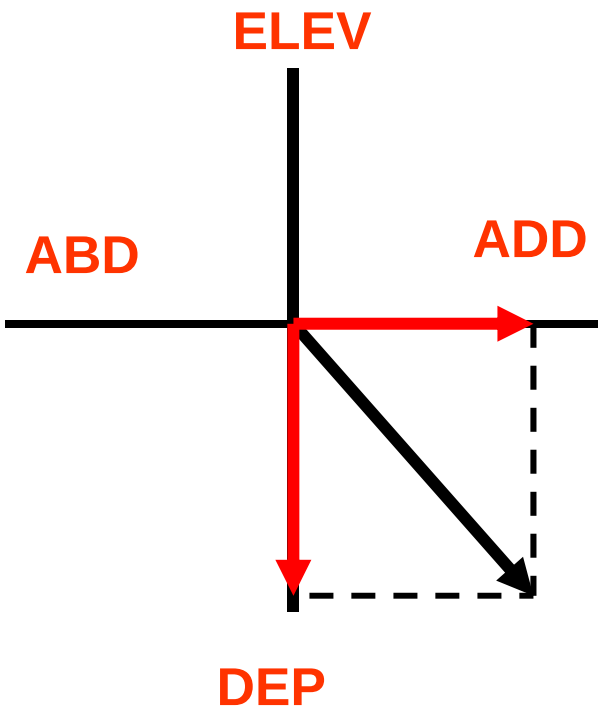

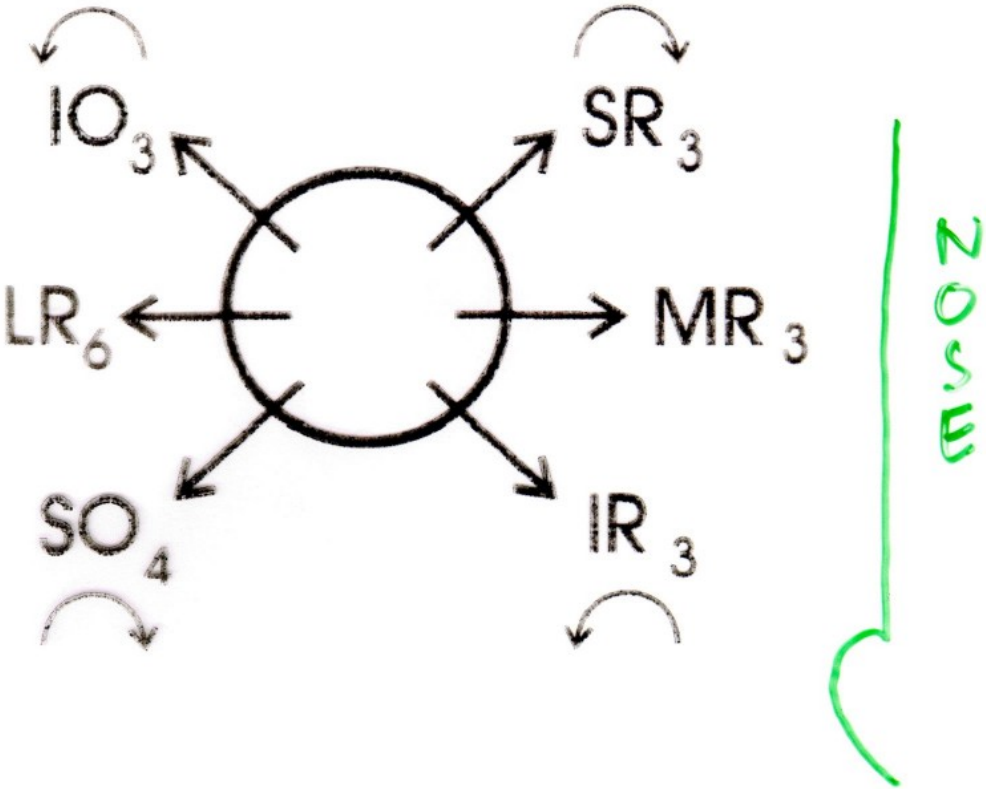

RESTING POSITION OF EYE: DETEMINED BY BALANCE OF ACTION OF OPPOSING MUSCLES

ABDUCENS NERVE DAMAGE

PATIENT WITH ABDUCENS (VI) NERVE DAMAGE

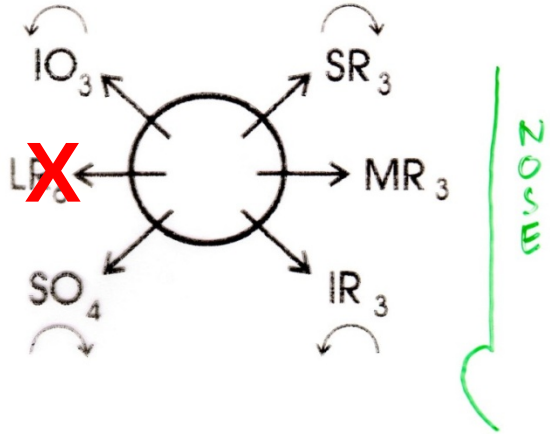

SYMPTOM: DIPLOPIA

ABDUCENS (VI): AT REST MEDIAL STRABISMUS (CROSS-EYED) DUE TO DAMAGE/PARALYZE LATERAL RECTUS

TROCHLEAR (IV) NERVE PALSY: INABILITY TO TURN EYE DOWN AND OUT; ALSO HEAD TILT TO OPPOSITE SIDE

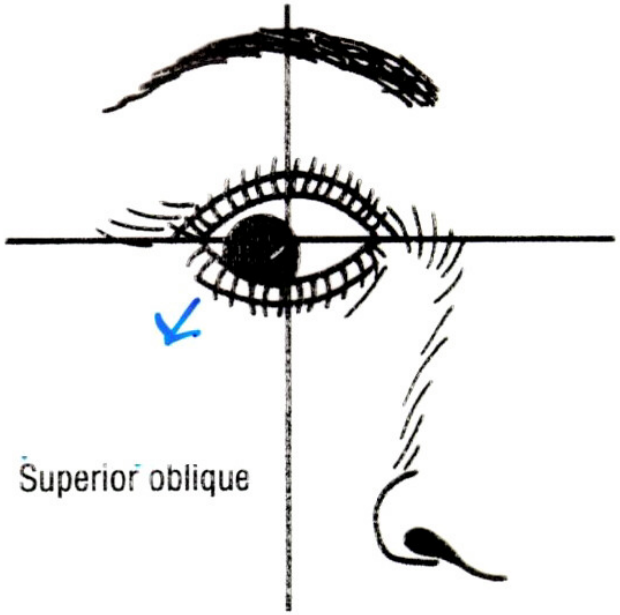

PATIENT CANNOT LOOK DOWN AND OUT

Symptoms - Difficulty walking down stairs; HEAD TILTED

NORMAL

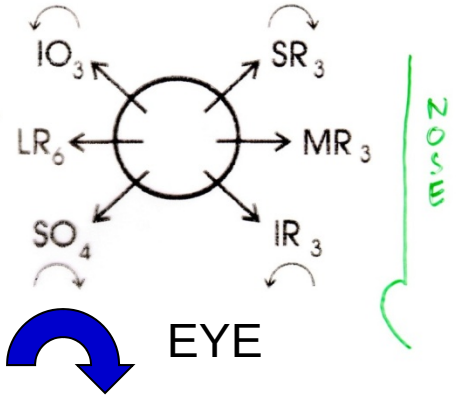

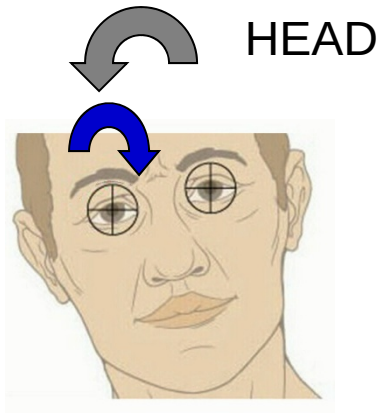

Rotation - occurs when tilt head; rotate eye medially when tilt head laterally

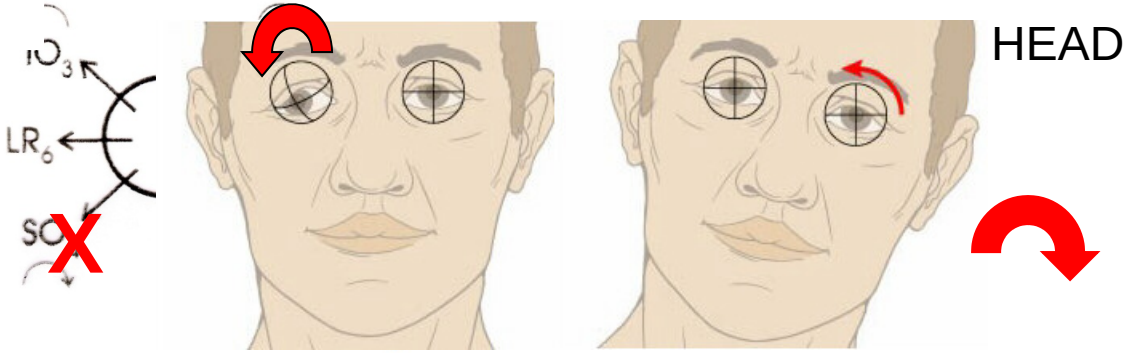

AFTER IV DAMAGE - eye rotated laterally; PATIENT TILTS HEAD TO OPPOSITE SIDE so both eyes similarly rotated

OCULOMOTOR (III) NERVE DAMAGE

Oculomotor Nerve supplies -

- Superior, Inferior, Medial Rectus
- Inferior Oblique
- Levator palpebra - lift eyelid
- Parasymp: pupil constrictor, ciliary muscle

DAMAGE: AT REST

- LATERAL STRABISMUS (WALL-EYED) DUE TO PARALYZE MEDIAL RECTUS

ALSO

- PTOSIS - DROOPING EYELID- PARALYZE LEV. PALPEBRAE SUPERIORIS
- DILATED PUPIL - PARALYZE PUPILLARY CONSTRICTOR

ANATOMY: LEVATOR PALPEBRAE SUPERIORIS

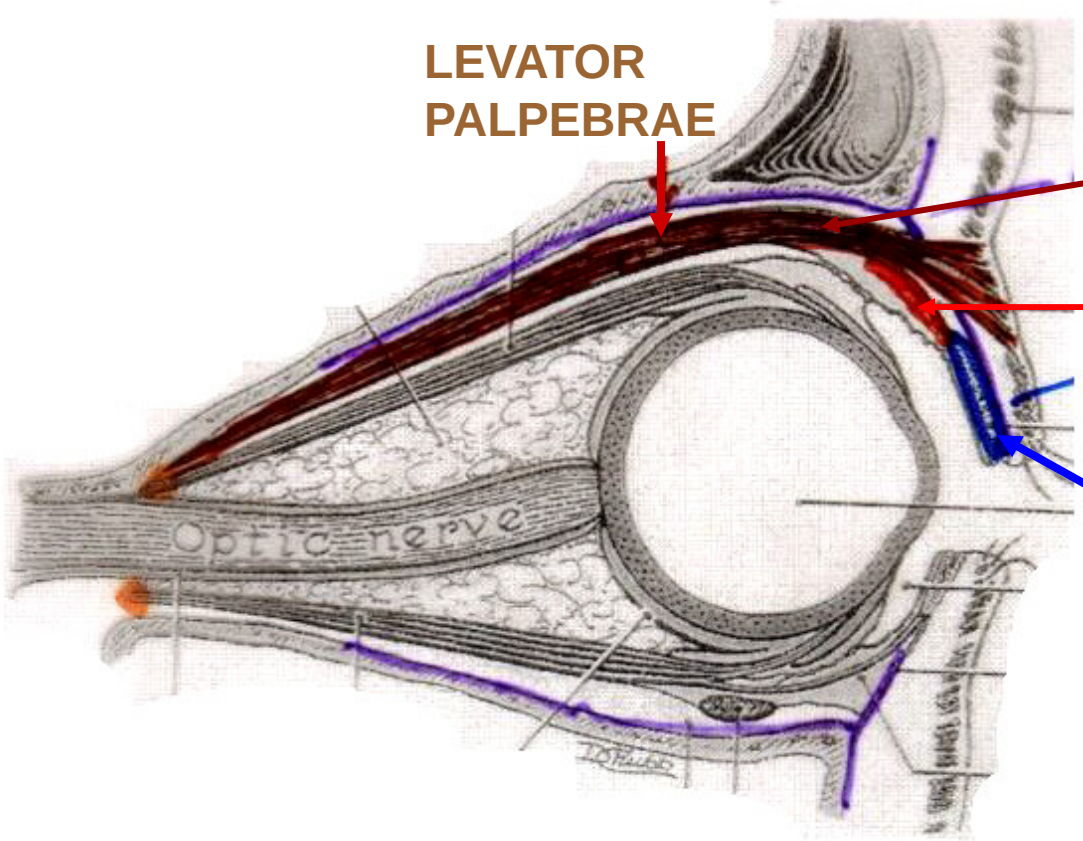

LEVATOR PALPEBRAE SUPERIORIS MUSCLE - ORIGIN FROM TENDINOUS RING - COMPOSED OF **SKELETAL (CN III)** & **SMOOTH (SYMPATHETICS) MUSCLE PARTS**

DAMAGE INNERVATION PTOSIS = DROOPING EYELID

PTOSIS = DROOPING EYELID; CAN BE SIGN OF DAMAGE TO <u>OCULOMOTOR NERVE (III) OR</u> <u>SYMPATHETICS</u>

Ptosis (drooping of the eyelid)

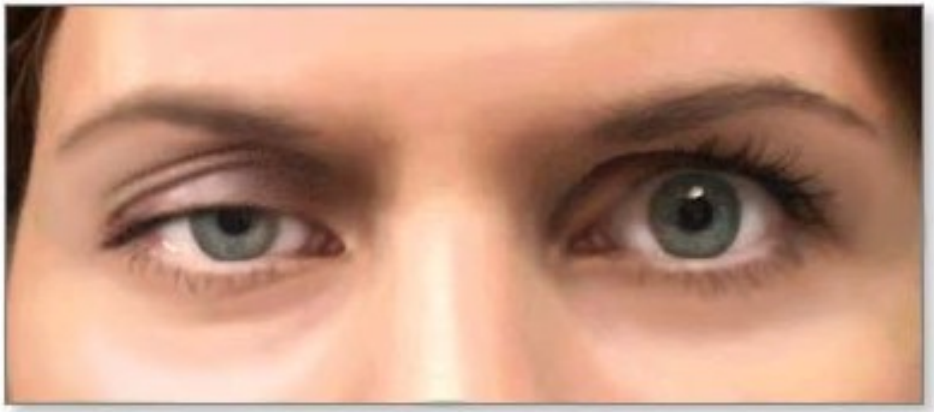

SKELETAL MUSCLE PART

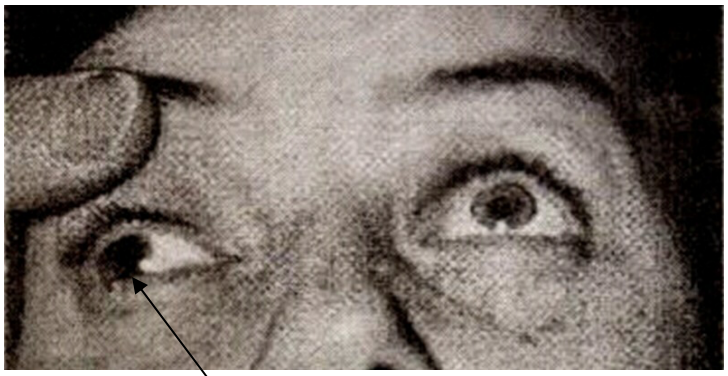

OCULOMOTOR NERVE PALSY
other symptoms:
- Pupil is dilated - denervate pupillary constrictor
- Also affect Eye movements
- Accomodation

SMOOTH MUSCLE PART

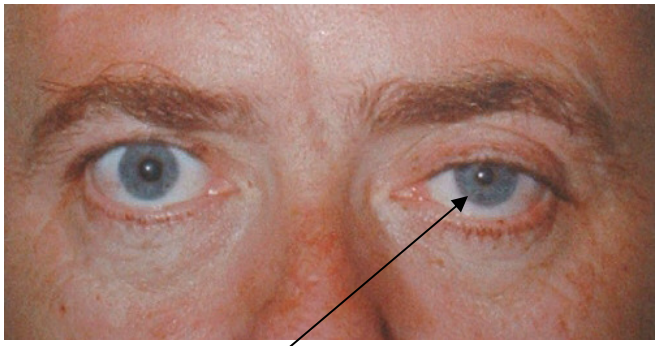

SYMPATHETICS - HORNER'S SYNDROME - 1) Ptosis
- Miosis - constricted pupil
- Anhydrosis - lack of sweating

Sympathetic pathway: out spinal cord T1 and T2; ascend sympathetic chain; synapse Sup. Cervical ganglion; distribute with arteries(Ophthalmic A.)

EYE- STRUCTURE OF EYEBALL- VASCULAR LAYER

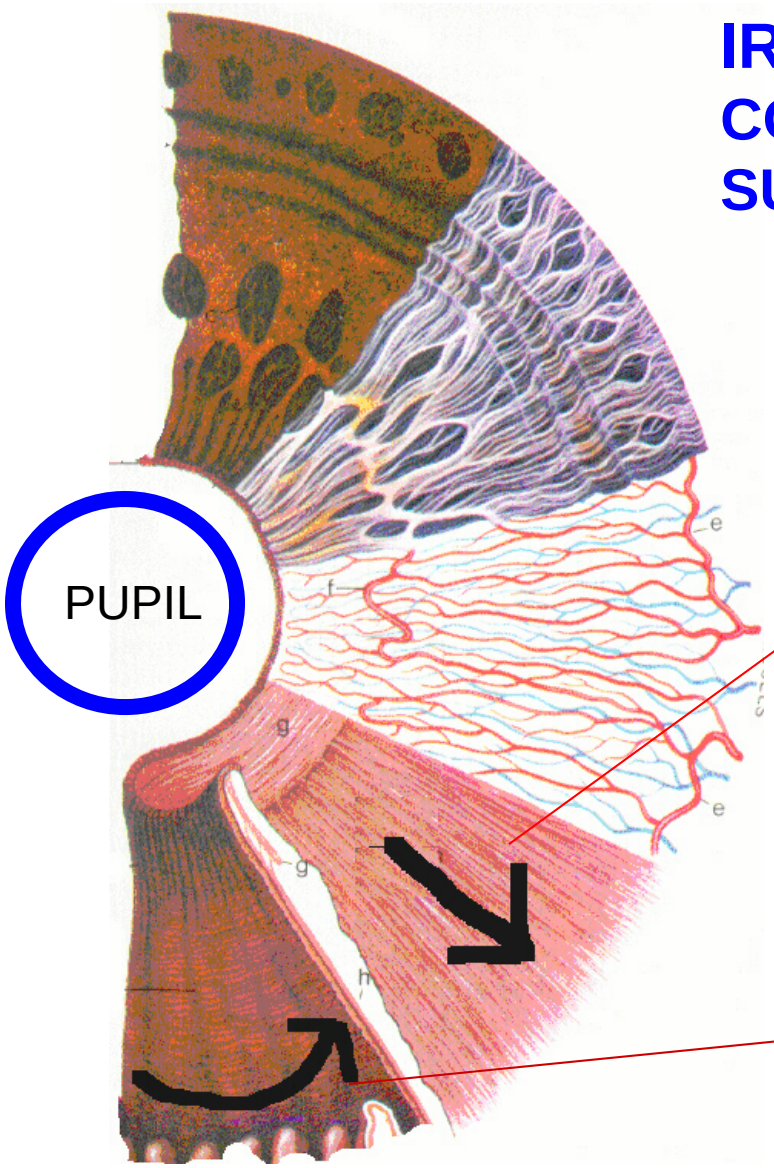

IRIS - PIGMENTED, CONTRACTILE LAYER SURROUNDING PUPIL

DILATOR PUPIL- RADIAL SMOOTH MUSCLE; SYMPATHETICS

CONSTRICTOR PUPIL- CIRCULAR SMOOTH MUSCLE; PARASYMPATHETICS III

PARASYMPATHETIC MECHANISM OF ACCOMODATION

SUSPENSORY LIGAMENTS OF LENS

CILIARY BODY-

ATTACHES SUSPENSORY LIGAMENTS OF LENS

CONTAINS CILIARY MUSCLES

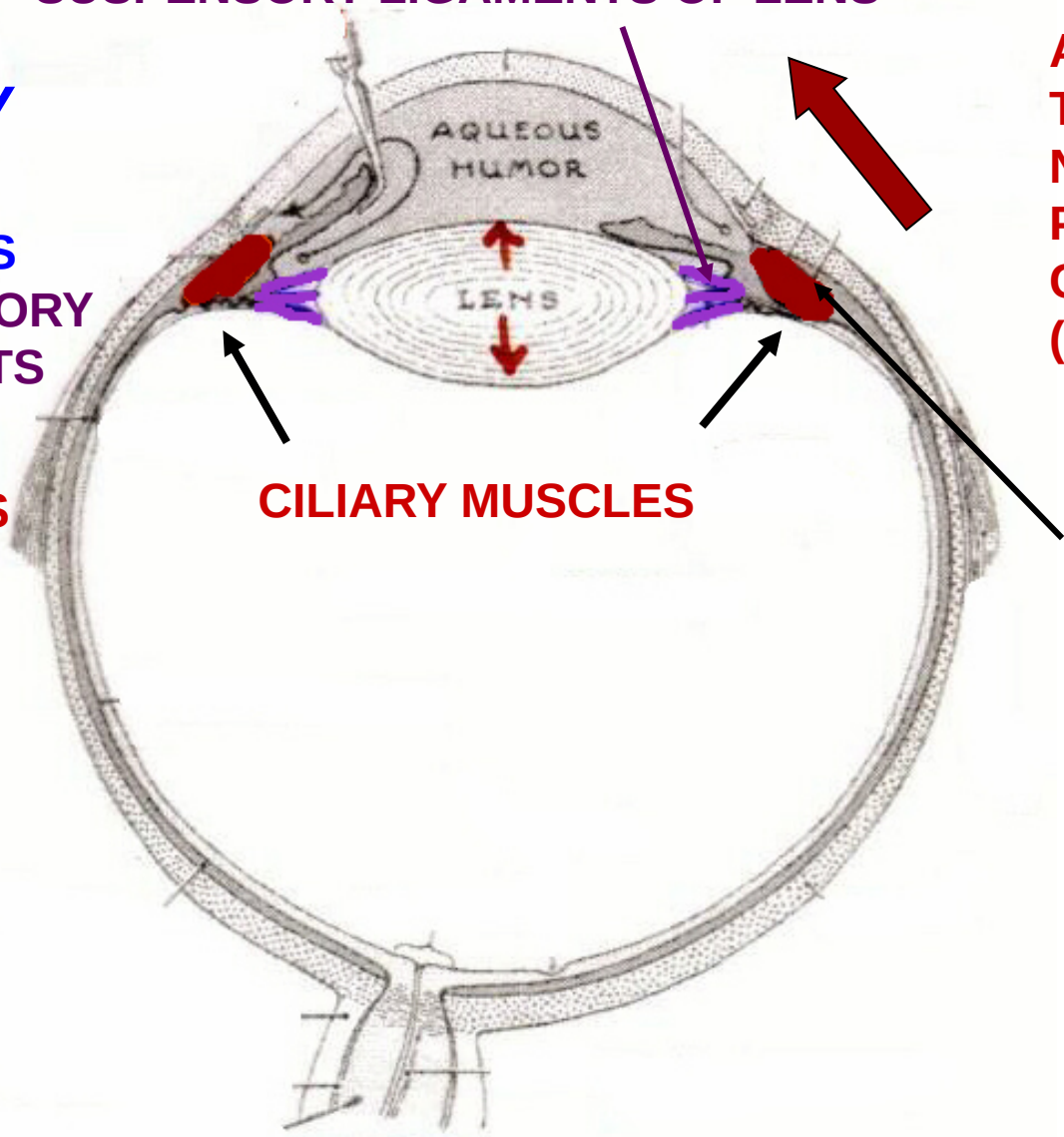

CILIARY MUSCLES

ACCOMODATION- THICKEN LENS FOR NEAR VISION; PARASYMPATHETIC CONTROL- III (CILIARY GANGLION)

CILIARY MUSCLES-

SMOOTH MUSCLES CONTRACT PRODUCE

- <u>RELAXATION</u> OF LIGAMENTS

- THICKENING LENS

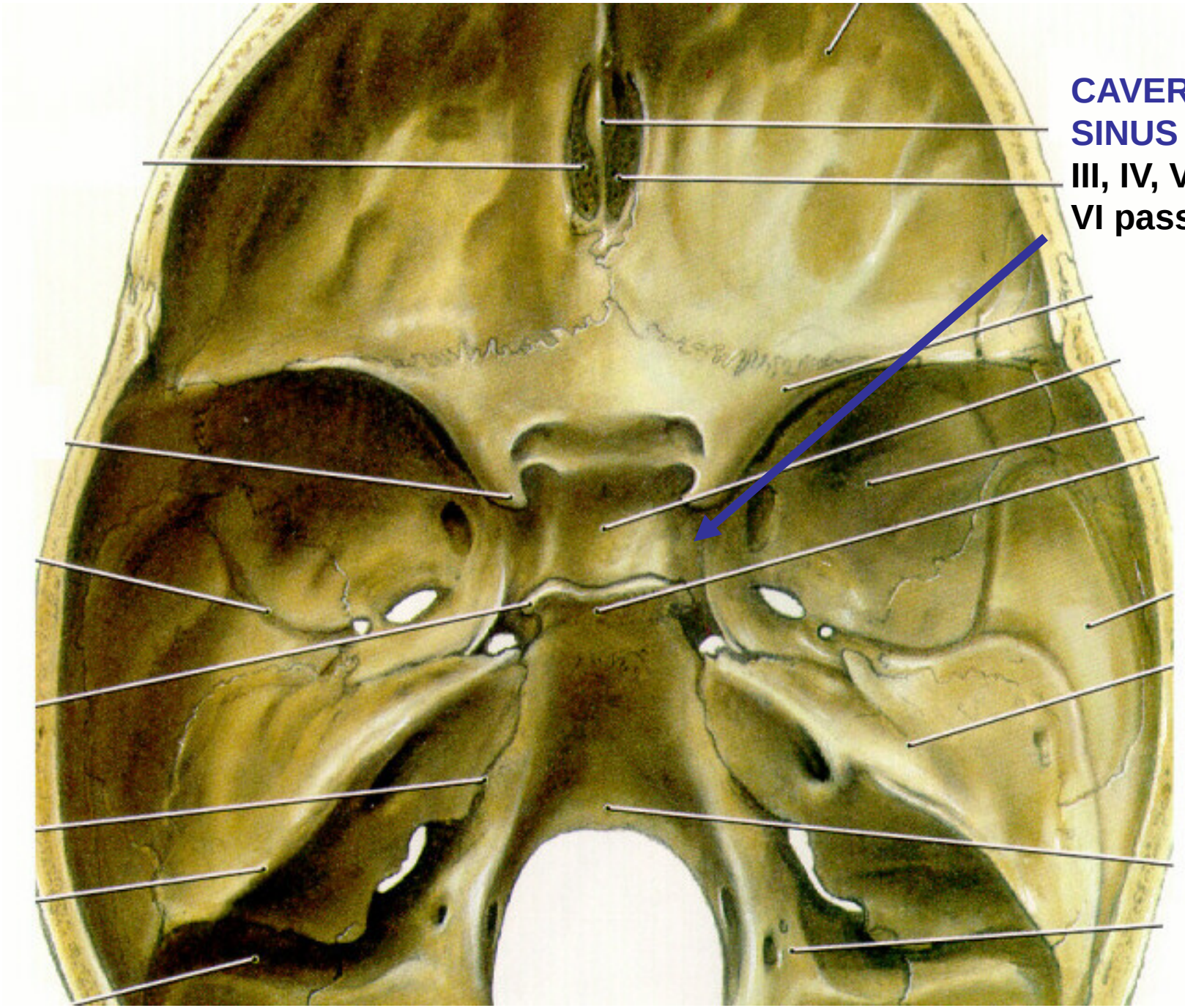

CAVERNOUS SINUS –
III, IV, V1, V2, VI pass through

CAVERNOUS SINUS

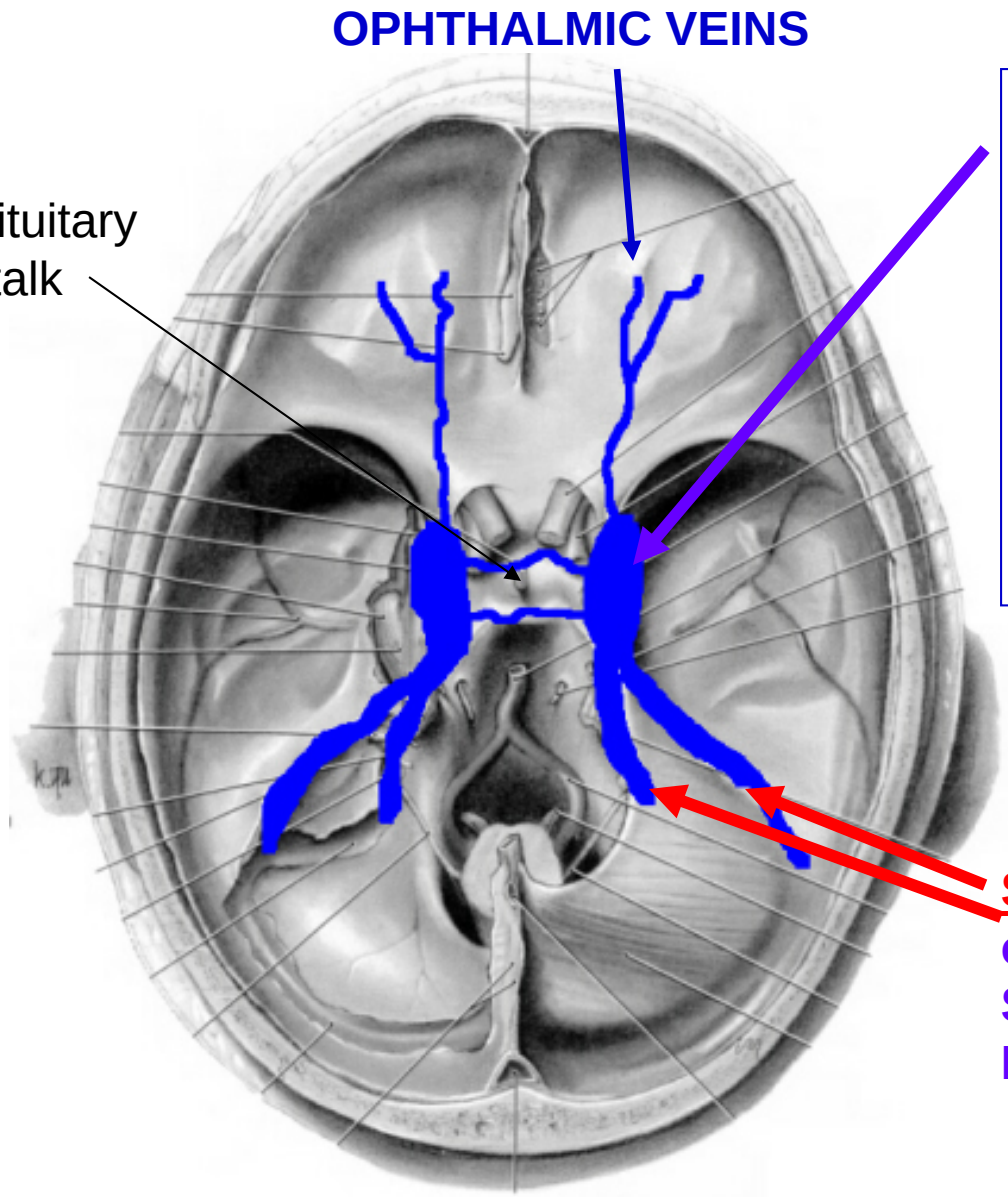

Cavernous sinuses - in middle cranial fossa; on side of the body of the sphenoid bone; receive blood from Sup. and Inf. Ophthalmic veins, Cerebral veins; drain to Sup. and Inf. Petrosal sinuses

Sup. and Inf. Petrosal sinuses - on petrous part of temporal bone
Sup. drains to Transverse sinus
Inf. drains to Internal Jugular V.

SPREAD OF INFECTION FROM FACE TO BRAIN

Anastomoses of Facial and Ophthalmic Vv.
- Ophthalmic veins drain to cavernous sinus (venous sinus inside skull)

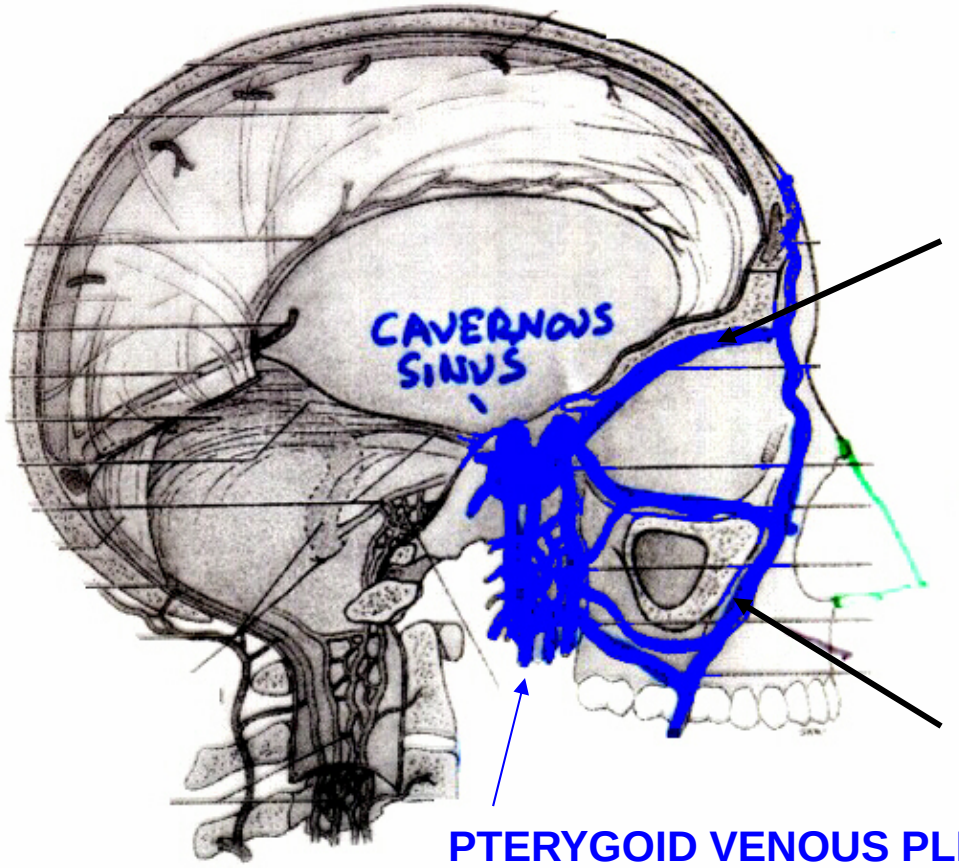

Question: Prolonged infection on face (lateral to nose) produces 'Blurred vision' (Diplopia)
- Why? Prolonged infections spread via veins (pressure low, no valves) through orbit via Ophthalmic Veins to Cavernous Sinus
- Infections lateral to nose particularly dangerous; also infections from teeth can spread through pterygoid venous plexus

STRUCTURES PASSING THROUGH WALL OF CAVERNOUS SINUS - Int. Carotid A., Cranial N.'s III, IV, V1, V2, VI;
SYMPTOM of Infection in Sinus – 'BLURRED' VISION; not affect CN II

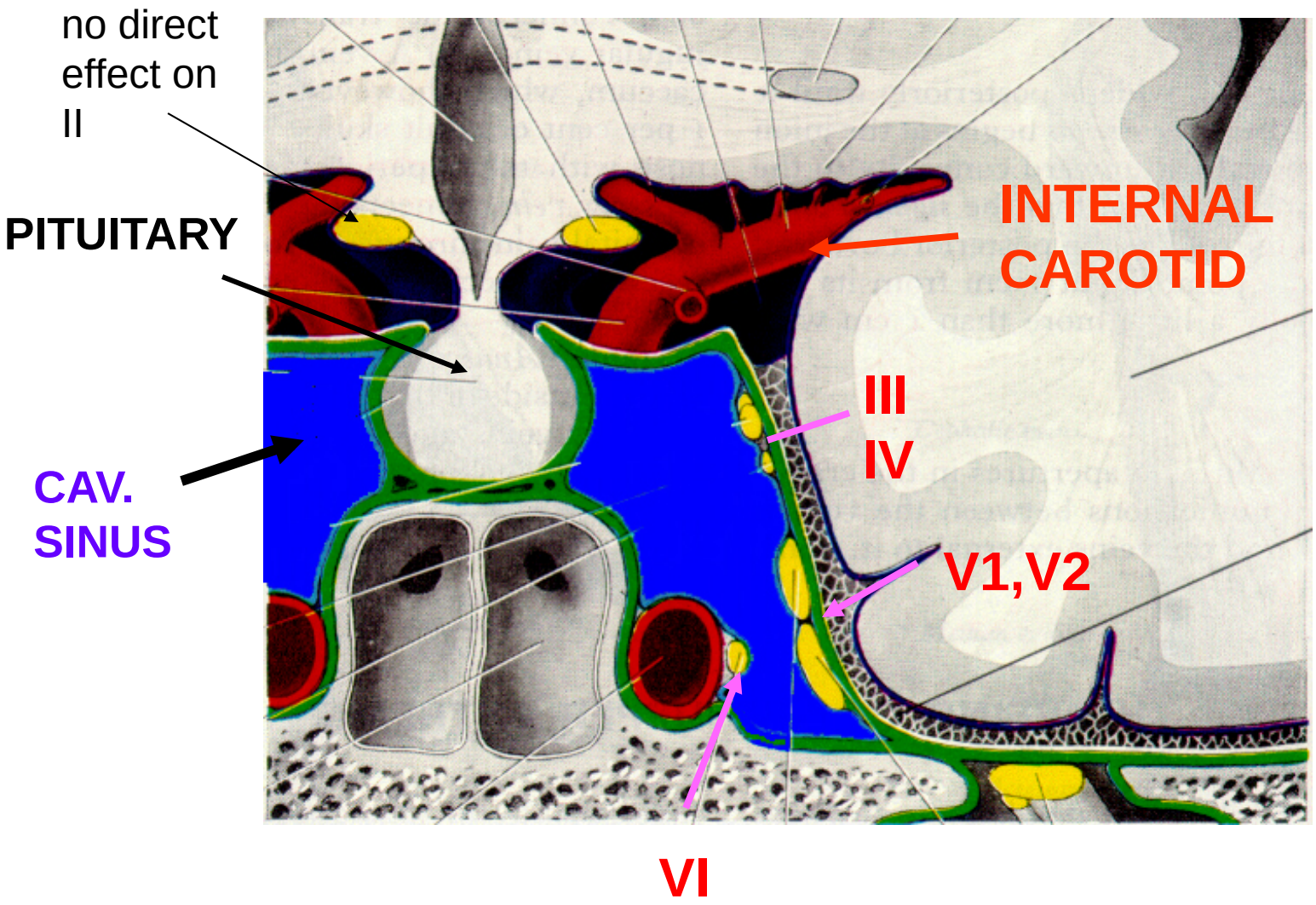

INTERNAL CAROTID ARTERY PASSES IN WALL OF CAVERNOUS SINUS

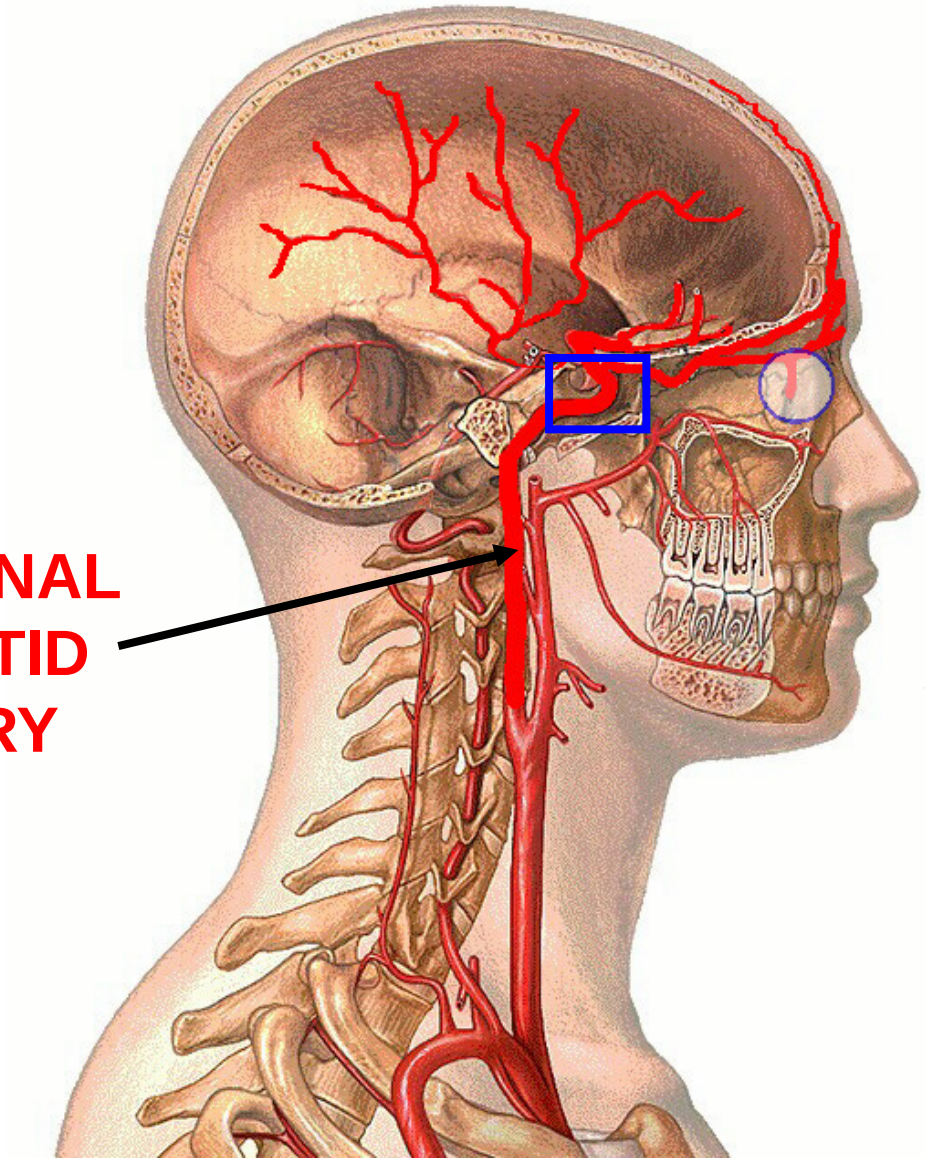

INTERNAL CAROTID ARTERY

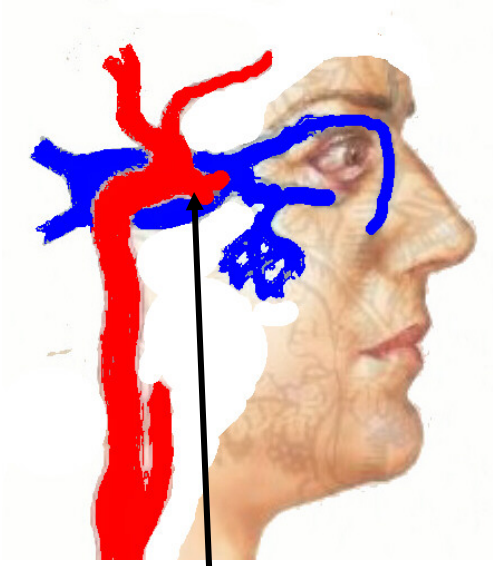

CAROTID-CAVERNOUS FISTULA - artery ruptures into venous sinus

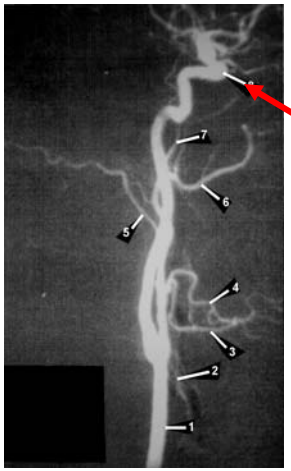

CAROTID SIPHON

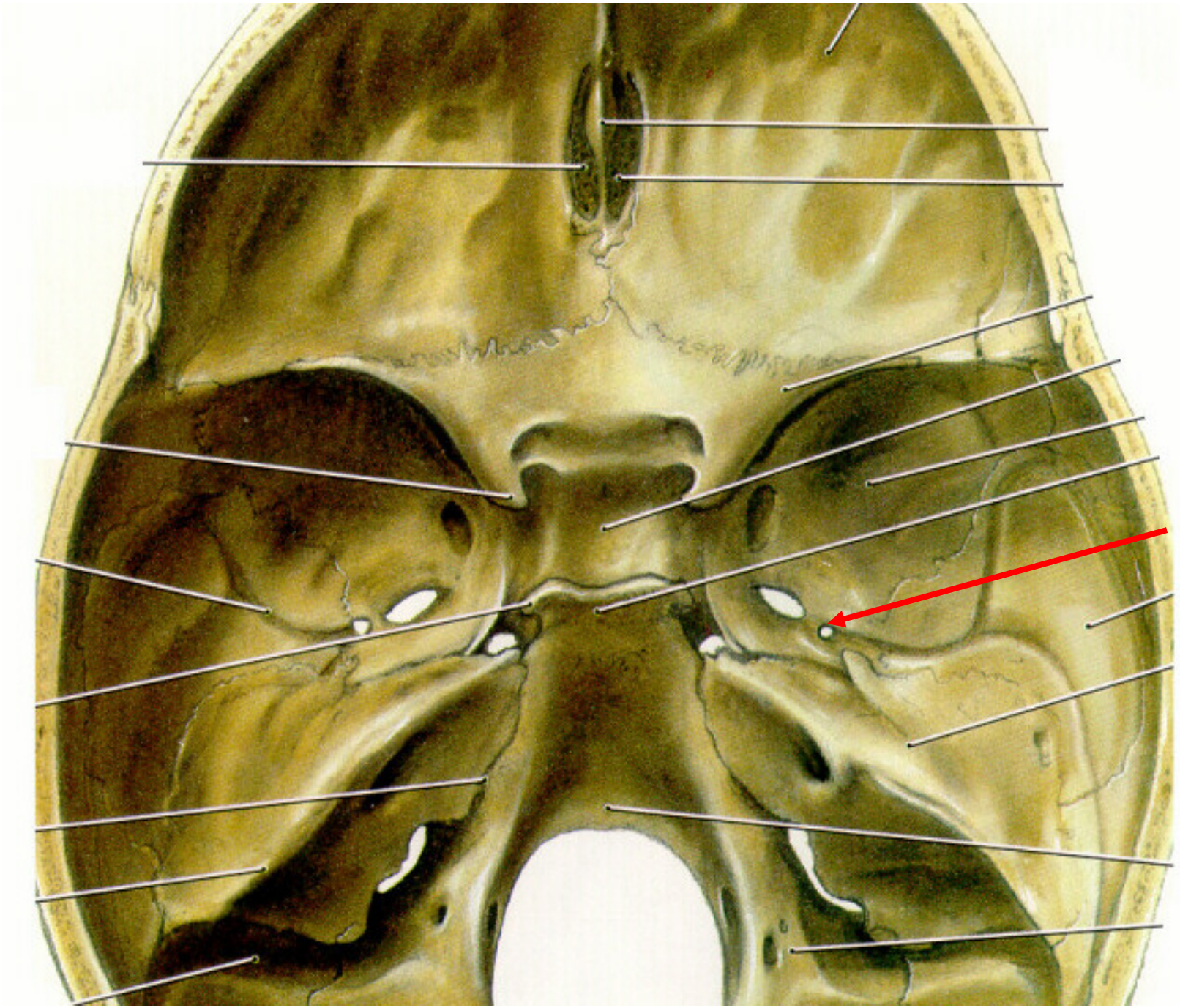

FORAMEN SPINOSUM - MIDDLE MENINGEAL ARTERY, NERVOUS SPINOSUS

INTRACRANIAL HEMATOMAS

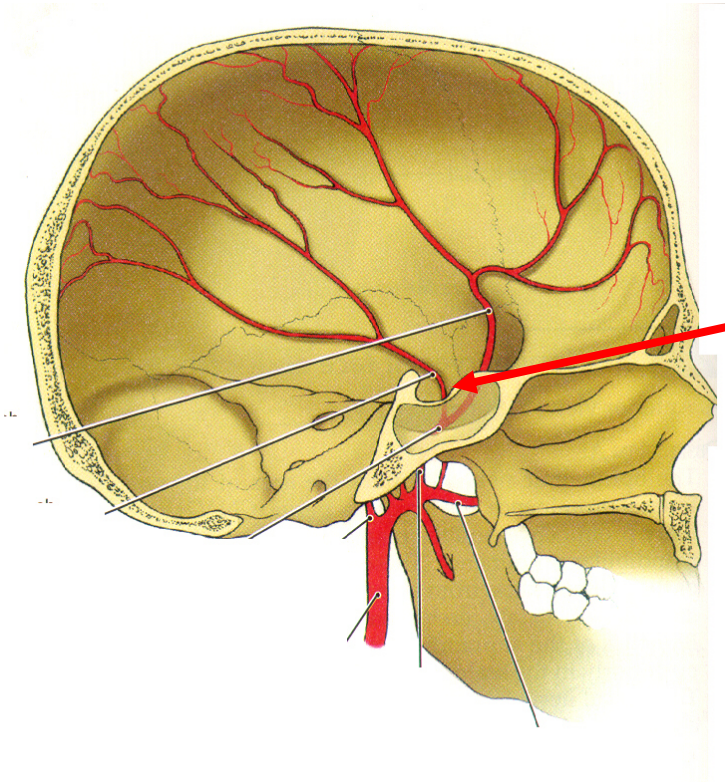

EPIDURAL HEMATOMA

– Middle meningeal artery - branch of Maxillary artery from External Carotid Artery

- provides blood supply to calvarium
- outside Dura

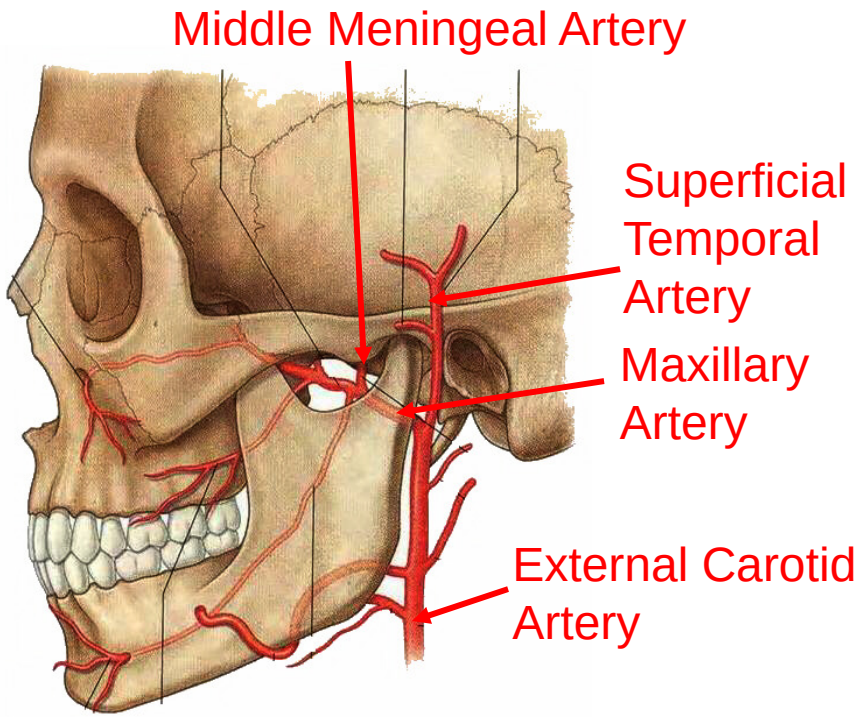

CORONAL SUTURE

CALVARIUM THIN ON LATERAL SIDE OF SKULL

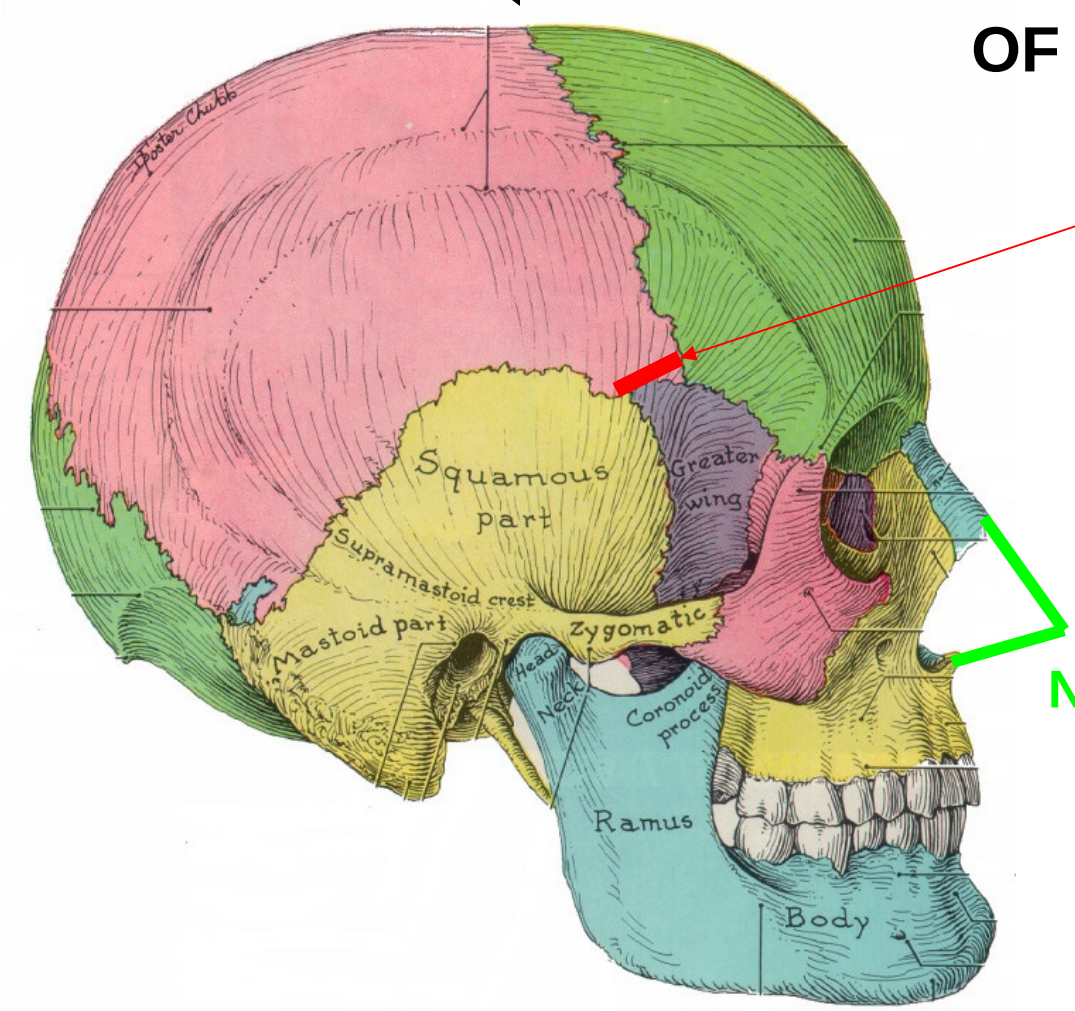

PTERION

- JUNCTION OF TEMPORAL SPHENOID PARIETAL & FRONTAL BONES

NOSE

PIC THANKS TO DR. ALBERICO

BLOWS TO HEAD LATERAL SIDE

EPIDURAL HEMATOMA

NORMAL CT →

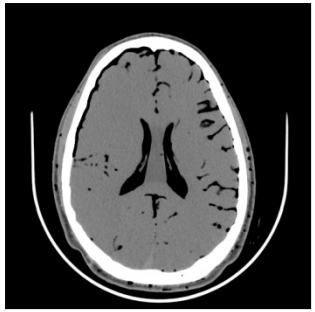

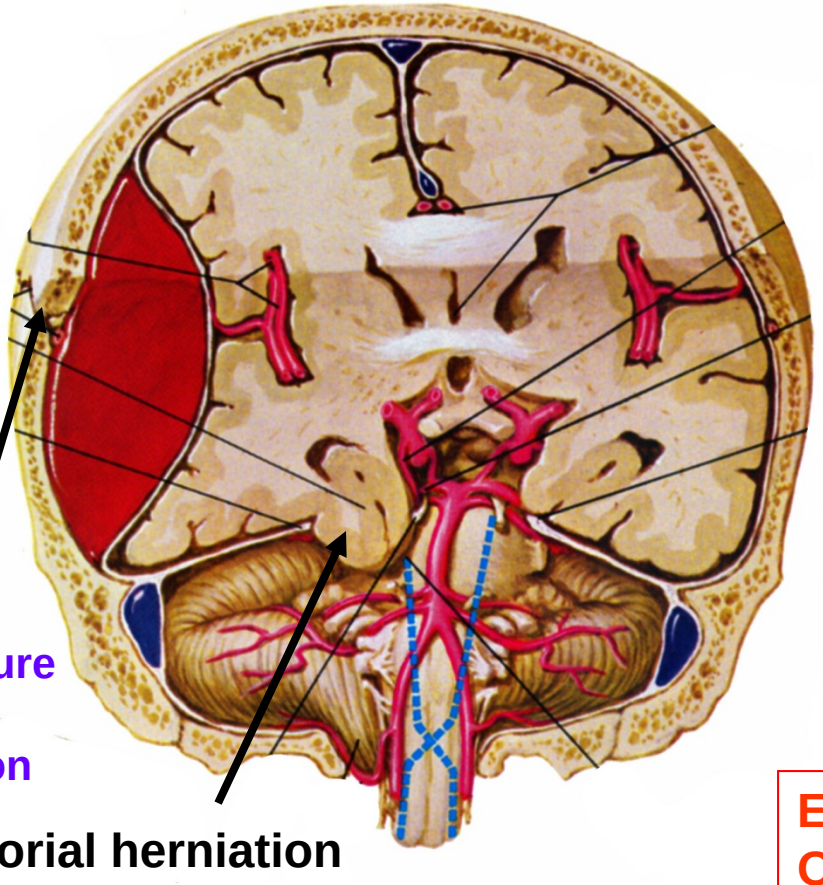

Fracture Near Pterion

tentorial herniation

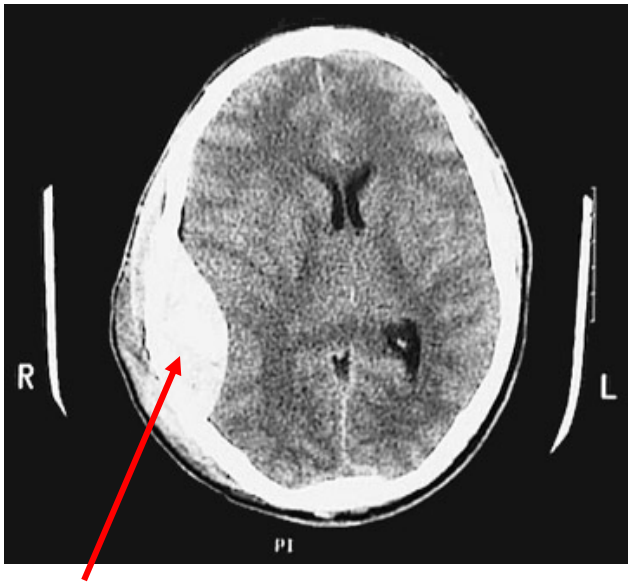

CT - BONE WHITE; NOTE ASYMMETRY LATERAL VENTRICLES

EPIDURAL HEMATOMA - LENS-SHAPED ON CT, MRI

Clinical question - Car accident; patient lucid at first; coma/death within hours.

Why? Bleeding is arterial, profuse and rapid; tentorial herniation causes death.

SUBDURAL HEMATOMA

- Bleed into potential space between Dura & Arachnoid
- from tear 'Bridging' vein or sinus
- bleeding often slow
- chronic subdural hematomas can remain undetected

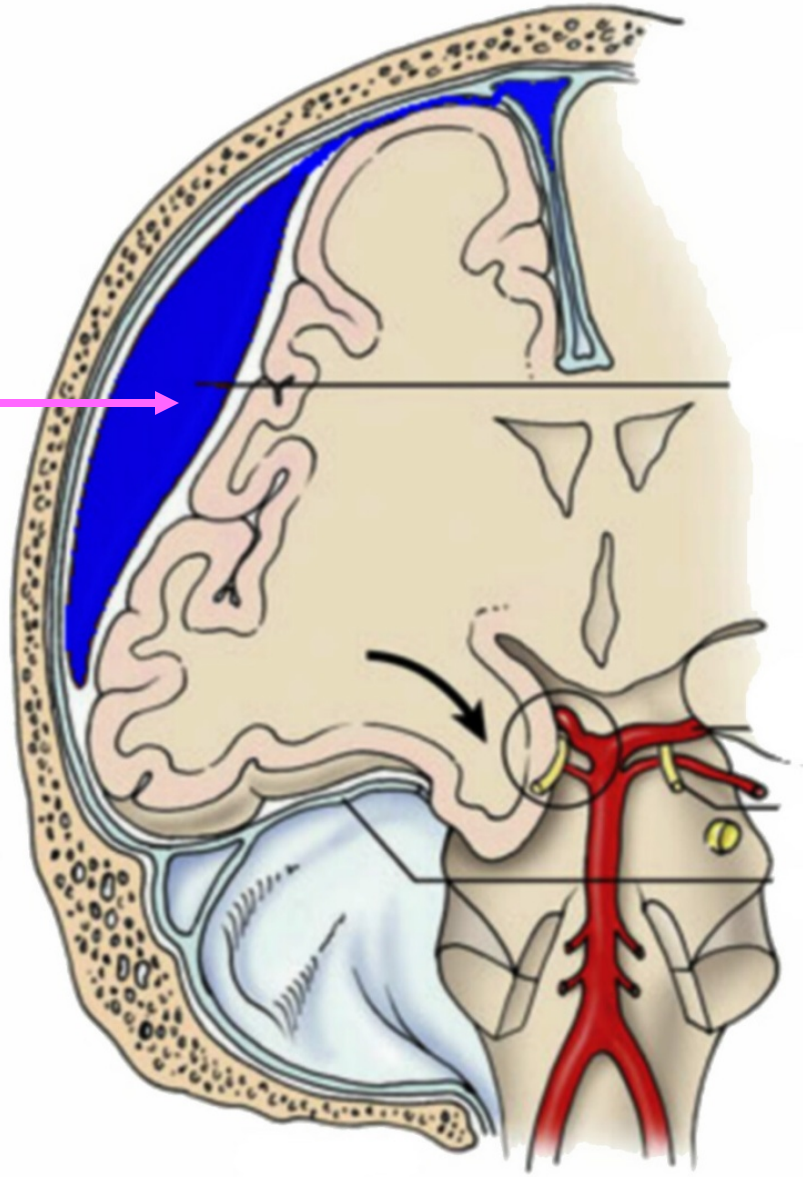

Crescent-shaped hematoma on CT/MRI

Clinical questions -
causes can be diverse
- trauma; car accident; headaches days later
- non-traumatic - in elderly

VENOUS DRAINAGE INTO SUPERIOR SAGITTAL SINUS

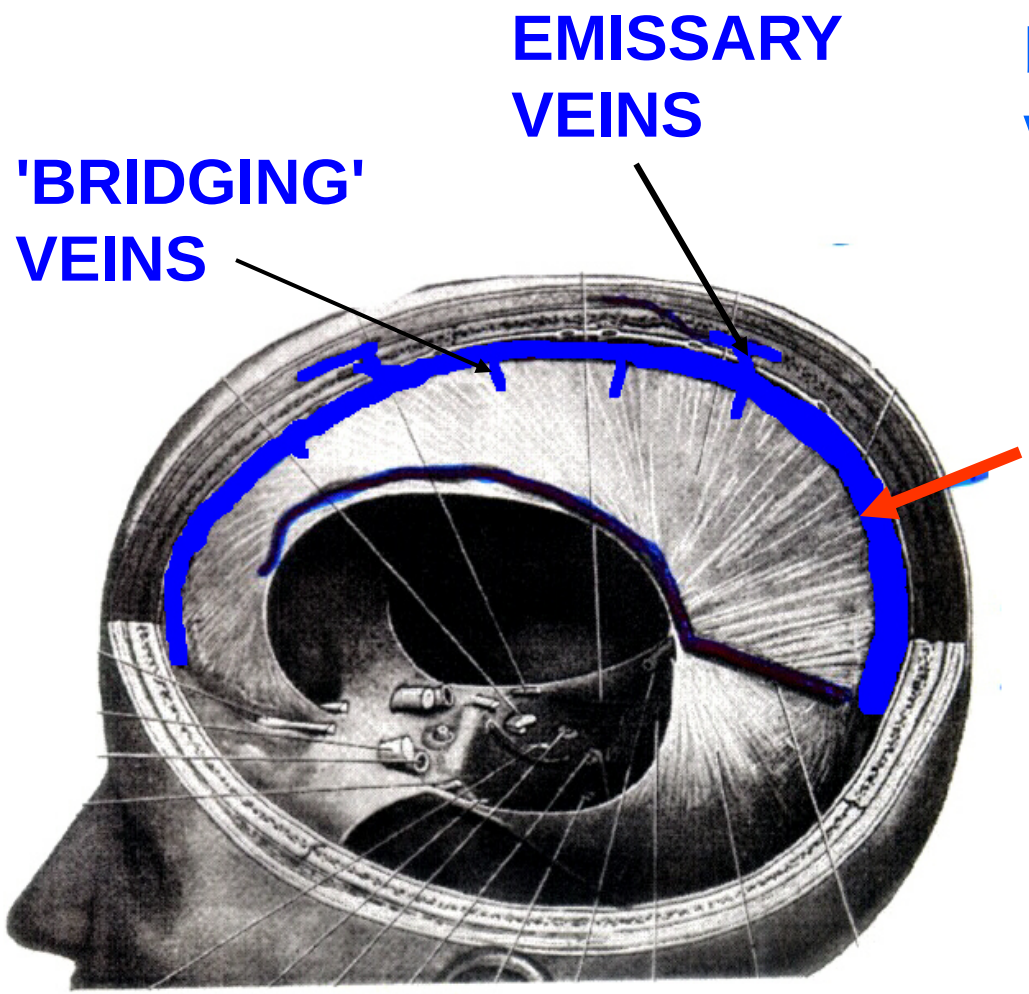

SUBDURAL HEMATOMA

Receive blood from brain, orbit, emissary veins

Superior Sagittal Sinus – in upper border of falx cerebri; blood from Superior Cerebral veins through 'bridging veins'; also blood from emissary veins (pass from diploe in calvarium or through bones of skull)

BLOOD FROM CEREBRAL CORTEX DRAINS TO SUPERIOR SAGITTAL SINUS

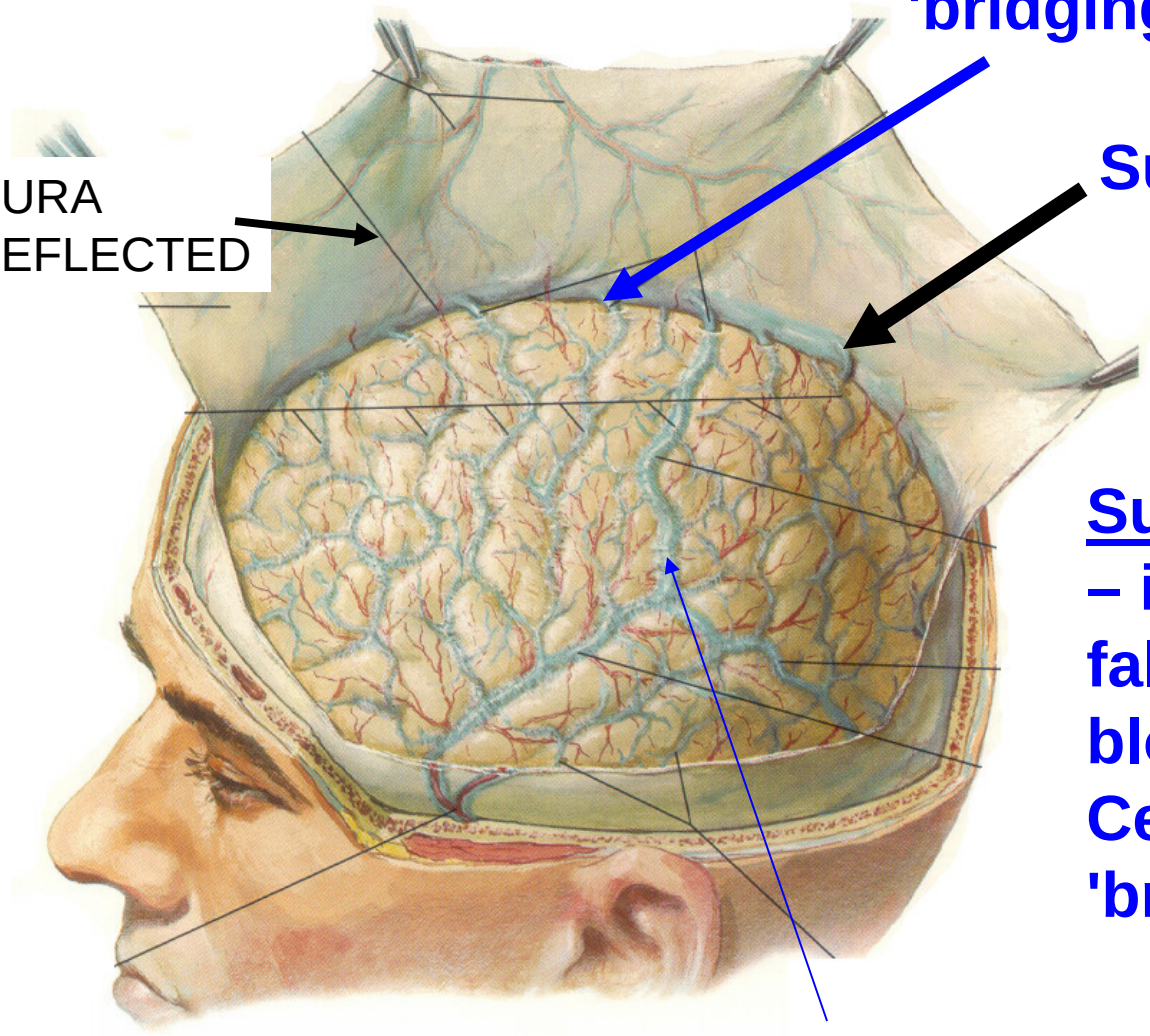

<u>Superior Sagittal Sinus</u>
– in upper border of falx cerebri; receives blood from Superior Cerebral veins through 'bridging veins'

CSF REABSORBED INTO VENOUS SINUSES

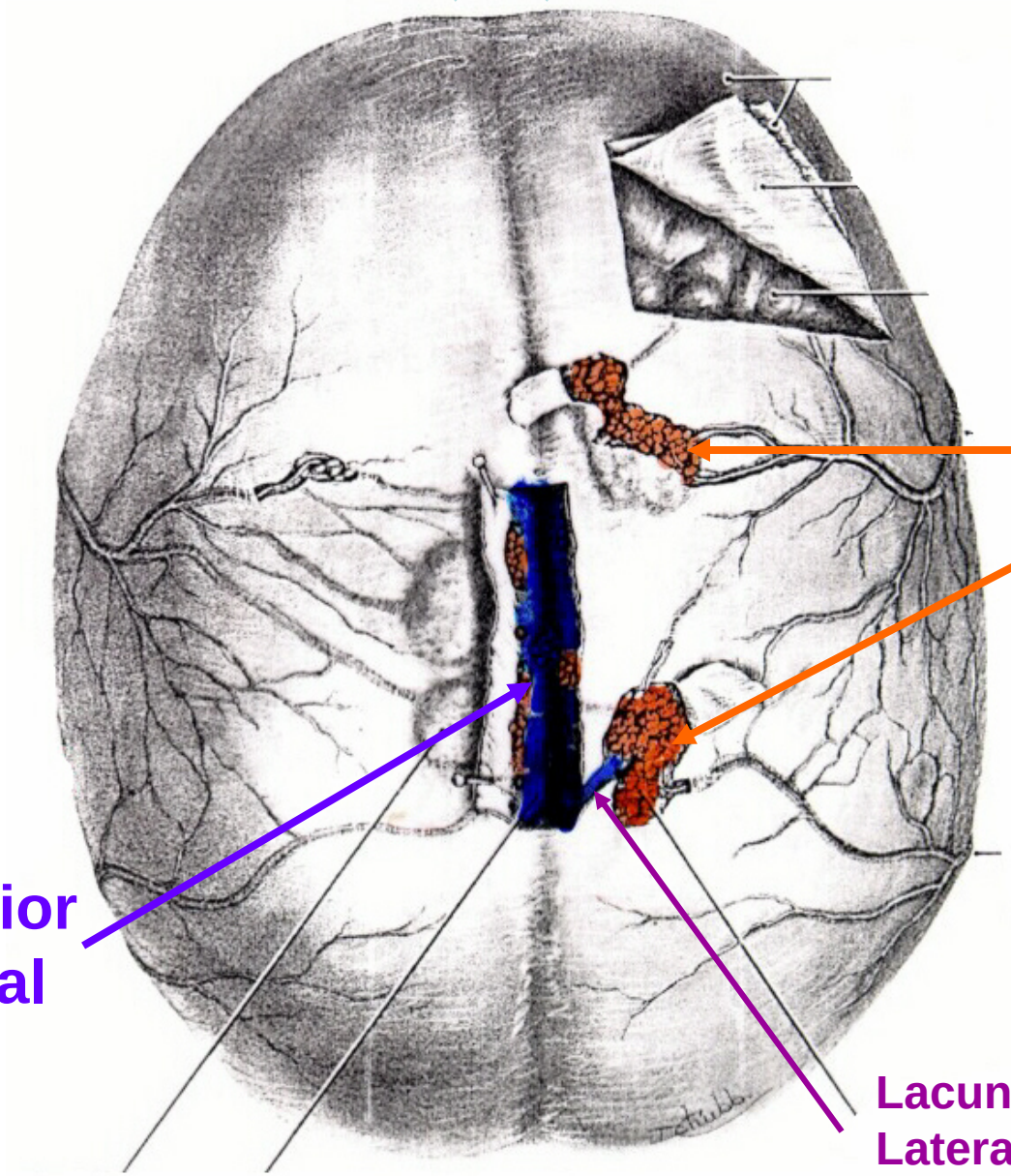

Arachnoid villi - sites of CSF reabsorption

Superior Sagittal Sinus

Lacunae Laterales

CSF REABSORBED INTO VENOUS SINUSES

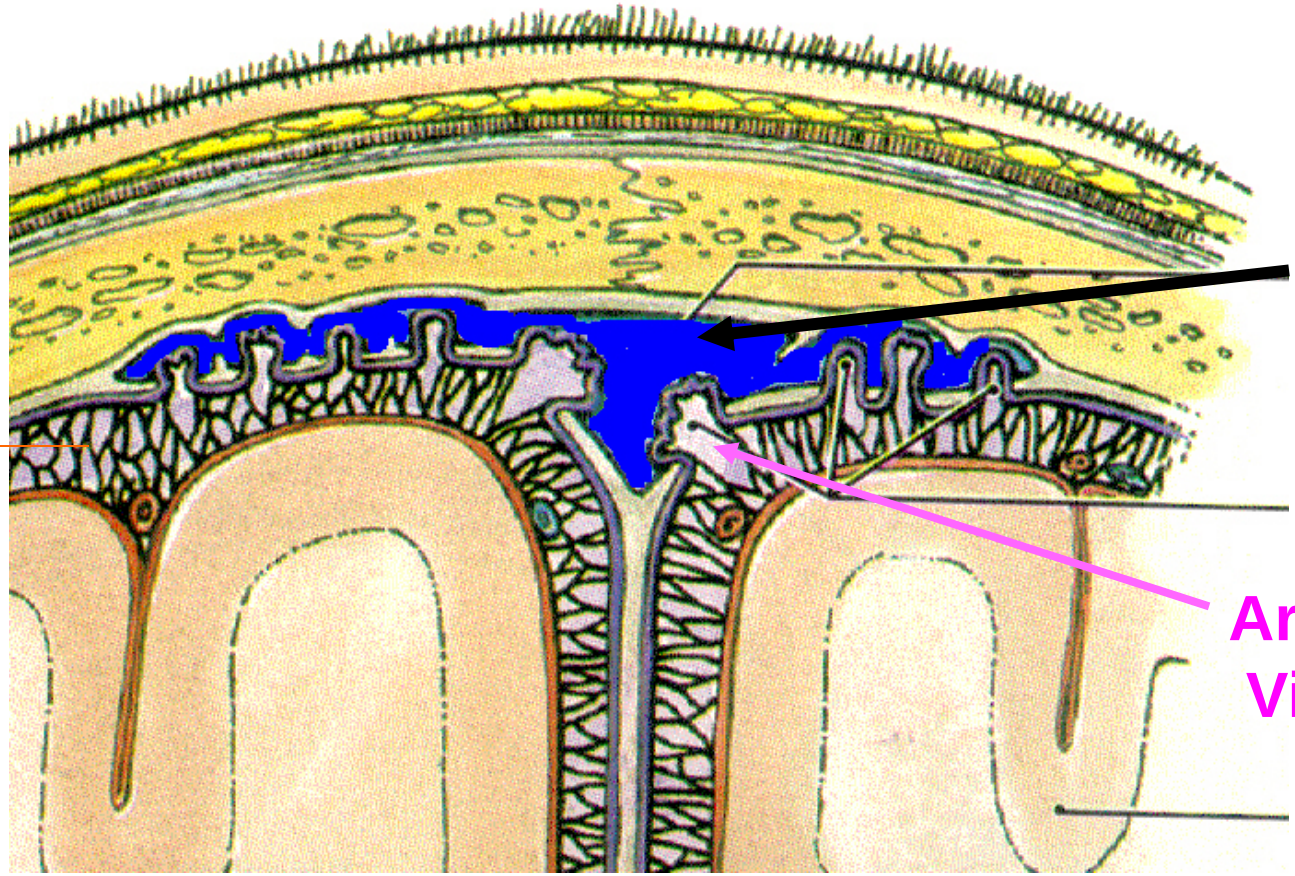

CSF reabsorbs into venous sinuses at Arachnoid Villi;

Reduced Re-Absorption - Clinical: Communicating Hydrocephalus - In elderly arachnoid villi can become calcified- Arachnoid Granulations

REVIEW OF HEAD AND NECK: CRANIAL NERVES, ETC.

OUTLINE: USE SKULL AND CRANIAL NERVES AS BASIS FOR REVIEW

1. INTRODUCTION: SKULL, DURA, VENOUS SINUSES

2. CRANIAL NERVES AND AREAS SUPPLIED

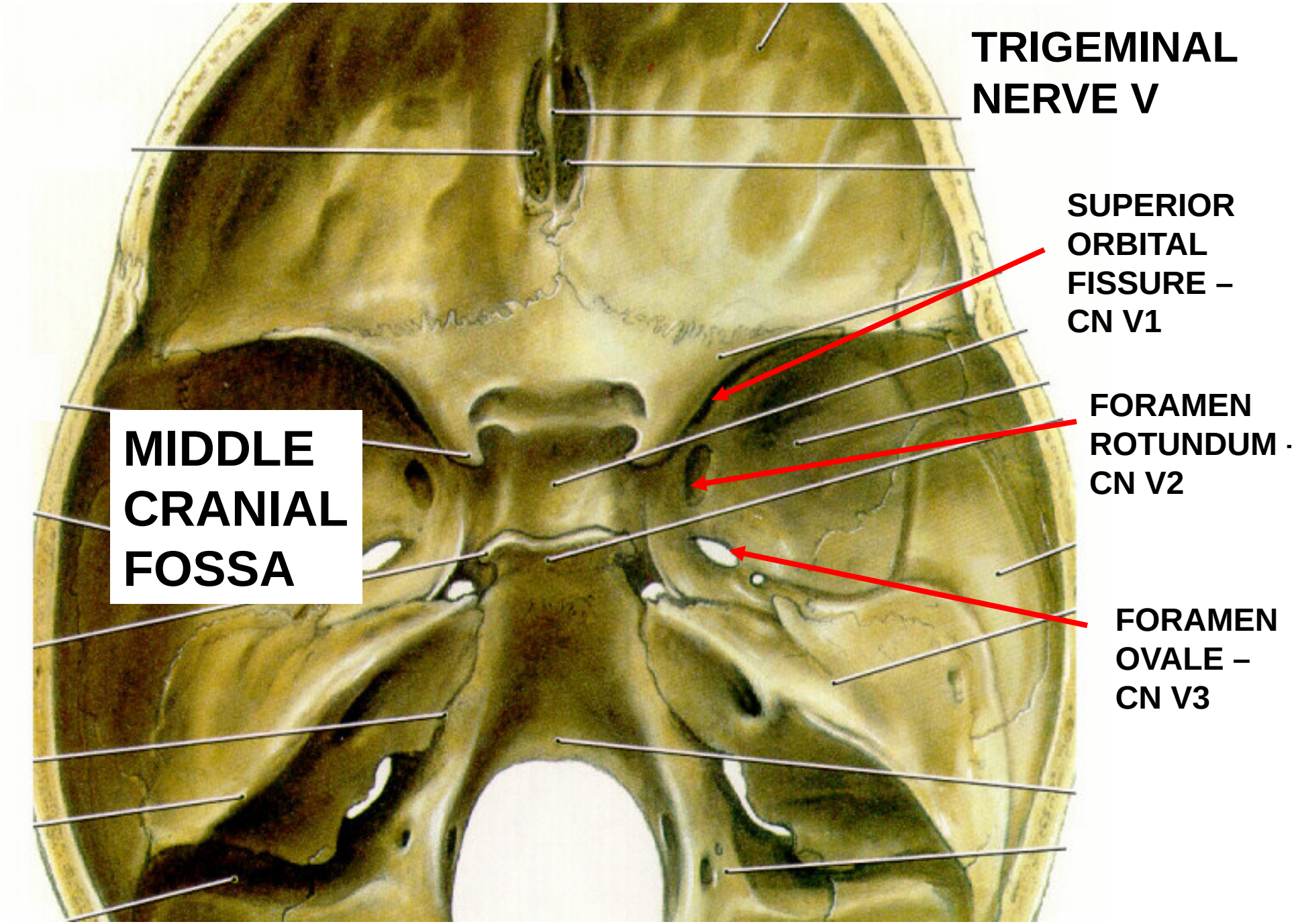
TRIGEMINAL NERVE V
SUPERIOR ORBITAL FISSURE – CN V1
FORAMEN ROTUNDUM - CN V2
FORAMEN OVALE – CN V3
MIDDLE CRANIAL FOSSA

V. TRIGEMINAL NERVE – SENSORY INNERVATION TO SKIN OF HEAD – 3 DIVISIONS

V1 – OPHTHALMIC DIVISION

Boundary- Lateral edge of eye

V2 – MAXILLARY DIVISON

Boundary Lateral edge of mouth

V3 – MANDIBULAR DIVISION

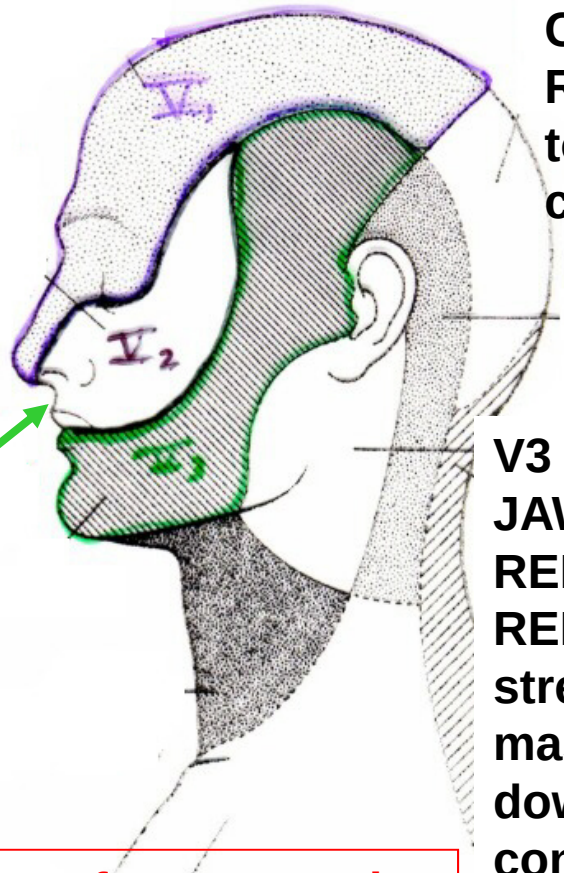

V1 - also CORNEAL REFLEX - touch cornea V1 close eye VII

V3 - JAW JERK REFLEX (STRETCH REFLEX) - ALL V stretch muscles mastication (tap down on mandible) contract muscles of mastication (mouth closes)

Numbness in Region of Face - can be correlated with damage to specific division of Trigeminal nerve

TRIGEMINAL SENSORY DISTRIBUTION

sensory to skin, ORAL cavity, NASAL cavity, joints

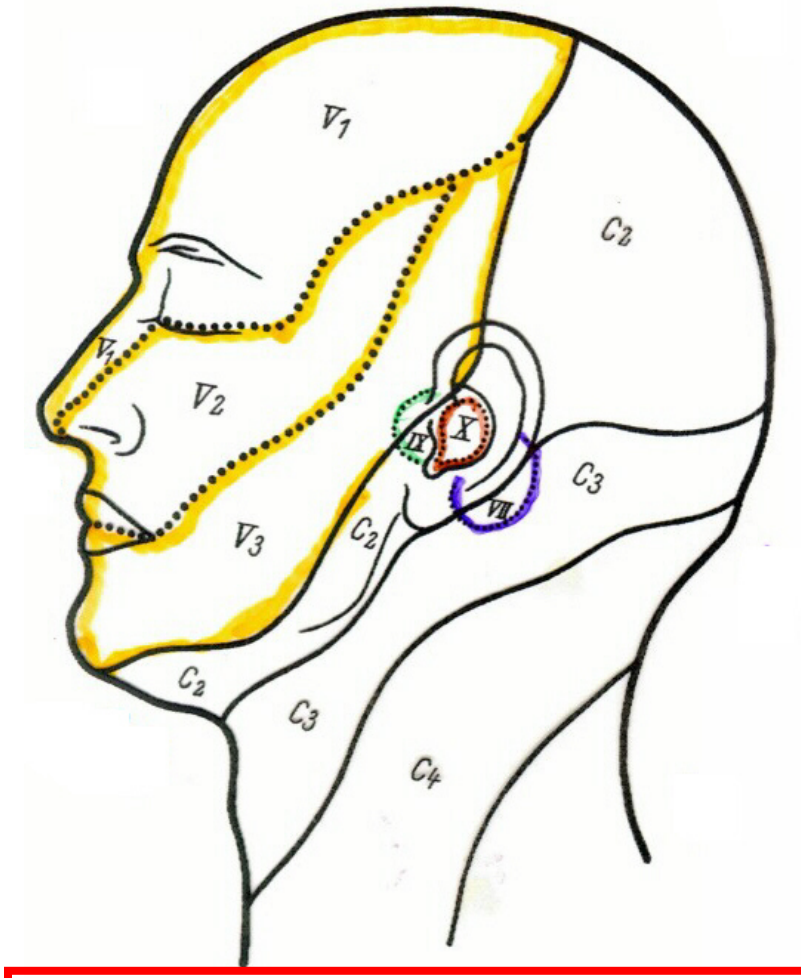

ALMOST ALL
TRIGEMINAL V
EXCEPTION:
SKIN OF OUTER EAR
ALSO
1) VII- FACIAL
2) IX - GLOSSO-PHARYNGEAL
3) X - VAGUS

PAIN IN EXTERNAL AUDITORY MEATUS : BELL'S PALSY (VII) - PARALYSIS OF FACIAL MUSCLES; IN RECOVERY, PATIENTS COMPLAIN OF EARACHES

STRUCTURES DERIVED FROM BRANCHIAL ARCHES

ARCH/NERVE	SKELETAL	LIGAMENTS	MUSCLES
First (V)	1) Malleus 2) Incus	1) Ant. ligament of malleus 2) Spheno-mandibular ligament	1) Muscles of Mastication 2) Tensor tympani 3) Tensor palati 4) Mylohyoid 5) Ant. belly of Digastric
Second (VII)	1) Stapes 2) Styloid process 3) Hyoid bone - lesser horn, upper half of body	Stylohyoid ligament	1) Muscles of Facial Expression 2) Stapedius 3) Stylohyoid 4) Post. belly of Digastric
Third (IX)	Hyoid bone - greater horn, lower half of body	----------	Stylopharyngeus
Fourth (X)	Cartilages of Larynx	----------	1) All muscles of Larynx 2) All muscles of Pharynx (except Stylopharyngeus) 3) All muscles of Soft Palate (except Tensor palati)
Sixth (XI)	----------	----------	1) Sternocleidomastoid 2) Trapezius

V MOTOR - DIVERSE

MUSCLES OF MASTICATION

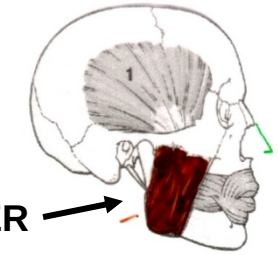

MASSETER

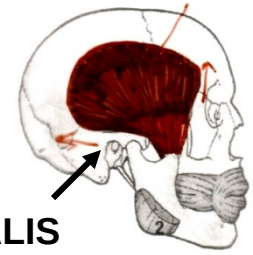

TEMPORALIS

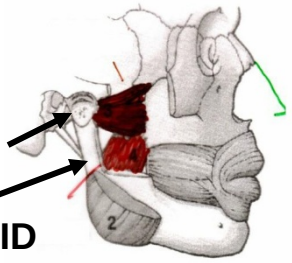

LAT. AND MED. PTERYGOID

TENSOR PALATI - tenses palate in swallowing

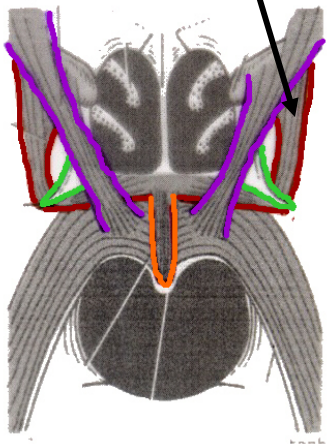

TENSOR TYMPANI - dampen sound

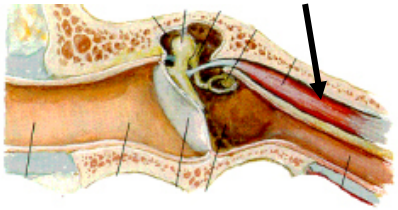

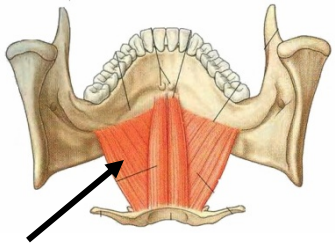

MYLOHYOID - raise floor of mouth in swallowing

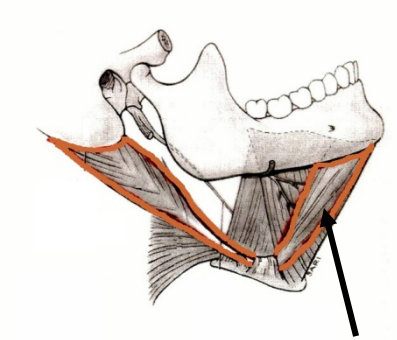

ANT. BELLY OF DIGASTRIC - opens mouth

ACTIONS - MOST CLOSE MOUTH - MASSETER, TEMPORALIS, MED. PTERYGOID
OPEN MOUTH - LAT. PTERYGOID

V DAMAGE - MOSTLY SENSORY, MOTOR SYMPTOM

V - DAMAGE: PARALYZE MUSCLE MASTICATION, DIFFICULTY CHEWING

LATERAL PTERYGOID

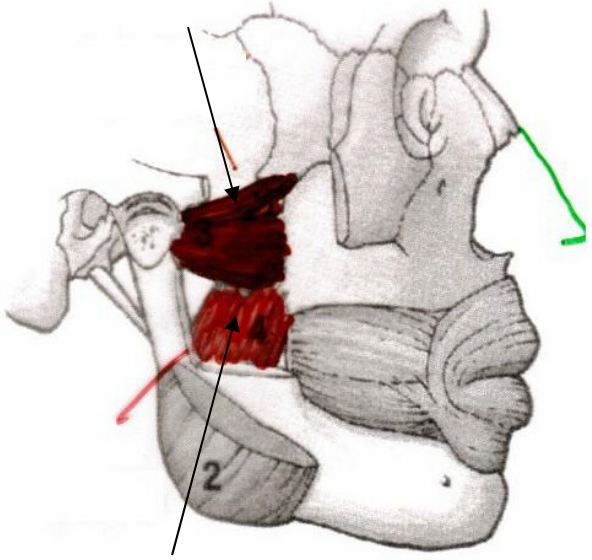

MEDIAL PTERYGOID

VIEW FROM BEHIND MANDIBLE

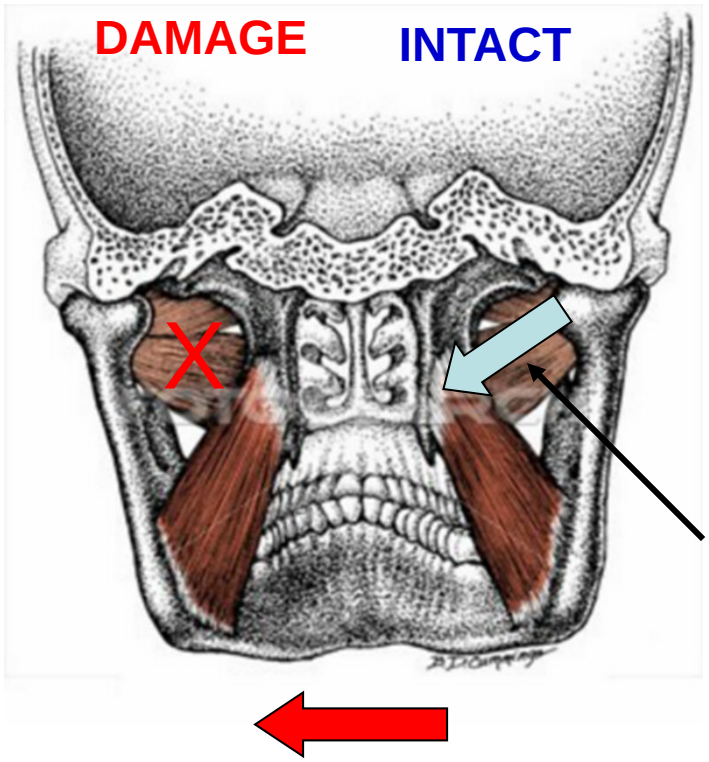

PUSHED BY INTACT LATERAL PTERGYOID ONOPPOSITE SIDE

CLINICAL: WEAKNESS MUSCLE OF MASTICATION -

MOTOR SIGN: OPENING MOUTH - JAW DEVIATES TOWARD PARALYZED SIDE -

CAUSE: EX. TUMOR AT FORAMEN OVALE

VII - FACIAL AND VIII - VESTIBULO-COCHLEAR

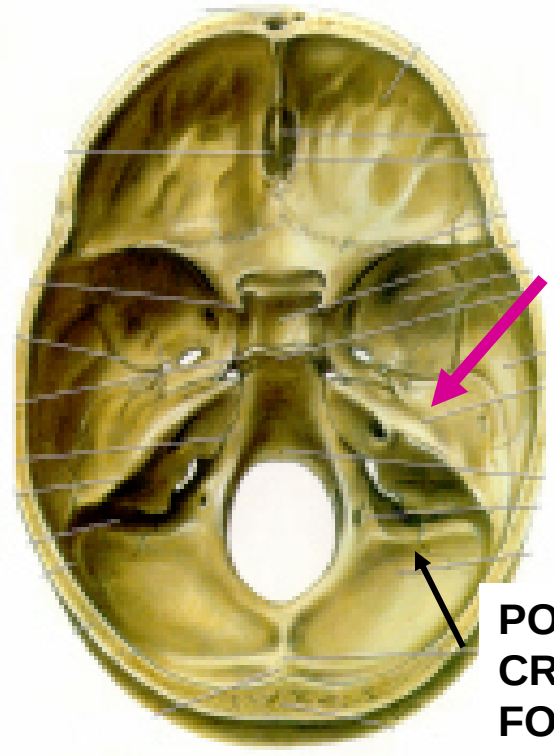

Petrous part of temporal bone

POST. CRANIAL FOSSA

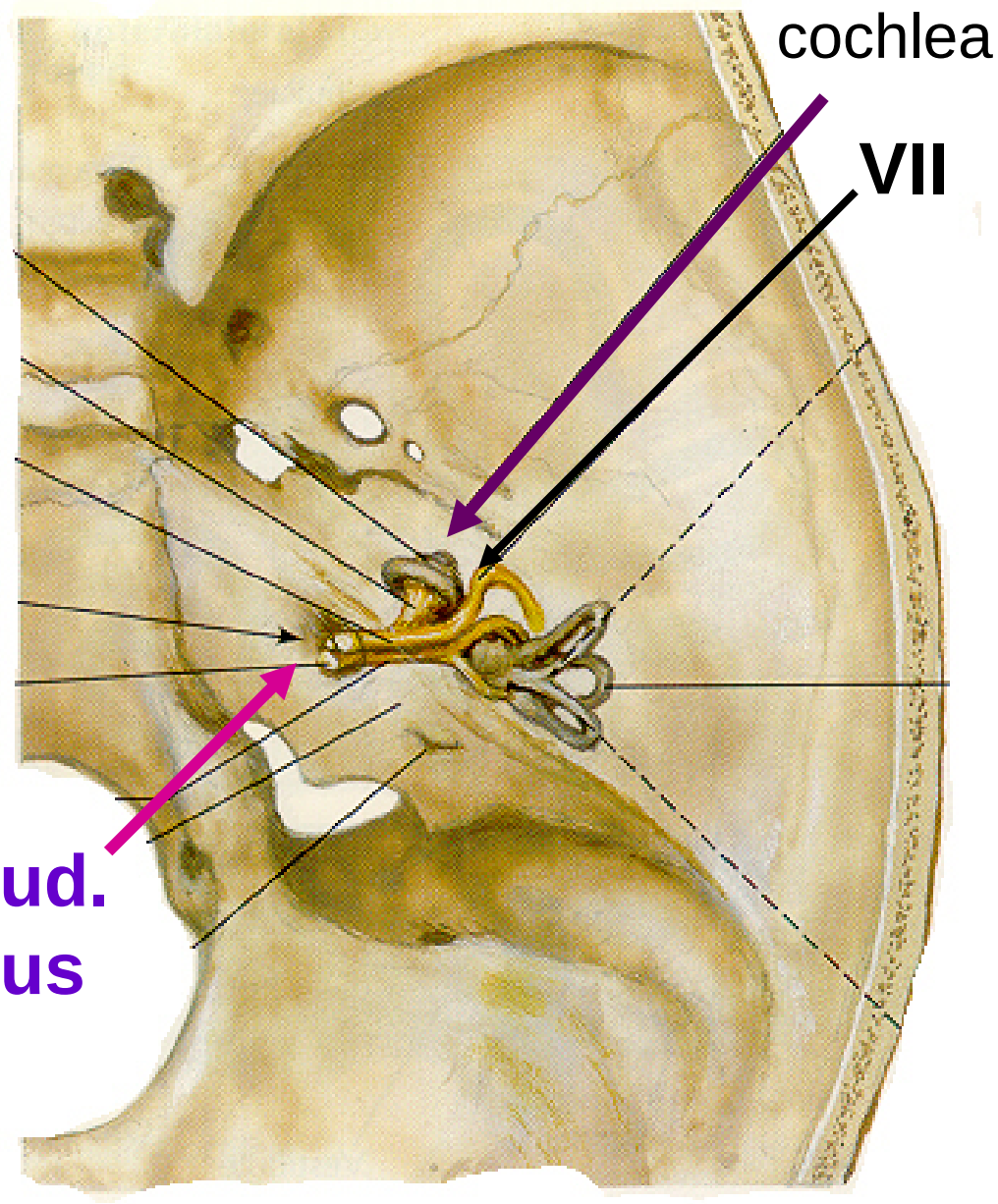

VIII - ends in Cochlea and Semicircular Canals (Vestibular Apparatus)

VII MOTOR

MUSCLES OF FACIAL EXPRESSION

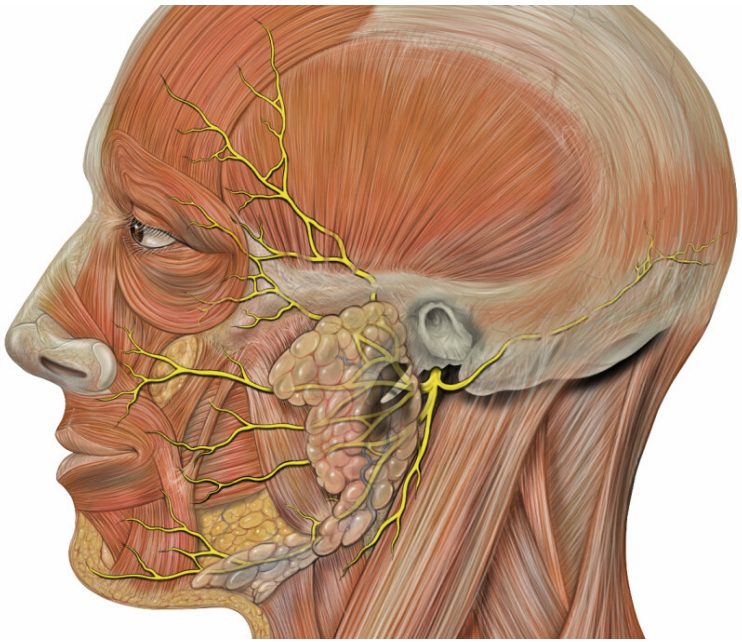

STYLOHYOID,
POST. BELLY DIGASTRIC

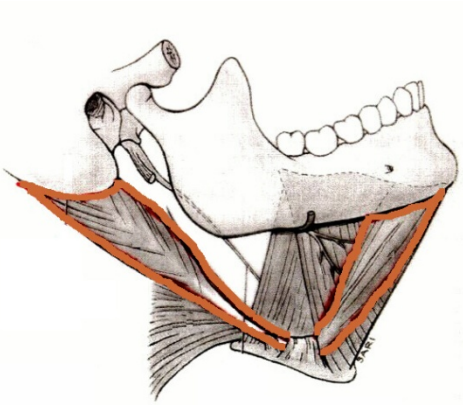

STAPEDIUS - DAMAGE
HYPERCOUSIA - sounds seem too loud

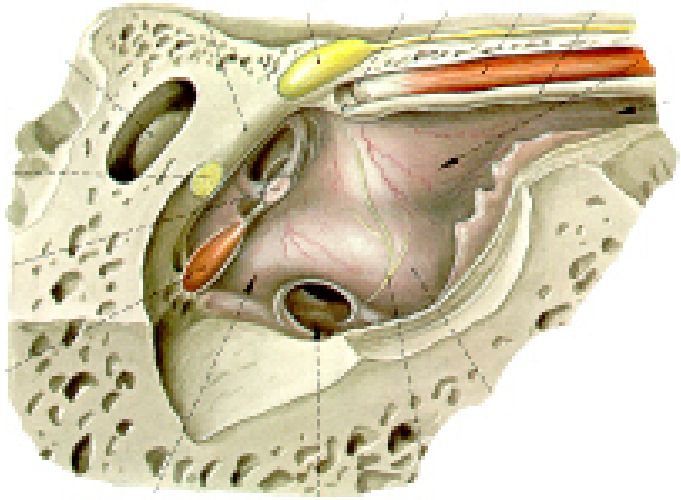

FACIAL PARALYSIS

sagging face
loss of naso-labial fold,
inability close eye



FACIAL NERVE (CRANIAL NERVE VII) - MANY BRANCHES INSIDE TEMPORAL BONE

VII - leaves post cranial fossa via Internal Auditory Meatus

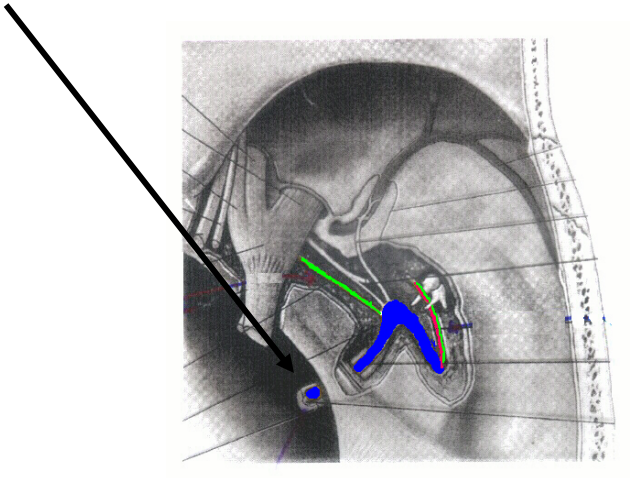

VII - EXITS SKULL VIA STYLOMASTOID FORAMEN

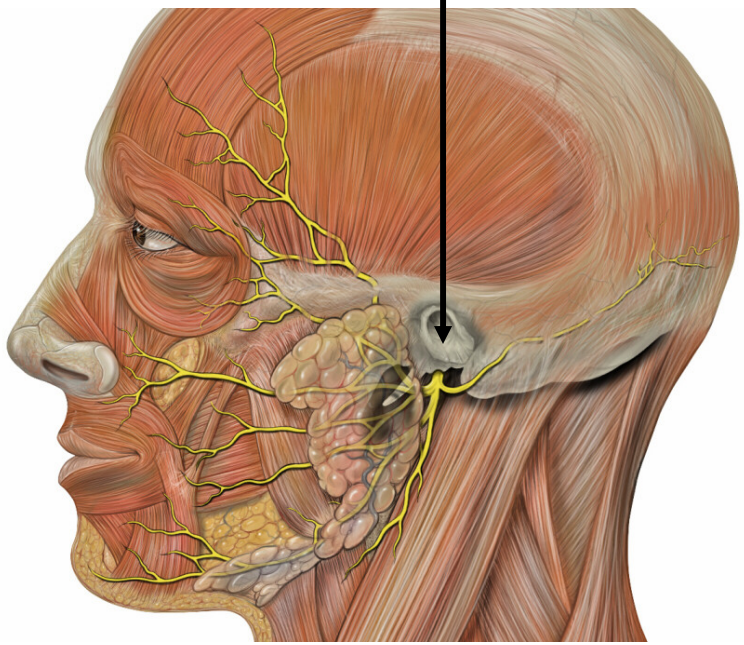

Branches arise in petrous temporal bone:

1) **Parasympathetics** - to Pterygopalatine ganglion - **Lacrimal gland, Mucous glands nose palat**e
2) **Taste fibers to ant. 2/3 tongue Chorda tympani** - also contains parasymp. **Submand., Sub.ling saliv. glands**

branches only to Muscles Facial Expression, Neck muscles

SYMPTOMS OF DAMAGE TO FACIAL NERVE DEPEND UPON LOCATION

Int. aud. meatus

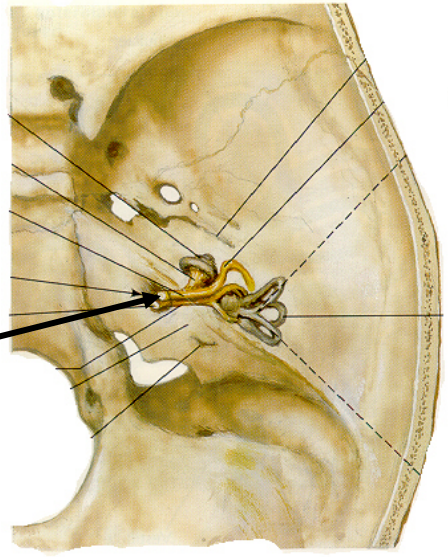

VII - FACIAL AND
VIII - VESTIBULO-COCHLEAR

ACOUSTIC NEUROMA (NEURINOMA)- tumor at INTERNAL AUDITORY MEATUS - BLOCK VII AND VIII

VIII - auditory/vestibular deficits

VII - Bell's Palsy - all FACIAL NERVE SYMPTOMS - facial paralysis, loss of taste, hyperacousia, decrease in secretion of lacrimal and salivary glands

Stylo-mastoid foramen or in Parotid Gland

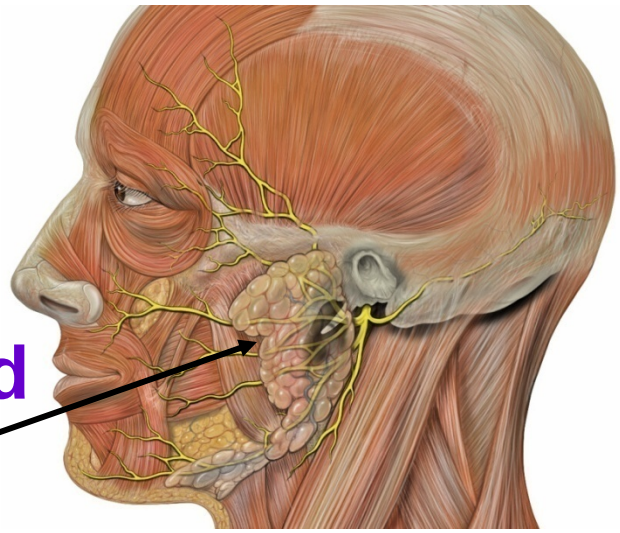

VII - ONLY

VII - ONLY facial paralysis; NO loss of taste, NO hyperacousia, NO decrease in secretion of lacrimal and salivary glands

NO auditory/vestibular deficits VIII NOT AFFECTED

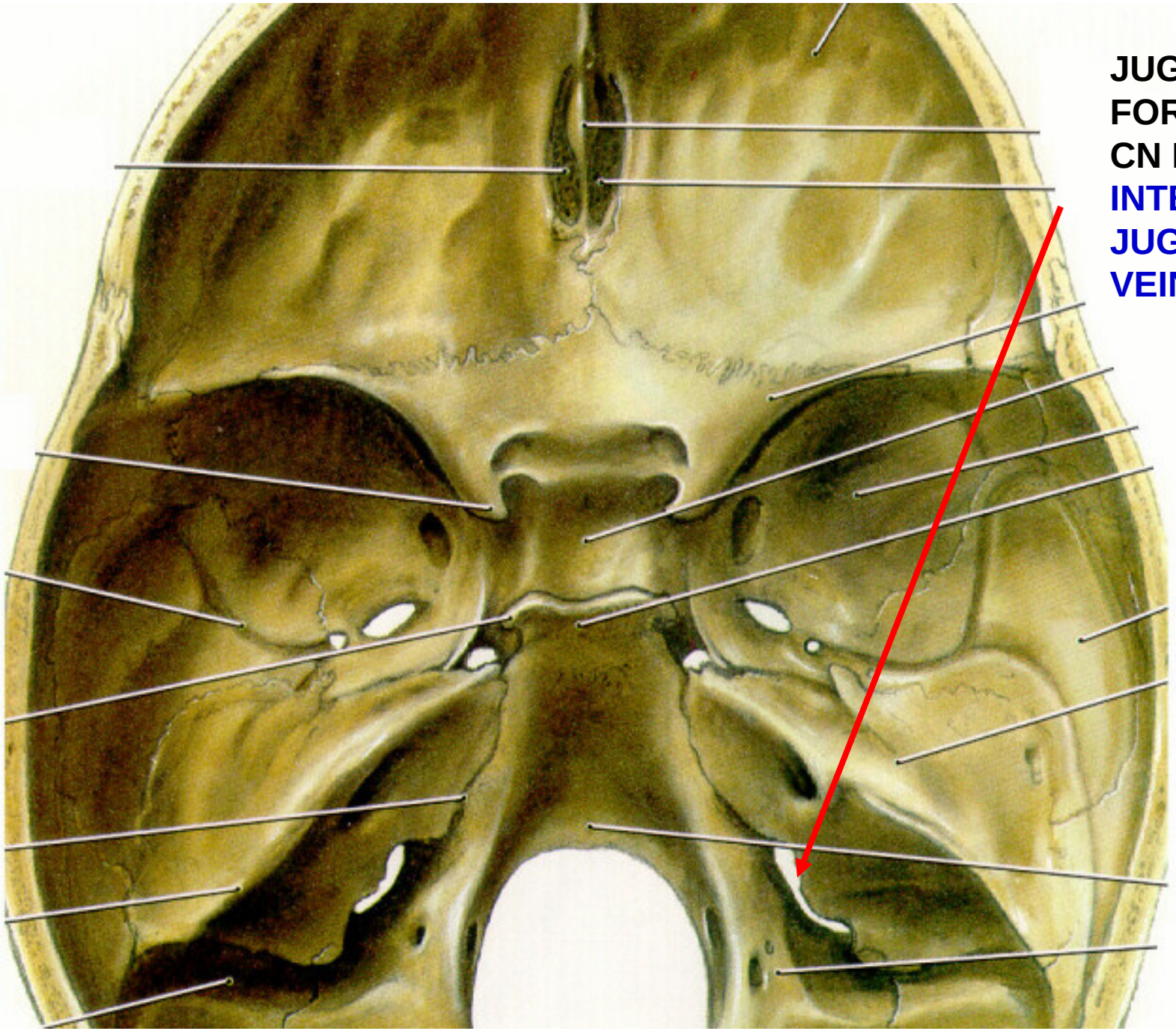

JUGULAR FORAMEN – CN IX, X, XI, INTERNAL JUGULAR VEIN

IX - GLOSSOPHARYNGEAL - TONGUE AND PHARYNX

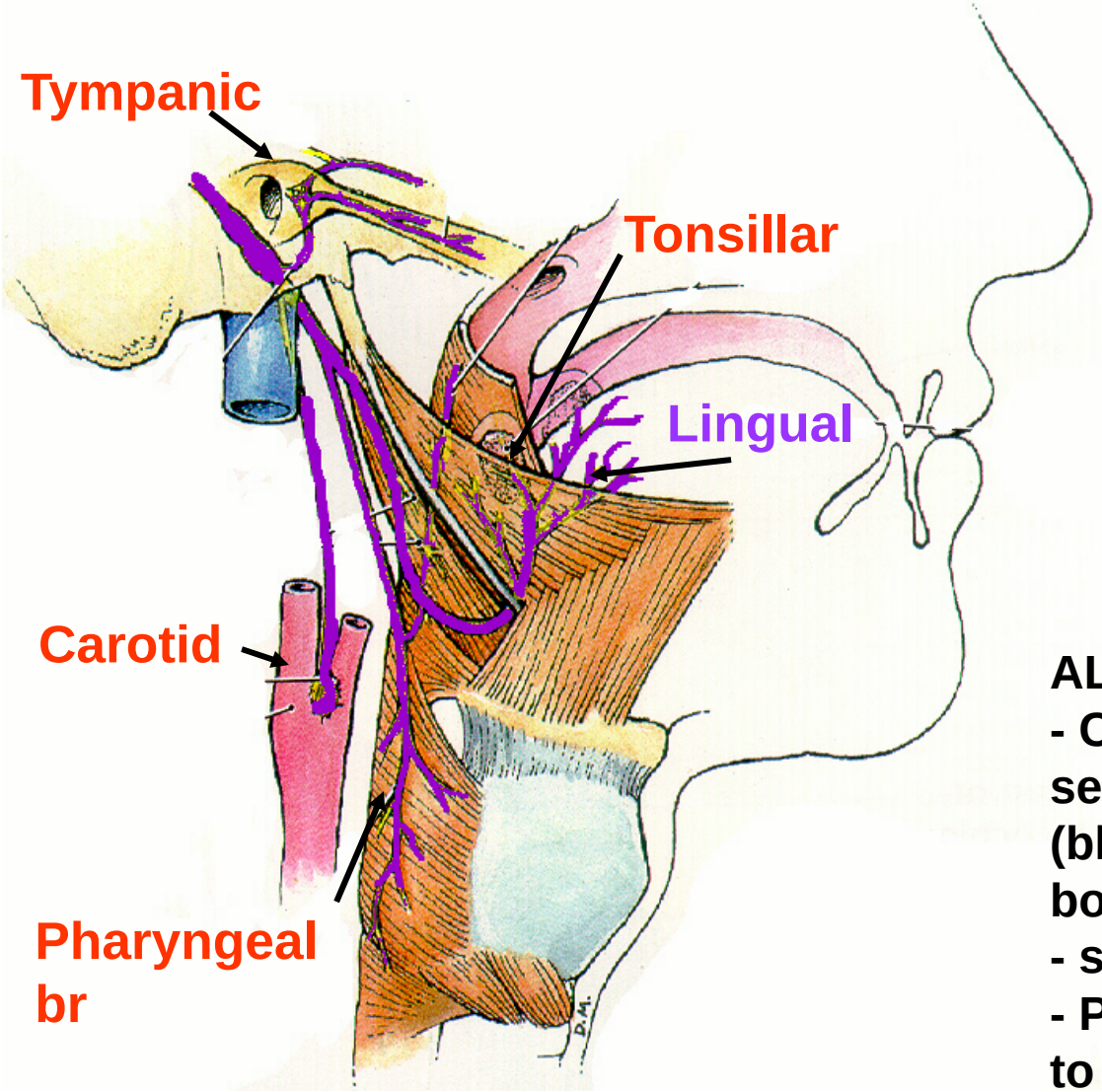

PHARYNX -
- GAG REFLEX (IX IN, X OUT) - IX is SENSORY touch to pharynx
- motor to stylopharyngeus

TONGUE -
- Taste and Touch to posterior 1/3 of tongue

ALSO
- CAROTID BRANCHES - sensory to carotid sinus (blood pressure) and carotid body (chemoreception)
- sensory to MIDDLE EAR
- PARASYMPATHETICS - to Parotid Salivary gland

STRUCTURES DERIVED FROM BRANCHIAL ARCHES

ARCH/NERVE	SKELETAL	LIGAMENTS	MUSCLES
First (V)	1) Malleus 2) Incus	1) Ant. ligament of malleus 2) Spheno-mandibular ligament	1) Muscles of Mastication 2) Tensor tympani 3) Tensor palati 4) Mylohyoid 5) Ant. belly of Digastric
Second (VII)	1) Stapes 2) Styloid process 3) Hyoid bone - lesser horn, upper half of body	Stylohyoid ligament	1) Muscles of Facial Expression 2) Stapedius 3) Stylohyoid 4) Post. belly of Digastric
Third (IX)	Hyoid bone - greater horn, lower half of body	----------	Stylopharyngeus
Fourth (X)	Cartilages of Larynx	----------	1) All muscles of Larynx 2) All muscles of Pharynx (except Stylopharyngeus) 3) All muscles of Soft Palate (except Tensor palati)
Sixth (XI)	----------	----------	1) Sternocleidomastoid 2) Trapezius

X- GAG REFLEX - is motor to all muscles of Pharynx (except Stylopharyngeus

MUSCLES OF LARYNX

CHANGE PITCH OF SOUND

Cricothyroid muscle - **raises pitch** TENSES

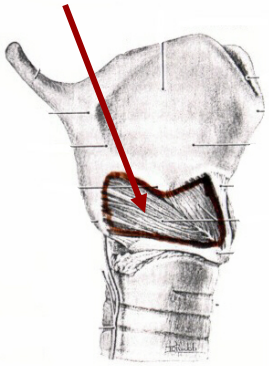

Thyroarytenoid muscle - **lowers pitch** RELAXES

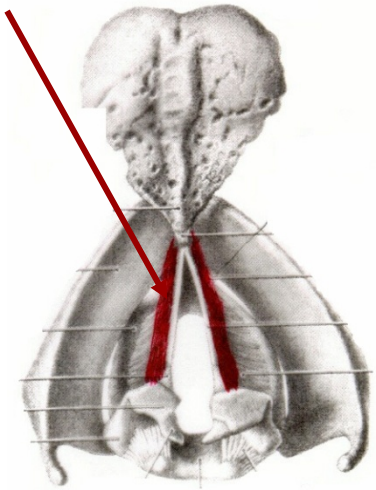

VOCAL LIGAMENTS

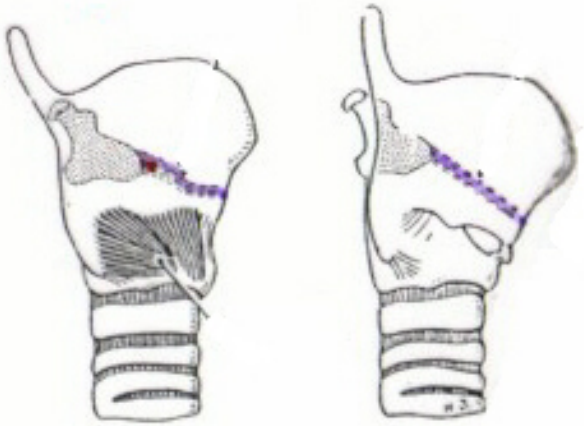

OPEN/CLOSE LARYNX (RIMA GLOTTIDIS)

Arytenoid and **Lateral Cricoarytenoid** - Close Rima Glottidis

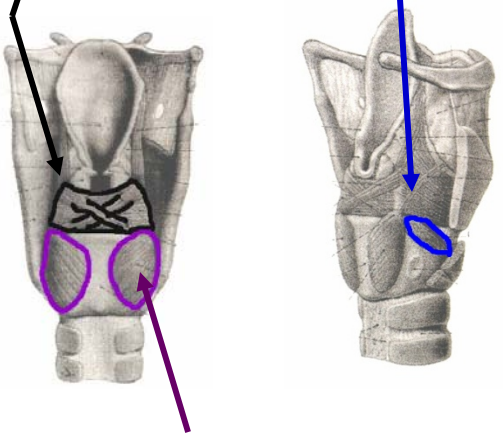

Posterior Cricoarytenoid - Opens Rima Glottidis

ALL MUSCLES INNERVATED BY VAGUS NERVE (X)

VAGUS (X) - ALL NERVES OF LARYNX

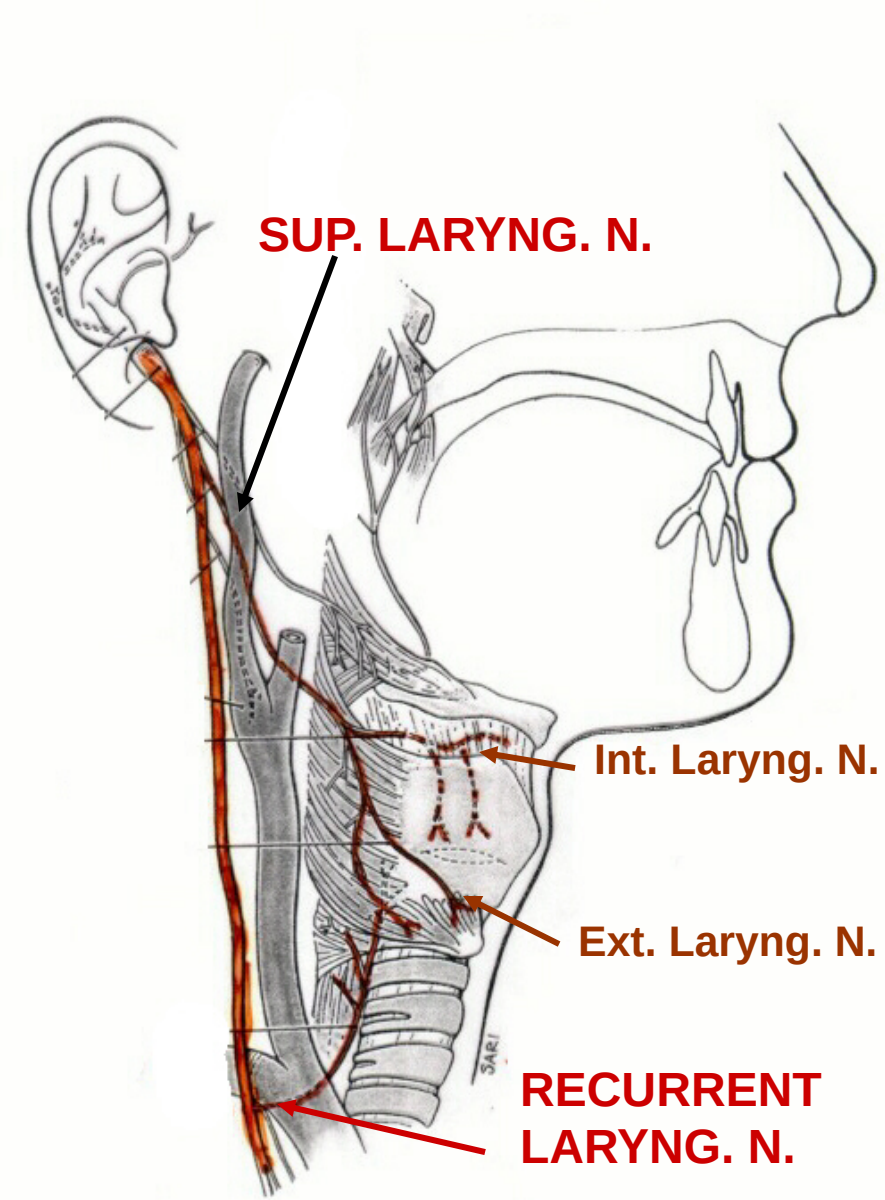

A. Superior Laryngeal N.
divides to -
1. Internal Laryngeal N.
Sensory to Larynx
Above True Vocal Folds
2. External Laryngeal N.
Motor to Cricothyroid

B. Recurrent Laryngeal N. -
(Inferior Laryngeal Branch)
- Sensory to Larynx
Below True Vocal Folds
- motor to all other
Muscles of Larynx

CLINICAL QUESTION -
Damage to recurrent laryngeal nerveduring thyroid surgery; also repair cervical intervertebral discs; patient has hoarse voice; damage all muscles except Cricothyroid

X- ALL MUSCLES OF PHARYNX EXCEPT STYLOPHARYNGEUS

Superior Const.

Middle Const.

Inferior Const.

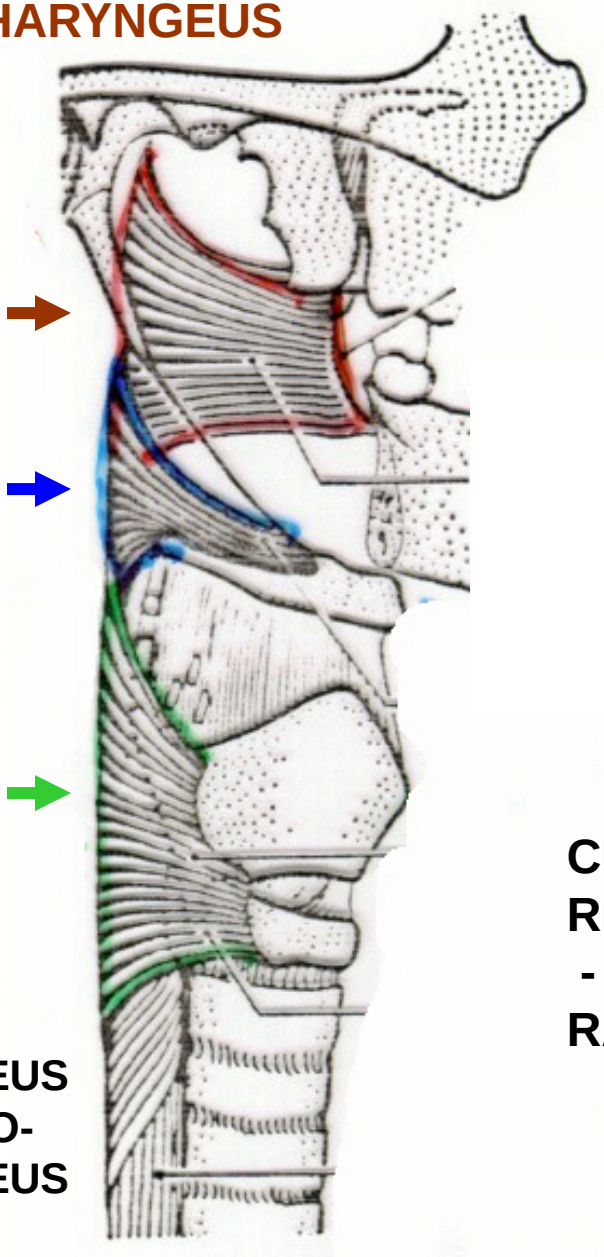

ALSO - PALATO-PHARYNGEUS - SALPINGO-PHARYNGEUS

X- ALL MUSCLES OF PALATE EXCEPT TENSOR PALATI

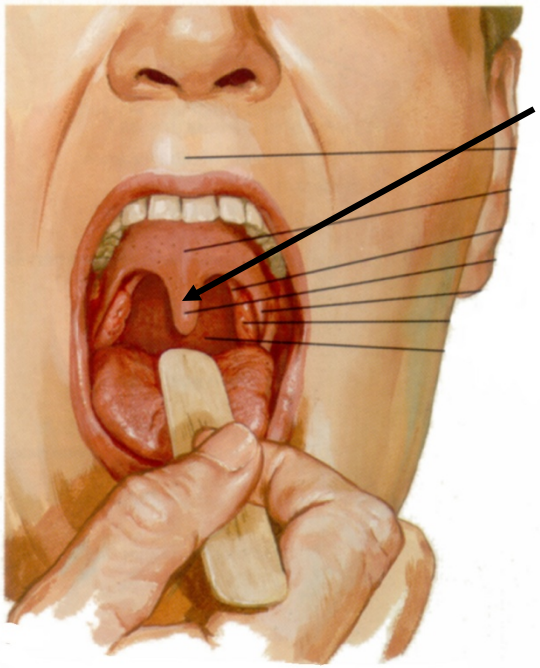

MUSCULUS UVULI - elevates uvula

LEVATOR PALATI -lifts palate

also PALATO-GLOSSUS - lowers palate

CLINICAL - MOTOR PART OF GAG REFLEX - pharyngeal constrictors - TEST MUSCLES OF PALATE – RAISE UVULA WHEN SAY AAAH!

XI - ACCESSORY NERVE

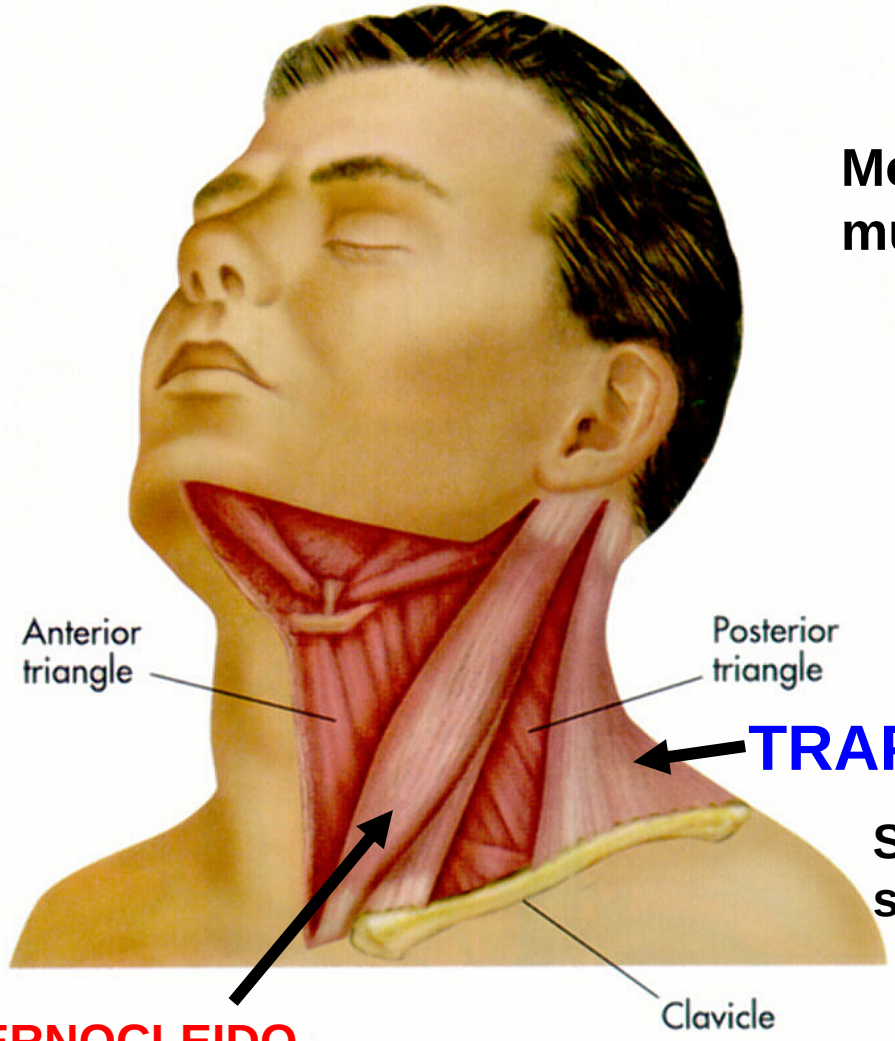

Motor to two muscles

TRAPEZIUS

Shrug shoulders

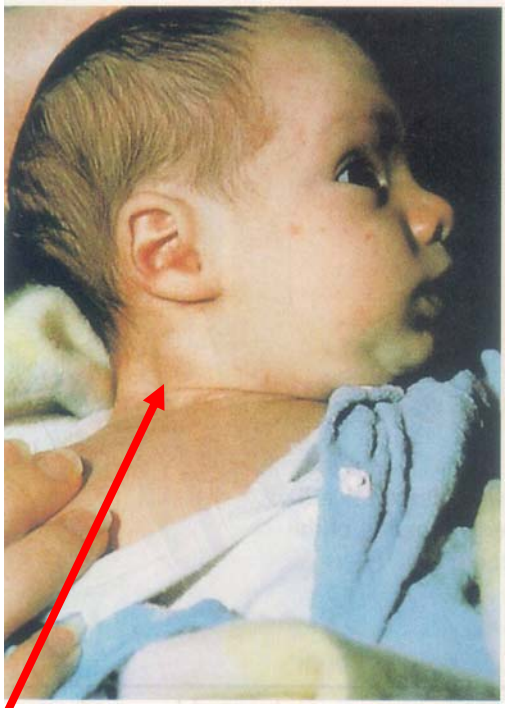

STERNOCLEIDO-MASTOID

Turn head

CLINICAL TEST TRAPEZIUS - shrug shoulders

CLINICAL: TORTICOLLIS – Contracture of Sternocleidomastoid; Face turned to opposite side

HYPOGLOSSAL NERVE (XII) - ALL MUSCLES OF TONGUE - GSE MOTOR

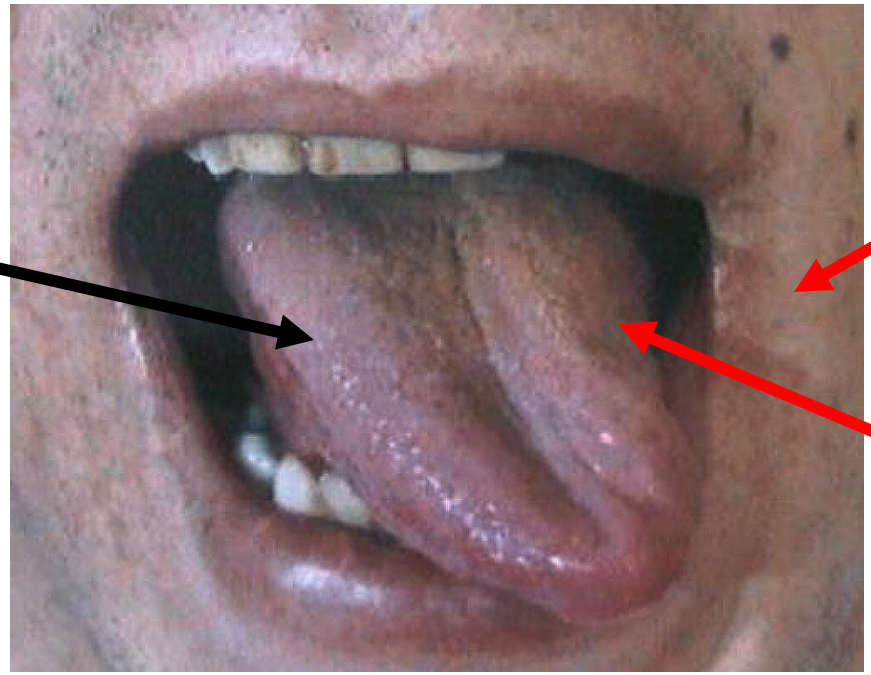

PROTRUDED TONGUE DEVIATES TOWARD SIDE OF LESION - due to unopposed action of the Genioglossus muscle which protrudes tongue (Lower Motor Neuron Lesion).

SENSORY INNERVATION OF TONGUE

NOTE:

PHARYNGEAL PART- POST 1/3 and ANT. TO EPIGLOTTIS

ORAL PART - ANT 2/3

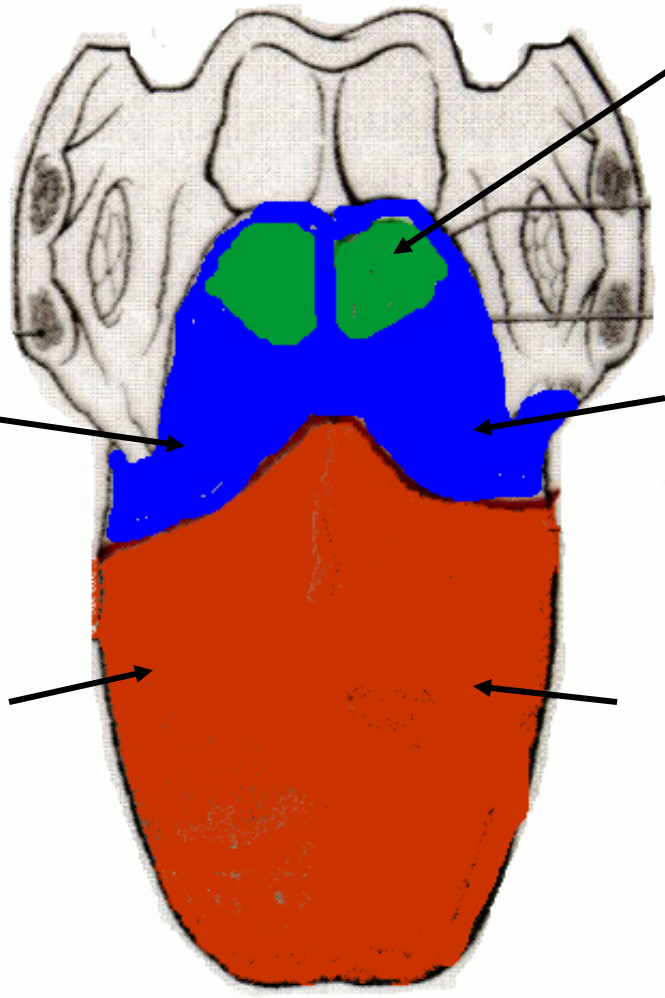

ANT. TO EPIGLOTTIS -
1) X- VAGUS
TOUCH AND TASTE

POST. 1/3 OF TONGUE
1) IX - GLOSSO-PHARYNGEAL TOUCH AND TASTE

ANT. 2/3 OF TONGUE
1) V3 - LINGUAL N. TOUCH
2) VII - CHORDA TYMPANI - TASTE

MOTOR - ALL MUSCLES INNERVATED BY XII HYPOGLOSSAL (GSE) –
PALATOGLOSSUS IS MUSCLE OF PALATE INNERVATED BY X (VAGUS)

GOOD LUCK!