

**LIST OF STRUCTURES TO BE IDENTIFIED IN LAB:
UPPER EXTREMITY REVIEW 2016**

BONES

Ribs, sternum, clavicle

Humerus: Head, greater tubercle, lesser tubercle, intertubercular sulcus, surgical neck, anatomical neck, **deltoid tuberosity**, medial epicondyle, medial supracondylar ridge, lateral epicondyle, lateral supracondylar ridge, radial groove, capitulum, trochlea, olecranon fossa

Radius: Head, neck, radial tuberosity, ulnar notch, styloid process, interosseous border

Ulna: Olecranon, trochlear notch, radial notch, head, interosseous border

Scapula: Acromion, spine, supraglenoid tubercle, infraglenoid tubercle, coracoid process, suprascapular notch, supraspinous fossa, infraspinous fossa, subscapular fossa, glenoid fossa, inferior angle

Wrist: Proximal row (lateral to medial): Scaphoid, lunate, triquetrum, pisiform

Distal row (lateral to medial): Trapezium, trapezoid, capitate, hamate

Hand: Metacarpals and phalanges (proximal, middle, and distal)

PECTORAL REGION

Muscles: Pectoralis major (clavicular and sternal heads), pectoralis minor, **subclavius**, **serratus anterior**

Nerves: Medial and lateral pectoral, **intercostobrachial**, (T2 - pain armpit from coronary)

Arteries: **Thoracoacromial** (medial to Pec Minor with Lateral Pectoral Nerve), **Lateral Thoracic** (lateral to Pec Minor with Medial Pectoral Nerve)

Veins: Cephalic vein in deltopectoral triangle (pierces clavipectoral fascia)

Test Pec major

Sternocostal - patient abducts arm to 60 degrees - test adduction resisted

Clavicular - patient abducts to 90 degrees - test anterior movement (flexion?)

Breast lymphatic drainage

Lateral quadrant - anterior (pectoral) nodes to central nodes to apical nodes

Medial quadrant - parasternal nodes

Lower quadrants - abdominal nodes

AXILLARY REGION/BRACHIAL PLEXUS

Muscles from axillary view: Latissimus dorsi, teres major, subscapularis, coracobrachialis, biceps brachii,

Nerves: Anterior rami of spinal nerves C5 to C8, and T1

Divisions, Cords

Trunks: Upper, middle, lower trunks and their anterior and posterior divisions

Medial cord: Medial part of median nerve, ulnar, medial cutaneous nerve of forearm, medial cutaneous nerve of arm (may not be present), medial pectoral

Lateral cord: Lateral part of median, musculocutaneous, **lateral pectoral**

Posterior cord: Radial, axillary, upper and lower subscapular, thoracodorsal

Other branches: Long thoracic, suprascapular

Arteries:

Subclavian, axillary (becomes Brachial at lat. border Teres Major), superior thoracic, thoraco-acromial, lateral thoracic, subscapular, circumflex scapular, thoracodorsal, anterior circumflex, posterior circumflex,

Veins: Axillary

AXILLARY ARTERY PART 1 - med to pec minor - Superior Thoracic artery
PART 2 - post to pec minor - Thoracoacromial artery, Lateral Thoracic artery
PART 3 - lat to pec minor - Ant + Post Humeral circumflex (with Axillary n.); Subscapular artery
(Circumflex scapular, Thoraco dorsal)

ANTERIOR ARM (FLEXORS) AND CUBITAL FOSSA

Muscles: **Coracobrachialis**, biceps brachii (long and short heads), brachialis, pronator teres, brachioradialis, bicipital aponeurosis

Nerves:

Musculocutaneous, lateral cutaneous nerve of forearm (continuation of musculocutaneous in forearm), ulnar, median

Arteries:

Brachial, **superior ulnar collateral, inferior ulnar collateral,**

Ligament: Transverse humeral

TRANSVERSE HUMERAL LIGAMENT - HOLDS IN TENDON OF BICEPS in BICIPITAL GROOVE BETWEEN GREATER AND LESSER TUBERCLES

SUPERIOR ULNAR COLLATERAL ARTERY PASSES WITH ULNAR NERVE

from Brachial

Superior Ulnar Collateral - Posterior ulnar recurrent

Inferior Ulnar Collateral - Anterior ulnar recurrent

from Profunda

Radial Collateral - Radial Recurrent

(Middle Collateral) - Interosseus Recurrent (from Post. interosseus)

POSTERIOR ARM (EXTENSORS)

Muscles: Triceps brachii (long, lateral, and **medial** heads), **anconeus**

(ANCONEUS - LATERAL TO OLECRANON PROCESS OF ULNA)

Nerves: Radial

Arteries: Profunda (deep) brachial

LONG HEAD IS MEDIAL PART - POSTERIOR TO TERES MAJOR, ANTERIOR TO TERES MINOR; MEDIAL HEAD IS PART BELOW SPIRAL GROOVE

SCAPULAR REGION

Muscles:

Deltoid, teres major, teres minor, supraspinatus, infraspinatus, long head of triceps brachii,

Nerves:

Axillary, suprascapular

Arteries:

Posterior circumflex humeral, suprascapular, circumflex scapular

Ligament: Suprascapular

SUPRASCAPULAR ARTERY OVER NERVE UNDER

ANTERIOR FOREARM (FLEXORS)

Fascia: Interosseous membrane

Muscles: Flexor carpi ulnaris, flexor carpi radialis, palmaris longus, flexor digitorum superficialis, flexor digitorum profundus, flexor pollicis longus, pronator teres, brachioradialis, pronator quadratus, supinator (anterior view)

Nerves: Median, anterior interosseous branch of median, superficial branch of radial, deep branch of radial through supinator muscle, ulnar, **dorsal branch of ulnar (sensory)**

Arteries: Brachial, radial, ulnar, common interosseous (branch of ulnar), posterior and anterior interosseous (branch of common interosseous), radial recurrent

Veins: Basilic, cephalic, median cubital

PALM OF HAND

Fascia: Palmar aponeurosis, flexor retinaculum, fibrous digital sheaths, digital synovial sheaths

Muscles: Thenar muscles: Abductor pollicis brevis, flexor pollicis brevis, opponens pollicis

Hypothenar muscles: Abductor digiti minimi, flexor digiti minimi brevis, opponens digiti minimi

Deep muscles: Lumbricals, palmar interosseous, dorsal interosseous, adductor pollicis (oblique and transverse heads)

Nerves: Median, recurrent branch of median, digital branches of median, deep branch of ulnar, superficial branch of ulnar, digital branches of ulnar

Arteries: Ulnar, superficial branch of ulnar, deep branch of ulnar, superficial palmar arch, superficial branch of radial (if present), deep palmar arch, metatarsal

POSTERIOR FOREARM (EXTENSORS) AND DORSUM OF HAND

Fascia: Extensor retinaculum

Muscles: Superficial group : Brachioradialis, extensor carpi radialis longus, extensor carpi radialis brevis, extensor digitorum, extensor digiti minimi, extensor carpi ulnaris

Deep group : Abductor pollicis longus, extensor pollicis brevis, extensor pollicis longus, extensor indicis, supinator (posterior view)

Dorsum of hand: Dorsal interosseous muscles

Nerves:

Deep branch of radial

Artery:

Posterior interosseous

JOINTS OF UPPER LIMB

Acromioclavicular joint: Acromioclavicular ligaments, coracoclavicular ligament (two parts)

Glenohumeral joint: Glenoid labrum, glenohumeral ligaments,

Not associated with any joint: Coracoacromial ligament

Elbow joint: Ulnar collateral ligament, radial collateral ligament

Proximal radioulnar joint: Annular ligament

Dislocate AC joint - tear coracoclavicular ligament - Point of shoulder lower, clavicle sticks up

Tennis elbow - Lateral epicondyle

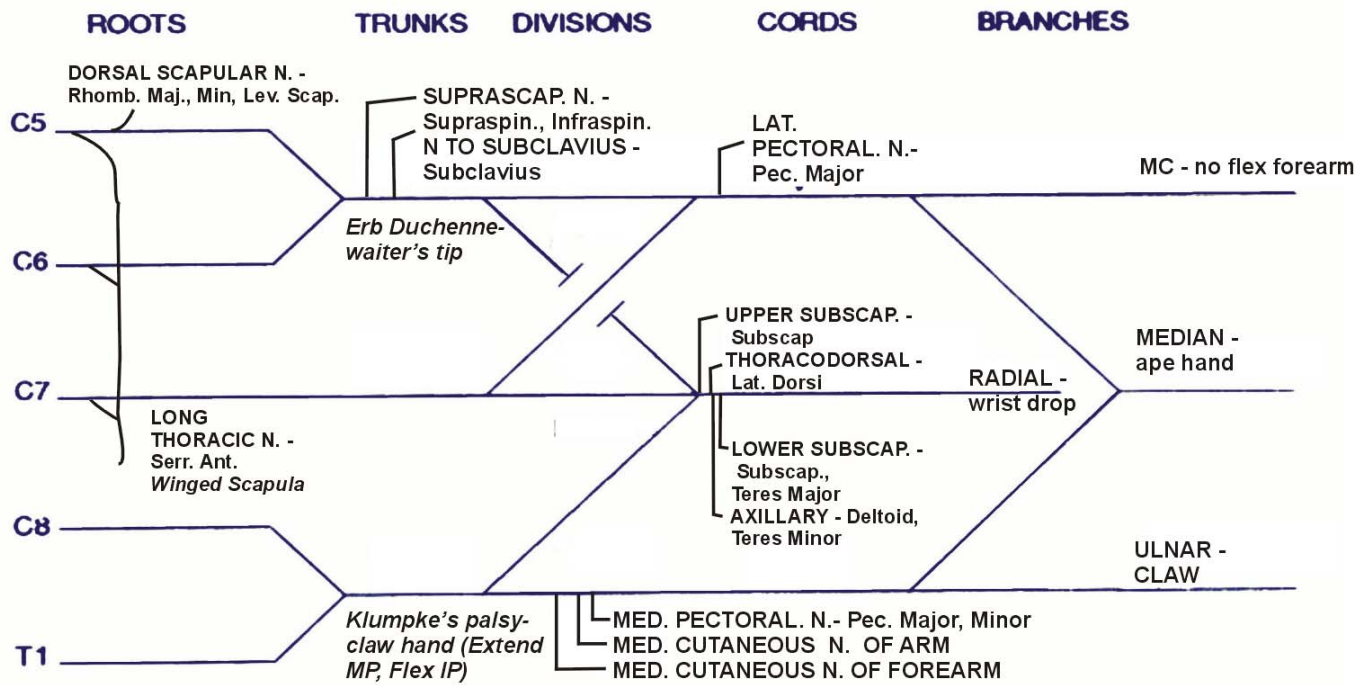
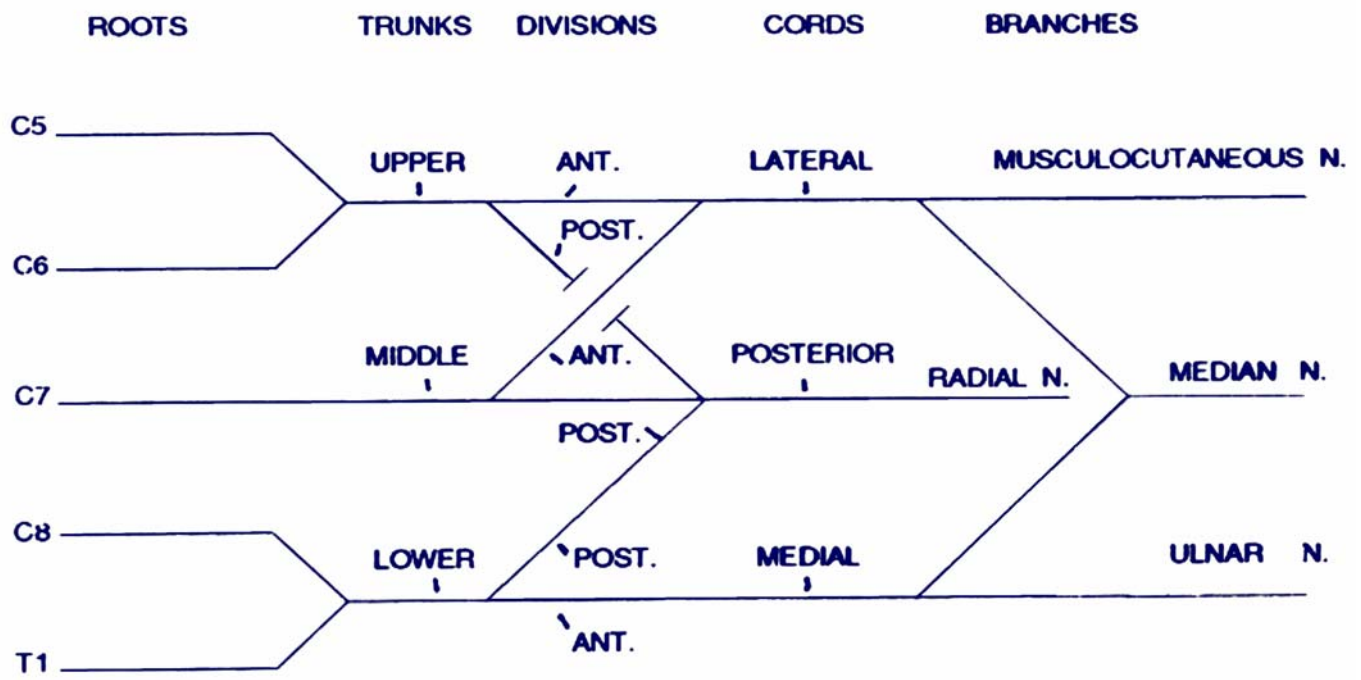
Tommy John surgery - ulnar collateral ligament

Mallet finger - jam phalanx against something - rupture extensor expansions (lateral slips) to distal interphalangeal joint - sign: distal IP joint flexed

Boutonniere deformity - jam phalanx against something or arthritis - lateral slips of extensor expansion separate - head of proximal phalanx through gap 'button hole' - - sign: PIP flexed, DIP hyperextended

TABLE OF NERVE INJURIES UPPER EXTREMITY

Nerve/Location	Cause	Symptoms
Long Thoracic - C567	Radical mastectomy, Knife wound upper (lateral) chest	Winged scapula - medial border scapula protrudes when extend arm against resistance No abduct past 120 degrees - rotate
Upper Trunk - Erb Duchenne - C56 - damage Musculocutaneous, Suprascapular nerves	Fall, separate head shoulder; Pull head at birth (breech delivery)	Waiter's tip position - Musculocutaneous - arm pronated (no biceps supinate); no flex forearm; no sens lat. forearm suprascapular - no abduct arm, arm medially rotate (no oppose subscapularis)
Lower Trunk - Klumpke's (C8)T1 - damage ulnar, median	Cervical rib; Fall grab object, (grab arm)	Claw hand - get ALL intrinsic hand muscles (lumbricals, interossei) - note: not get long flexors (C8) sensory - T1 - no sense medial arm, forearm
Axillary nerve	Shoulder dislocation, (also fracture surgical neck), damage in quadrangular space	No abduct arm past 15 degrees (supraspinatus 0-15); Sens. deficit - Upper lateral arm
Radial nerve	Fracture mid shaft of humerus; damage in spiral (radial) groove	Wrist drop - no extend wrist, no sensation dorsal hand (can extend forearm)
	Radial nerve - at plexus - poorly fitting crutches, Saturday night palsy (drape arm over chair)	Wrist drop + No extend forearm; no sensation dorsal hand
Median nerve	Compress in carpal tunnel - (progressive)	Ape hand - no oppose thumb, atrophy thenar eminence (not adductor); no sensation lateral 3.5 digits,
	Knife wound wrist, suicide	Above plus lose palmar sensory Branch
	higher up (Supracondylar fracture)	Above plus motor ant. forearm - no flex wrist, forearm in supination
Ulnar nerve	Damage at medial epicondyle	Ulnar 'Claw' hand - paralyze lumbricals to medial two digits + all interossei - extend mc, flex ic on medial two digits; no DAB or PAD digits; no sensation medial 1.5 digits dorsal and ventral (also medial palm, dorsum); + flex carpi ulnaris, flex, dig. prof.
	Damage at wrist	not affect Flexor carpi ulnaris, half of Flexor digitorum profundus



UPPER EXTREMITY - MUSCLE INNERVATION COMPARTMENTALIZED

RADIAL N.

EXTENSION
AT ELBOW

RADIAL N.

EXTENSION
AT WRIST,
FINGERS;
SUPINATION

MUSCULOCUTANEOUS N.

FLEXION
AT ELBOW

MEDIAN N. +
ULNAR N.
(1.5 MUSCLES)

FLEXION
AT WRIST,
FINGERS;
PRONATION

