

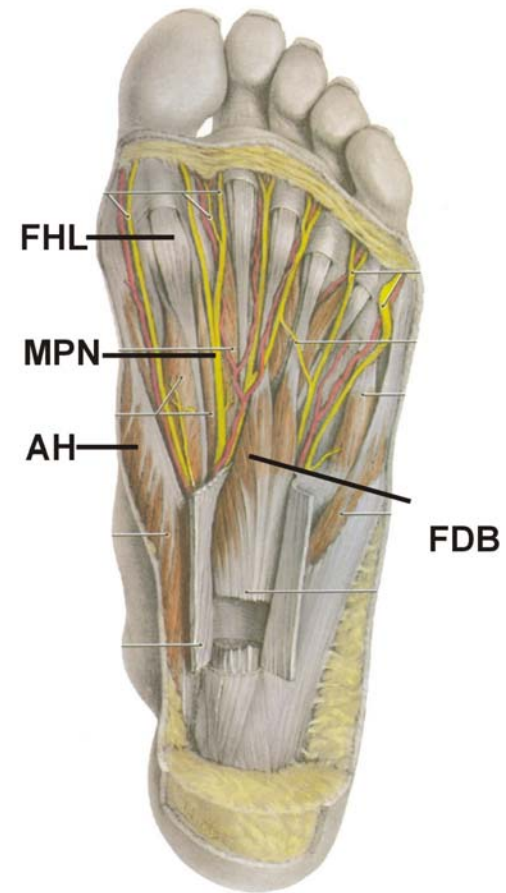
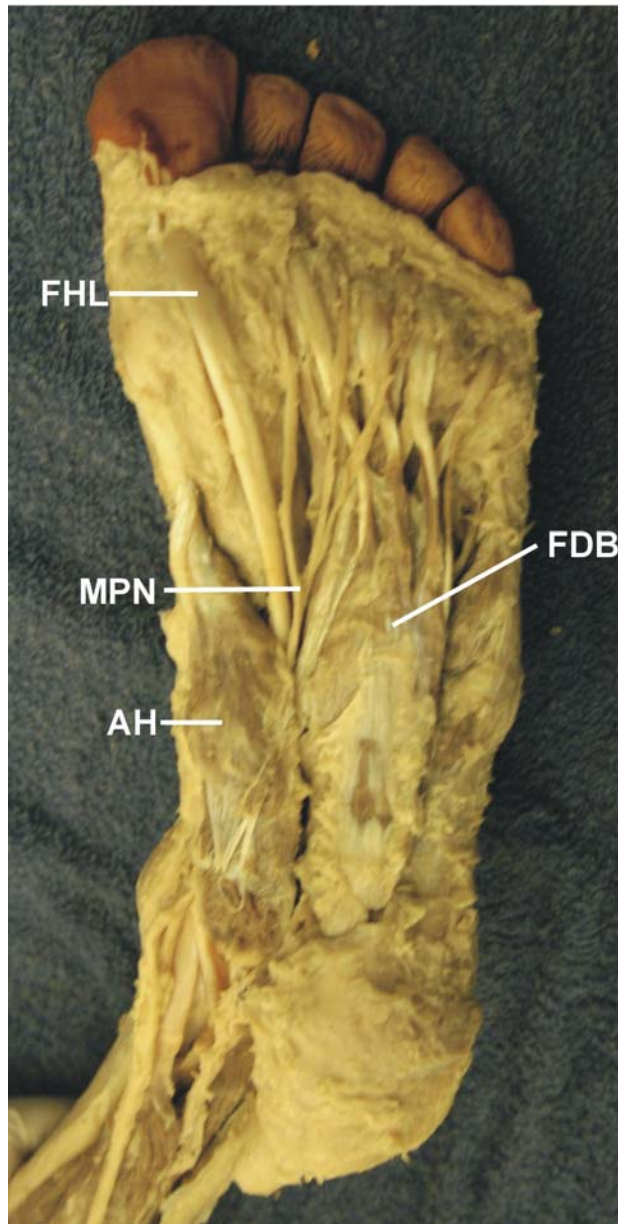
LOWER EXTREMITY PROSECTIONS 2019

- A. FEET PROSECTIONS**
- B. JOINTS PROSECTIONS**
- C. THIGH, LEG PROSECTIONS**

**A. FEET
PROSECTIONS**

SOLE OF FOOT: MUSCLE LAYER 1

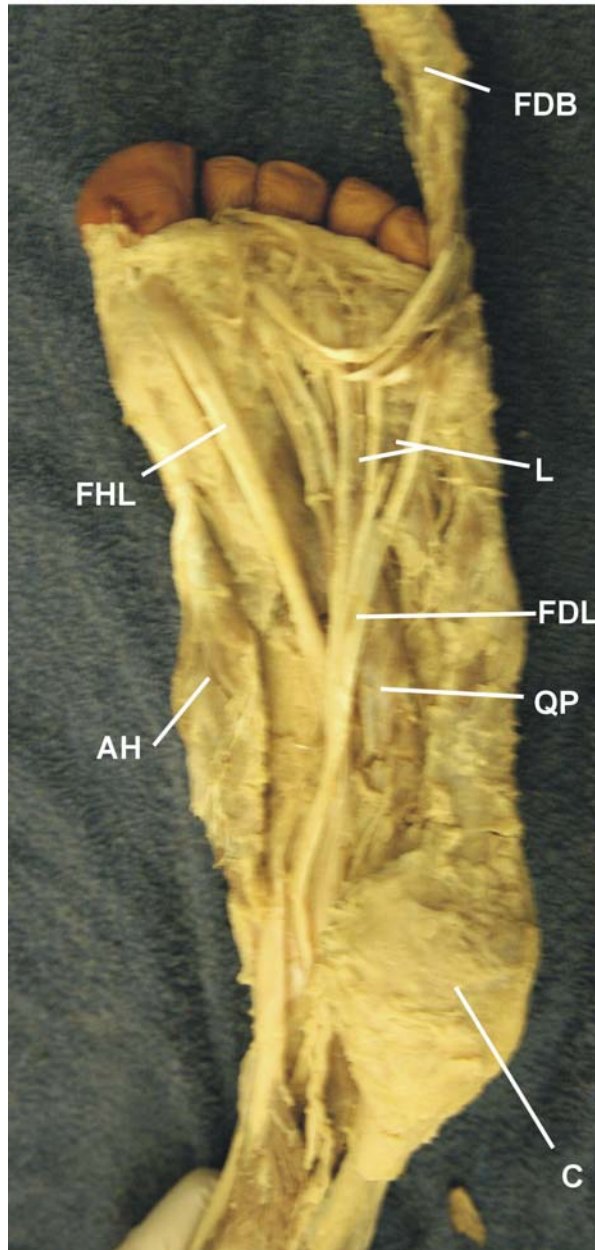
213



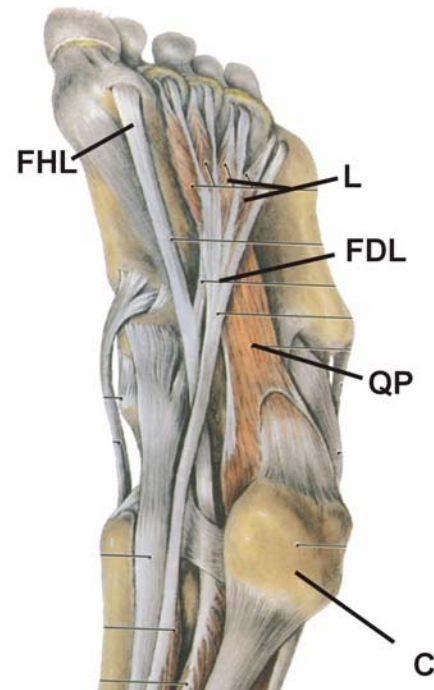
AH - ABDUCTOR HALLUCIS
FDB - FLEXOR DIGITORUM BREVIS
FHL - FLEXOR HALLUCIS LONGUS
MPN - MEDIAL PLANTAR NERVE

SOLE OF FOOT: MUSCLE LAYER 2

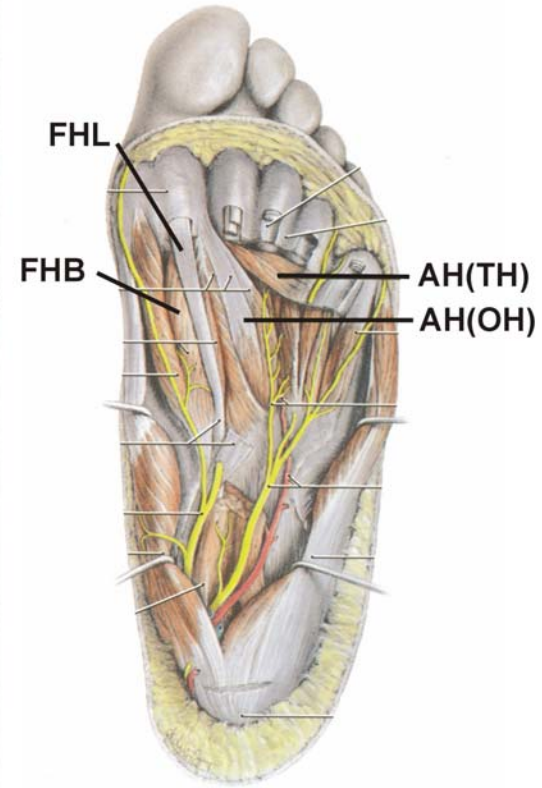
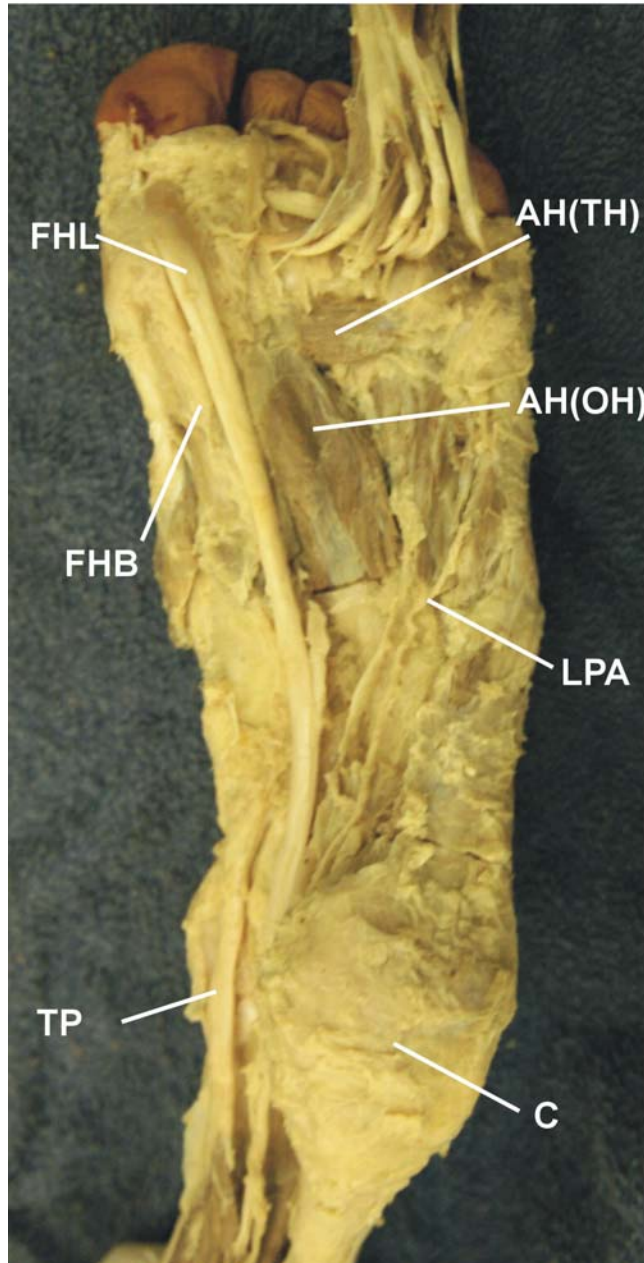
213



AH - ABDUCTOR HALLUCIS
C - CALCANEUS
FDB - FLEXOR DIGITORUM BREVIS
FDL - FLEXOR DIGITORUM LONGUS
FHL - FLEXOR HALLUCIS LONGUS
L - LUMBRICALS
QP - QUADRATUS PLANTAE

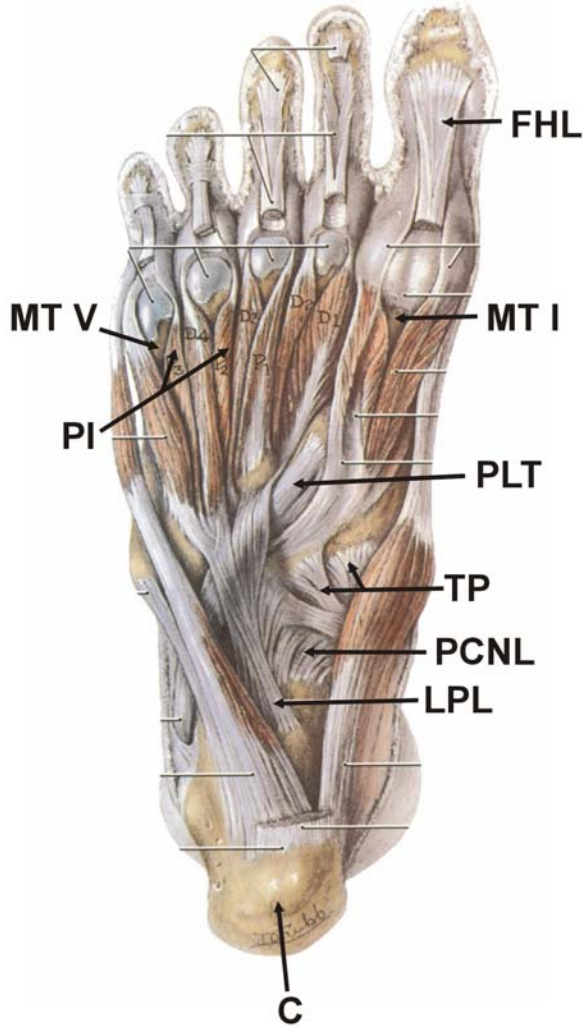
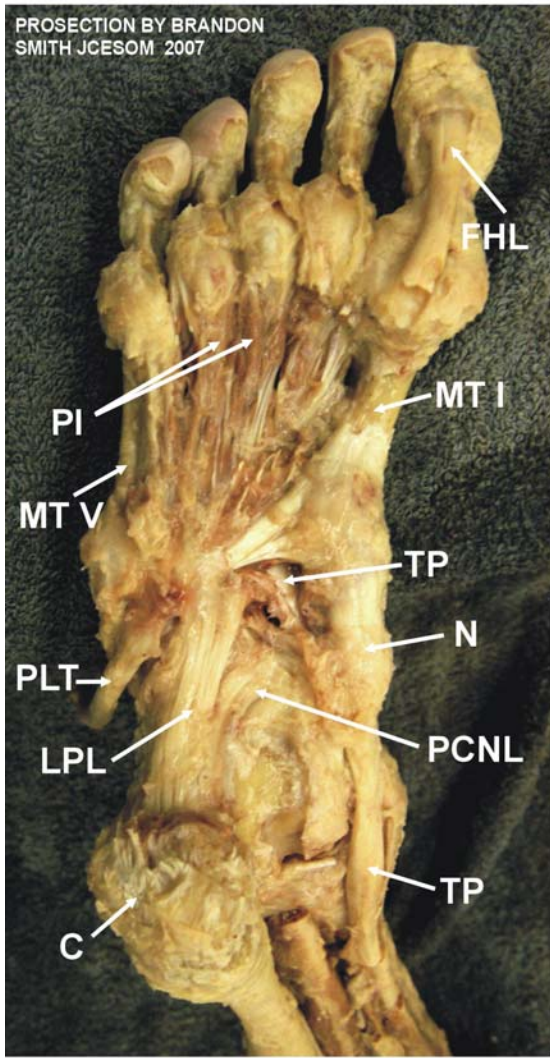


SOLE OF FOOT: MUSCLE LAYER 3



- AH(TH) - ADDUCTOR HALLUCIS (TRANSVERSE HEAD)
- AH(OH) - ADDUCTOR HALLUCIS (OBLIQUE HEAD)
- FHB - FLEXOR HALLUCIS BREVIS
- FHL - FLEXOR HALLUCIS LONGUS
- TP - TIBIALIS POSTERIOR
- C - CALCANEUS
- LPA - LATERAL PLANTER ARTERY

DEEP FOOT: PERONEUS LONGUS TENDON

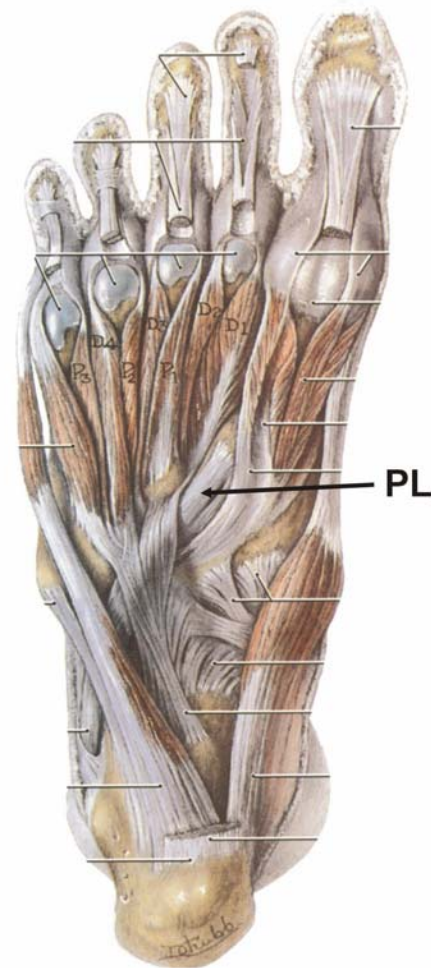
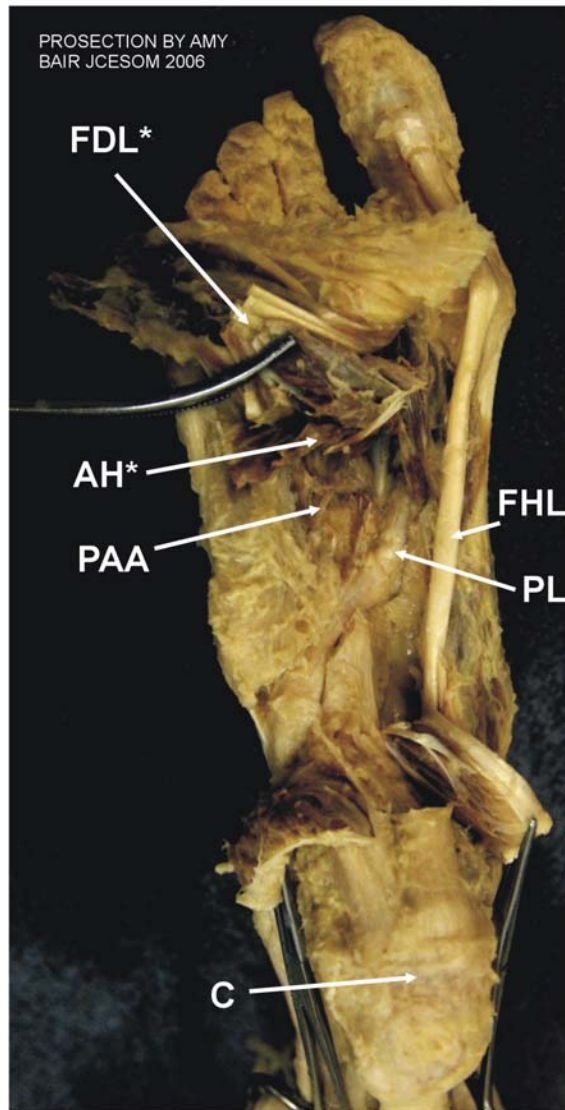


- MT I - 1st METATARSAL
- MT V - 5th METATARSAL
- C - CALCANEUS
- FHL - FLEXOR HALLUCIS LONGUS TENDON
- LPL - LONG PLANTAR LIGAMENT
- N - NAVICULAR BONE
- PLT - PERONEUS LONGUS TENDON
- PCNL - PLANTAR CALCANEONAVICULAR LIGAMENT
- NTPLT - PERONEUS LONGUS TENDON

- PI - PLANTAR INTEROSSEUS MM.
- TP - TIBIALIS POSTERIOR

DEEP FOOT: PERONEUS LONGUS TENDON

215

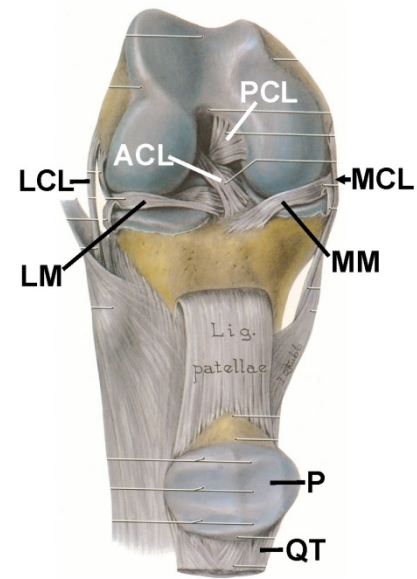
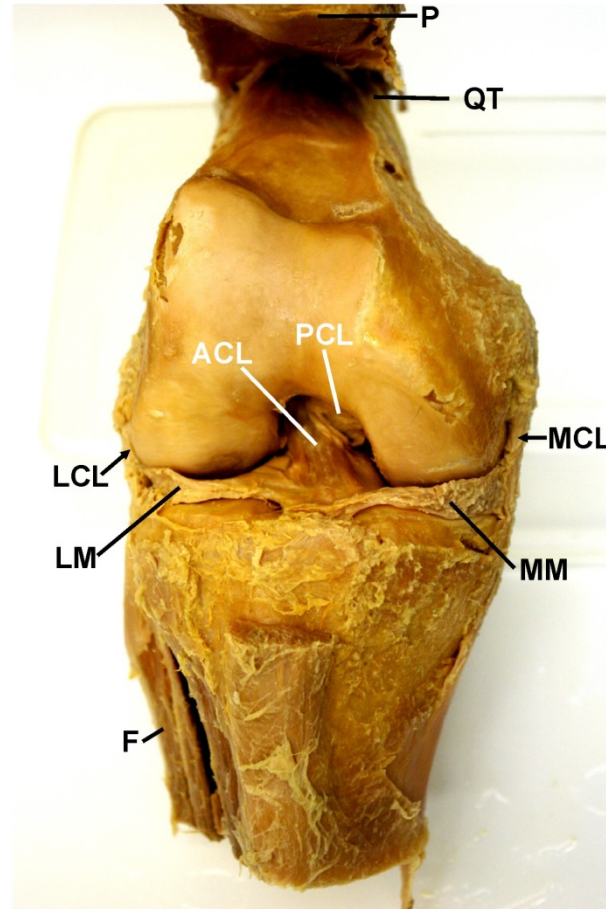


- FDL* - FLEXOR DIGITORUM LONGUS (REFLECTED)
- AH* - ADDUCTOR HALLICUS (REFLECTED)
- PAA - PLANTAR ARTERIAL ARCH
- PL - PERONEUS LONGUS TENDON
- C - CALCANEUS
- FHL - FLEXOR HALLUCIS LONGUS

B. JOINT PROSECTIONS

KNEE JOINT: ANTERIOR VIEW

216



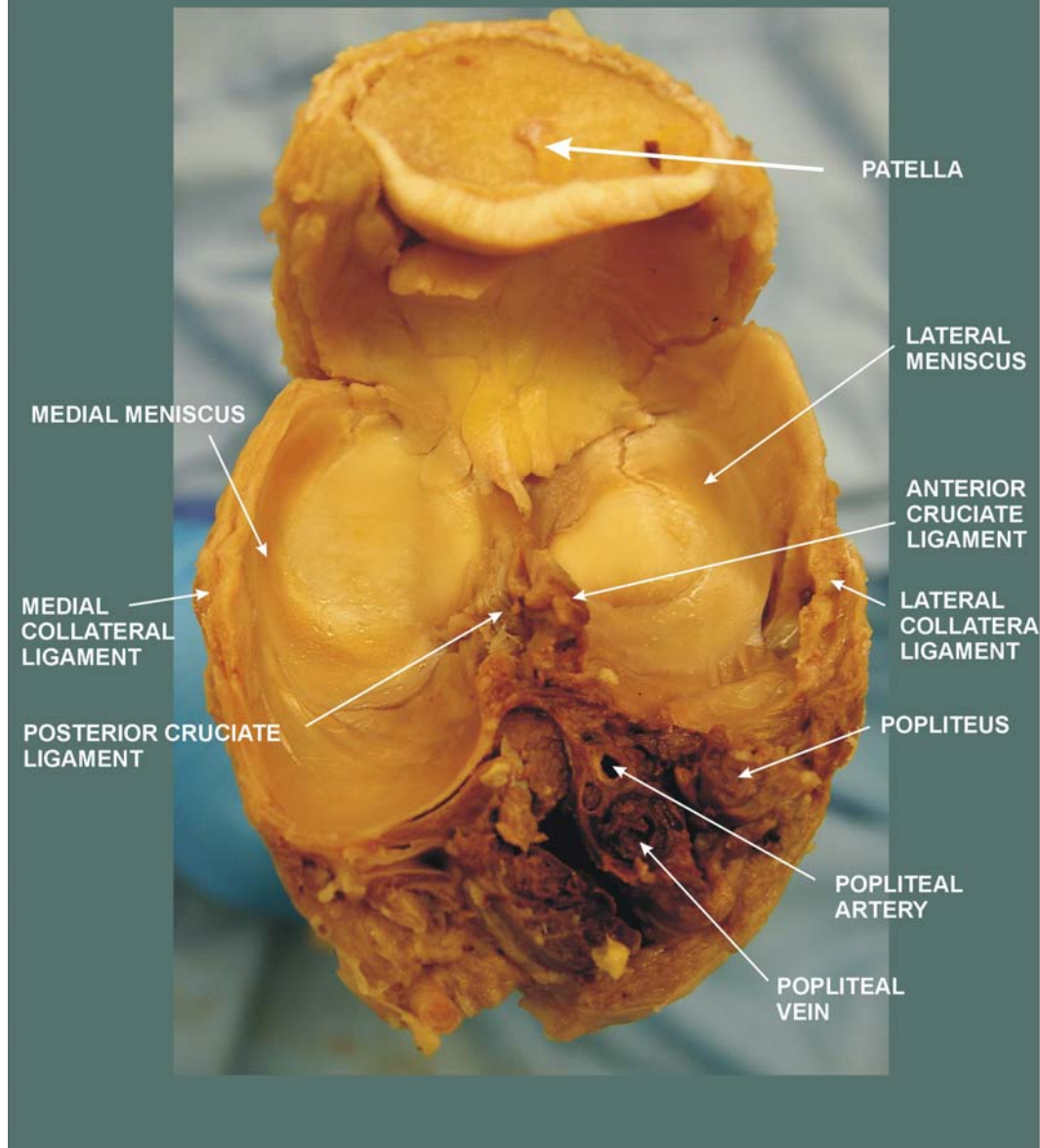
ACL - ANTERIOR CRUCIATE LIGAMENT
F - FIBULA
LCL - LATERAL (FIBULAR) COLLATERAL LIGAMENT
LM - LATERAL MENISCUS
MCL - MEDIAL (TIBIAL) COLLATERAL LIGAMENT
MM - MEDIAL MENISCUS
P - PATELLA
PCL - POSTERIOR CRUCIATE LIGAMENT
QT - QUADRICEPS TENDON

TERRIBLE TRIAD = ACL + MM + MCL

KNEE CARTILAGES FROM ABOVE

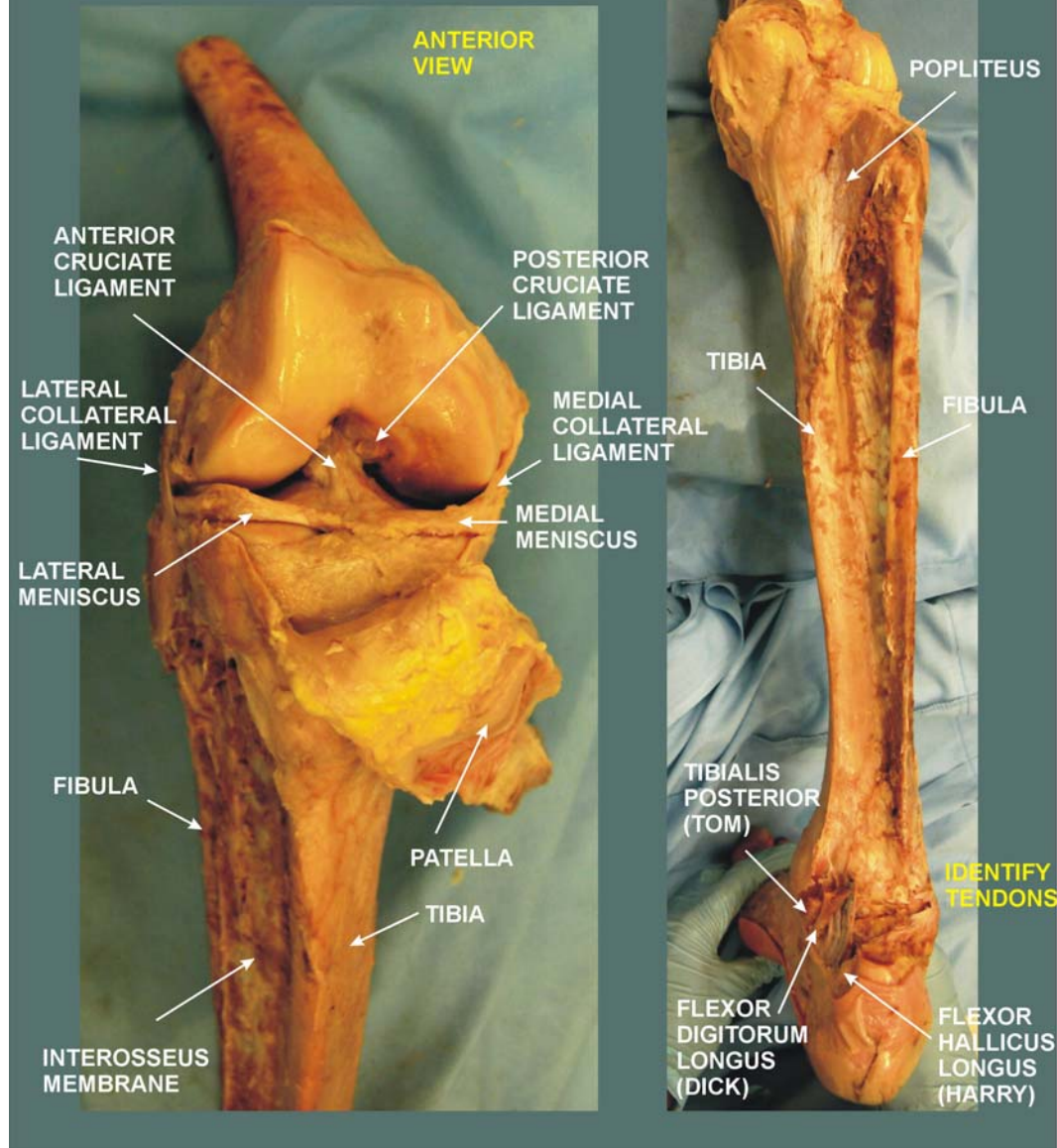
311

PROSECTON BY KARA CLOXTON,
AND JOSHUA HOUSER, JCESOM
SUMMER DISSECTION COURSE, 2009



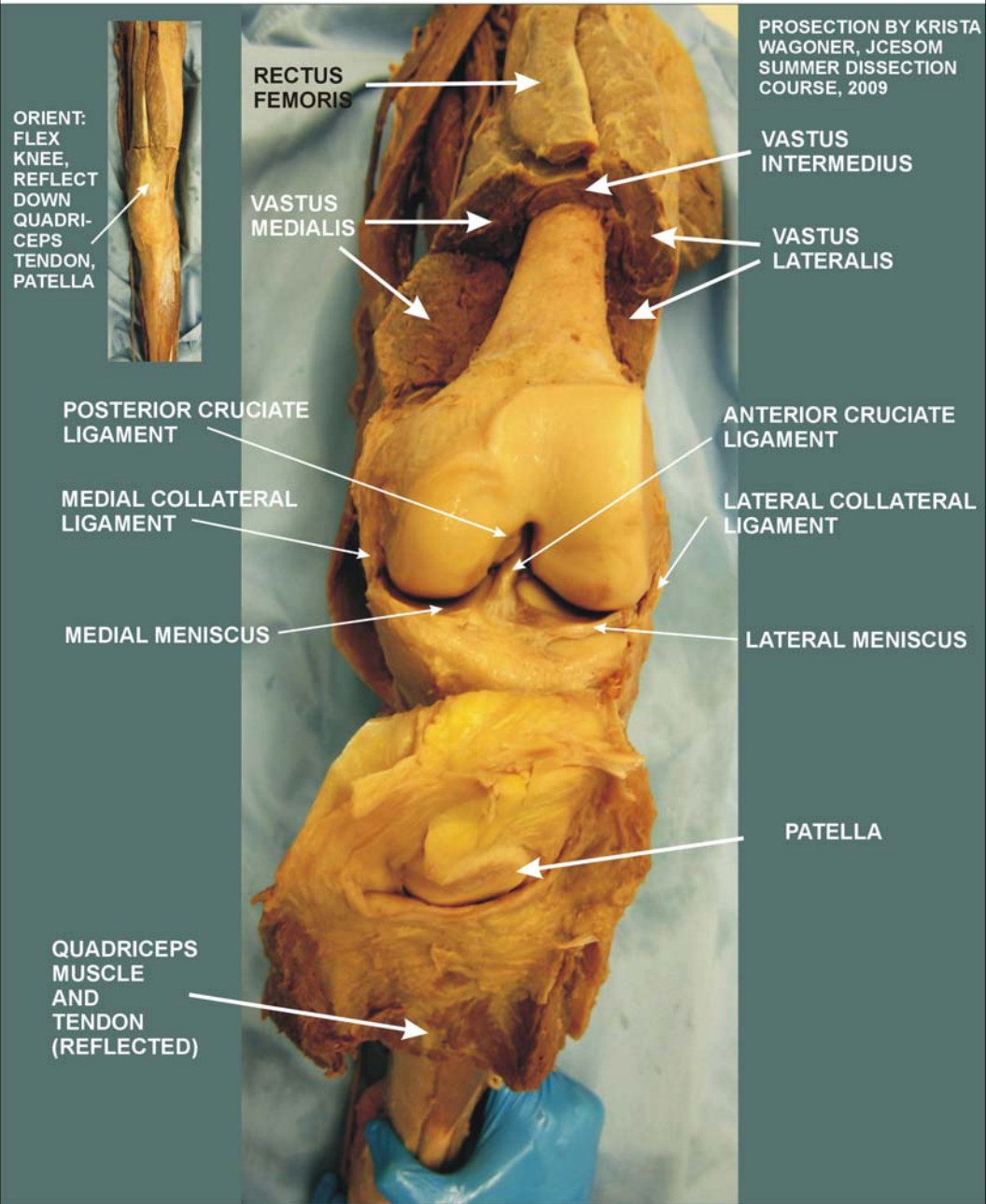
KNEE JOINT, POPLITEUS AND INTEROSSEUS MEMBRANE

PROSECTON BY RAJ
GADHIA, JCESOM SUMMER
DISSECTION COURSE, 2009



KNEE JOINT WITH MUSCLES INTACT AND REFLECTED

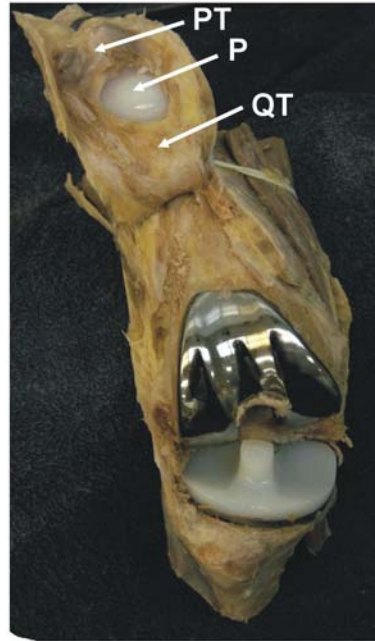310



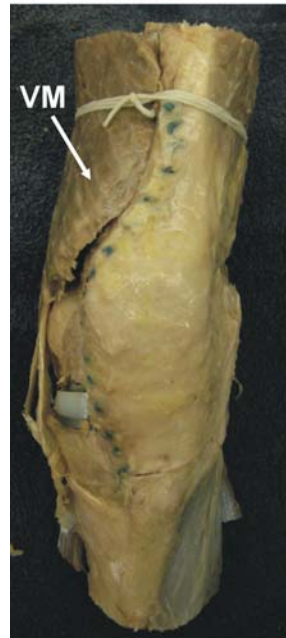KNEE JOINTS: ARTHROPLASTY

218

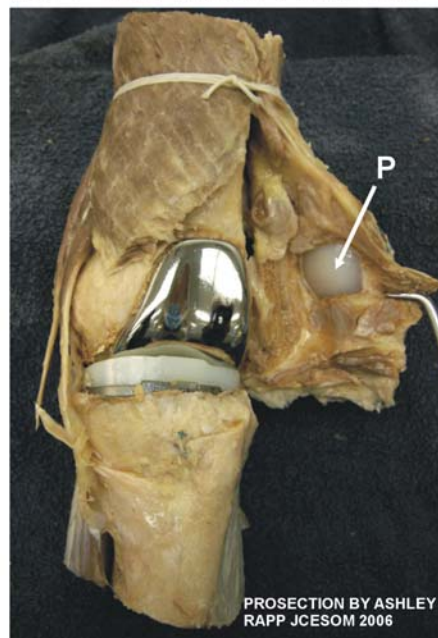RIGHT KNEE



LEFT KNEE



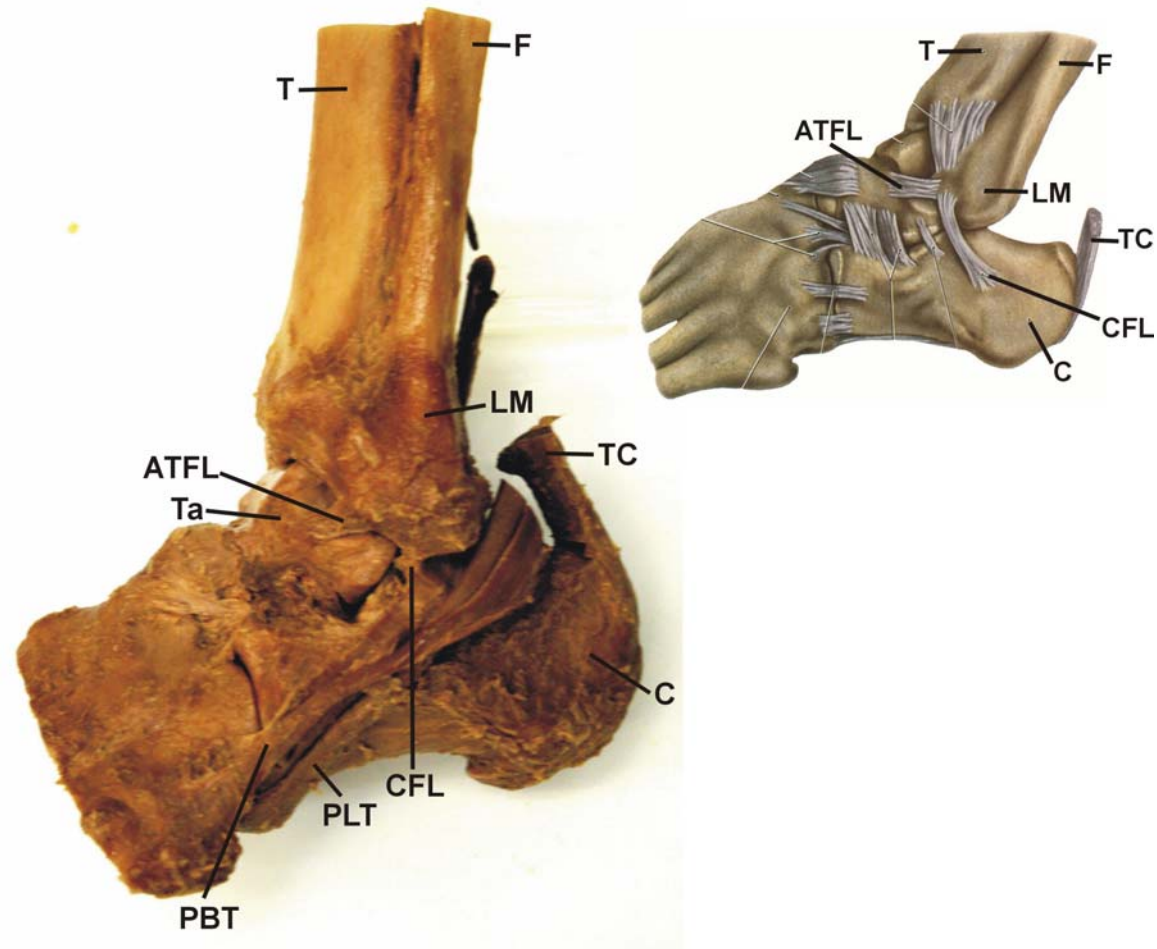
LEFT PATELLA REFLECTED



PT - PATELLAR
TENDON
P - PATELLA
QT - QUADRICEPS
TENDON
VM - VASTUS
MEDIALIS

PROSECTON BY ASHLEY
RAPP JCESOM 2006

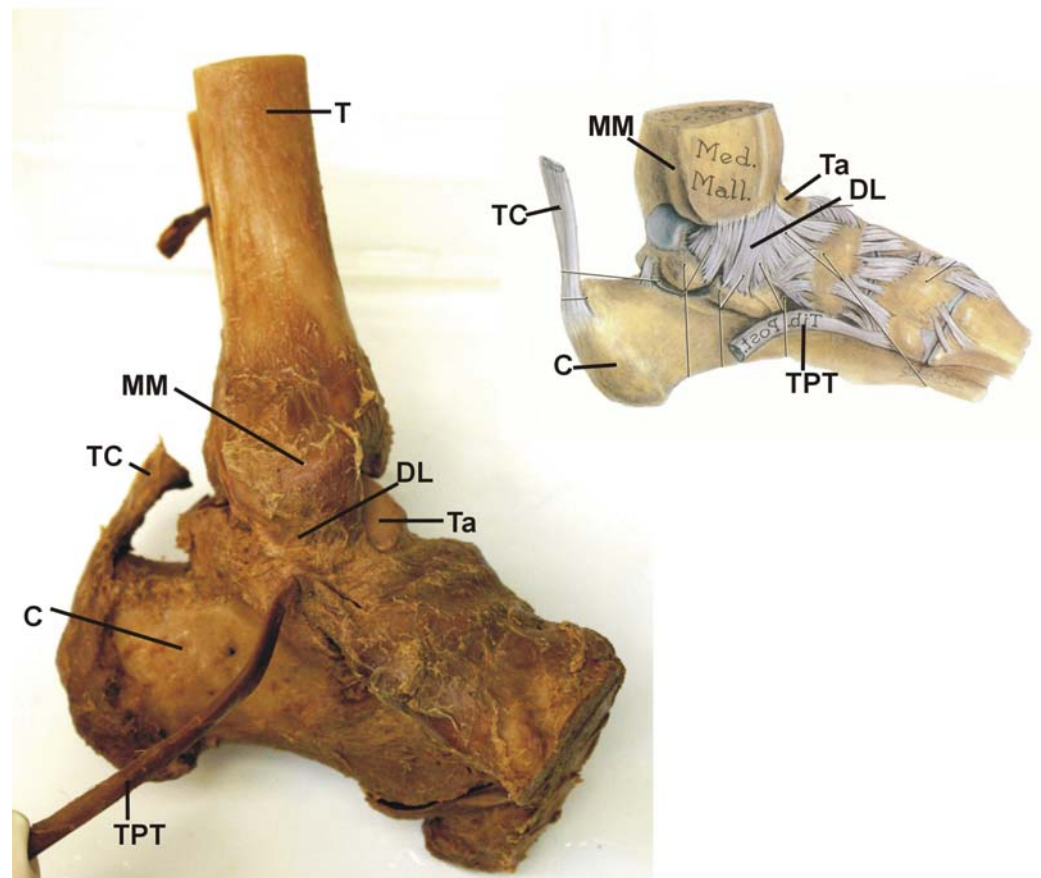
ANKLE JOINT: LATERAL SIDE 217



ATFL - ANTERIOR TALOFIBULAR LIGAMENT
C - CALCANEUS
CFL - CALCANEOFIBULAR LIGAMENT
F - FIBULA
LM - LATERAL MALLEOLUS
PBT - PERONEUS BREVIS TENDON
PLT - PERONEUS LONGUS TENDON
T - TIBIA
Ta - TALUS
TC - TENDO CALCANEUS

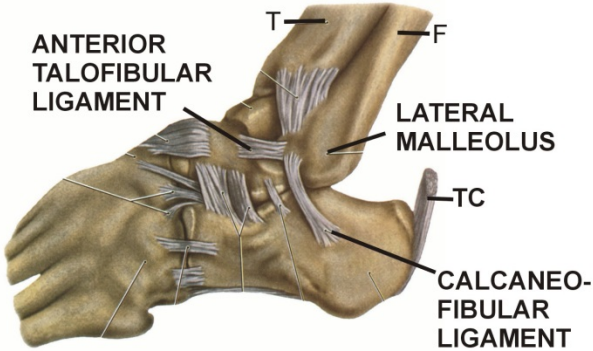
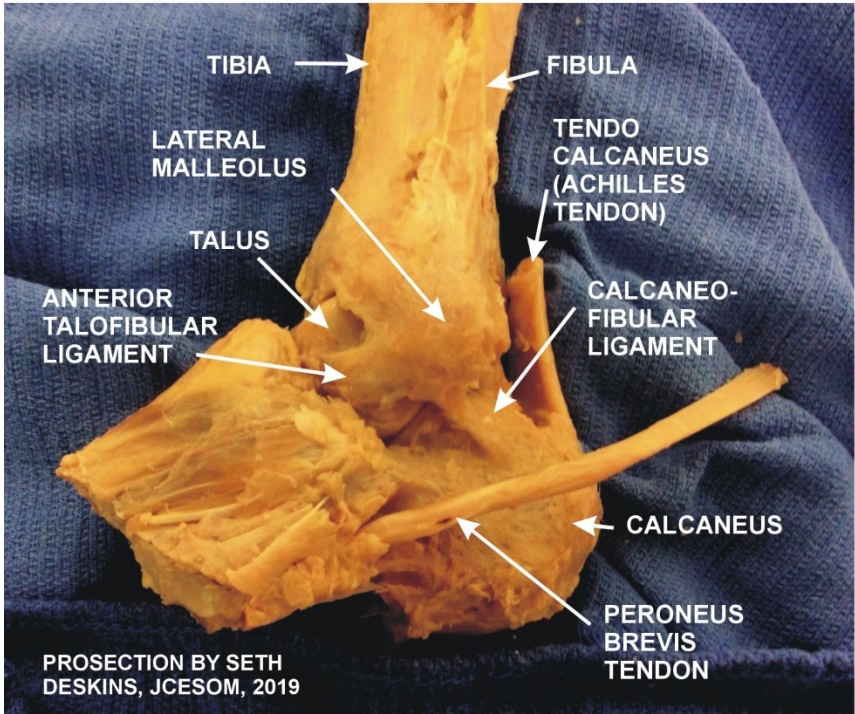
ANKLE JOINT: MEDIAL SIDE

217

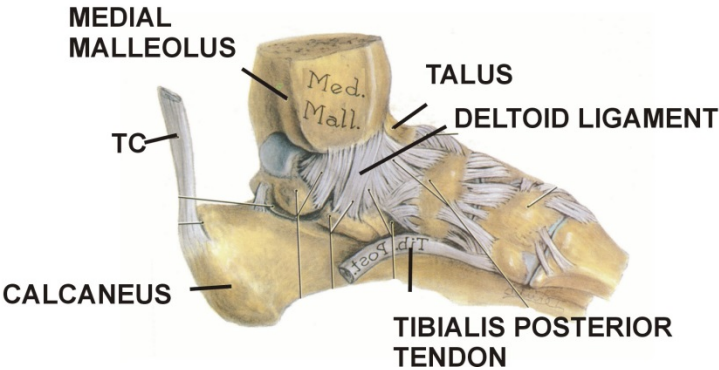
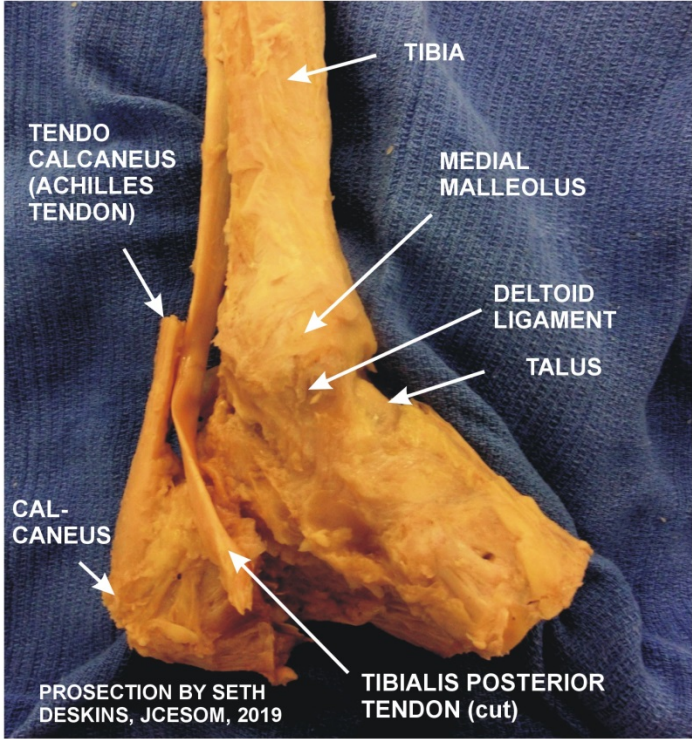


- C - CALCANEUS
- DL - DELTOID LIGAMENT
- MM - MEDIAL MALLEOLUS
- Ta - TALUS
- TC - TENDO CALCANEUS
- Ti - TIBIA
- TPT - TIBIALIS POSTERIOR TENDON (REFLECTED)

ANKLE JOINT: LATERAL SIDE

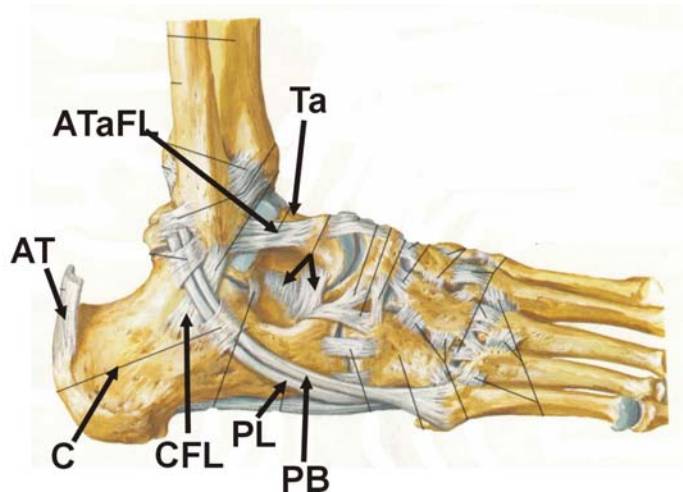
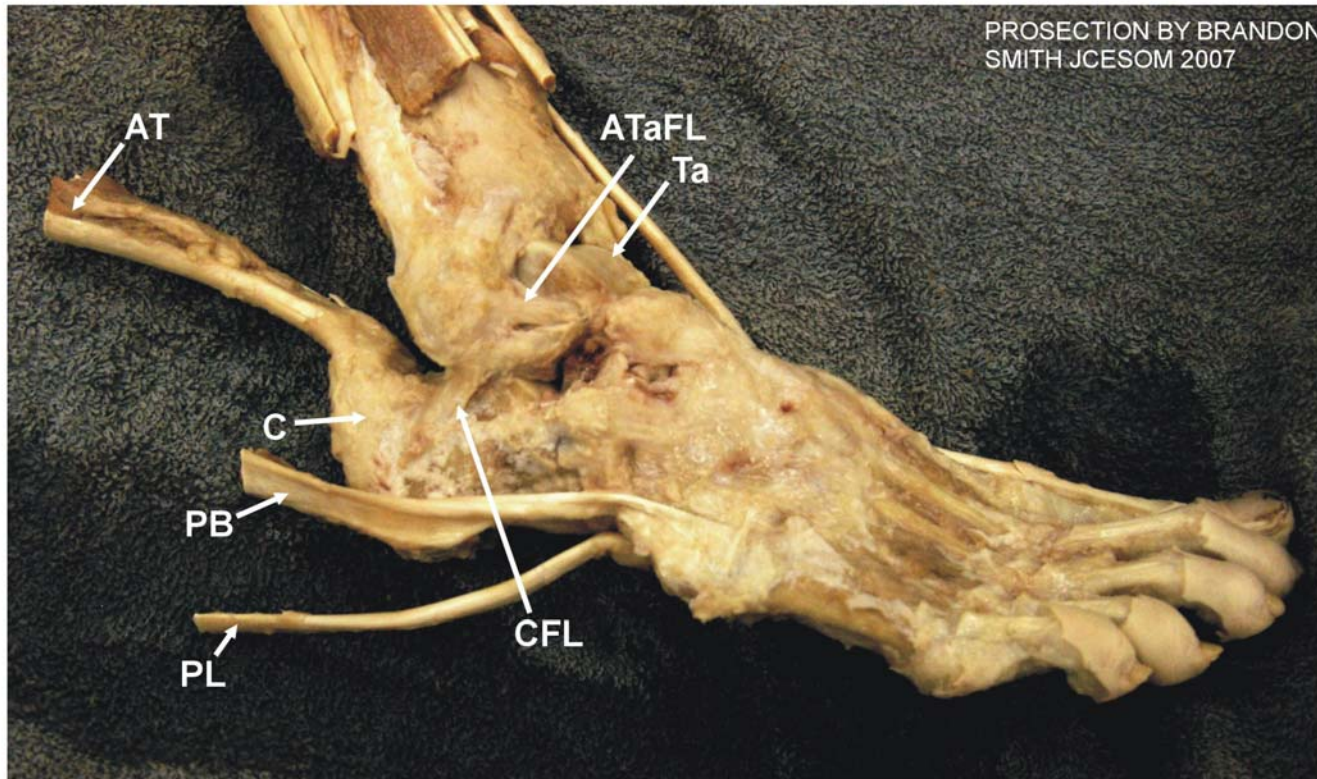


ANKLE JOINT: MEDIAL SIDE



ANKLE JOINT: LATERAL SIDE

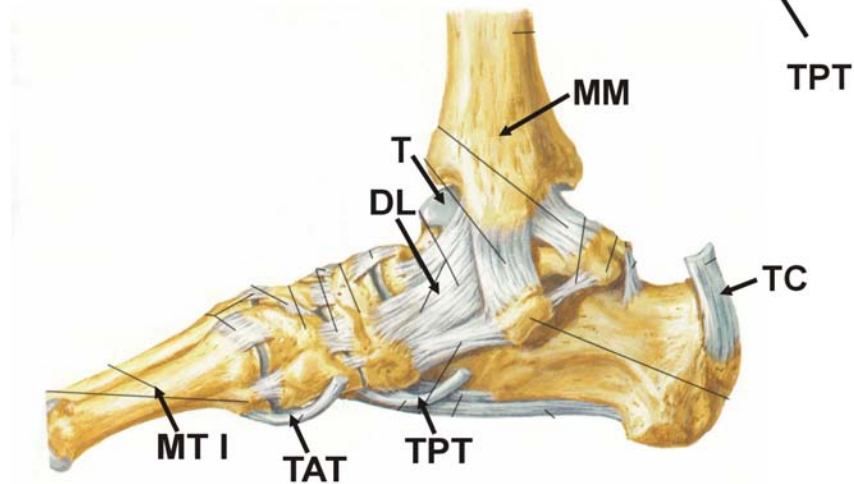
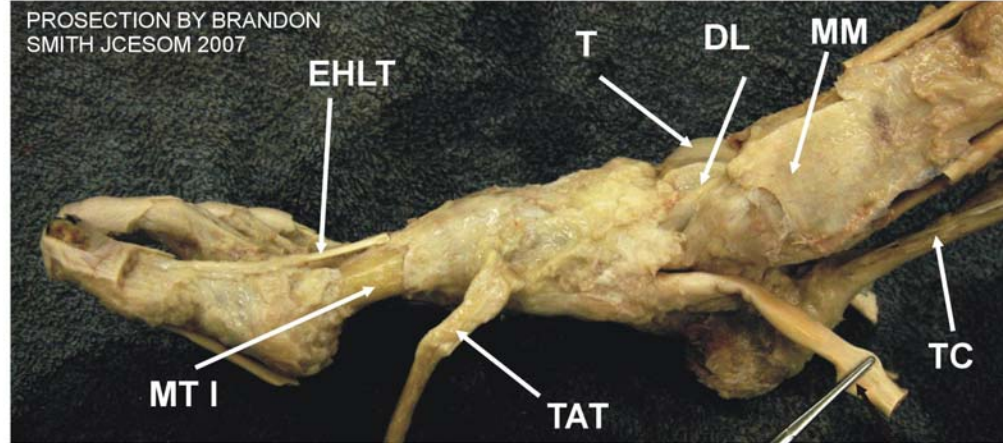
220



AT - ACHILLES TENDON
ATaFL - ANTERIOR
TALOFIBULAR LIGAMENT
C - CALCANEUS
CFL - CALCANEOFIBULAR
LIGAMENT
PB - PERONEUS BREVIS M.
PL - PERONEUS LONGUS M.
Ta - TALUS

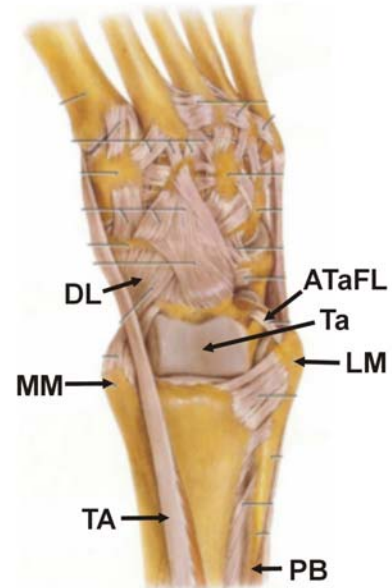
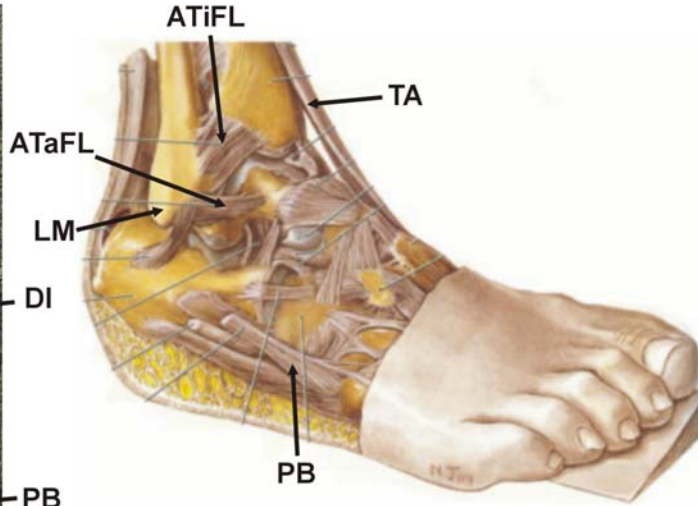
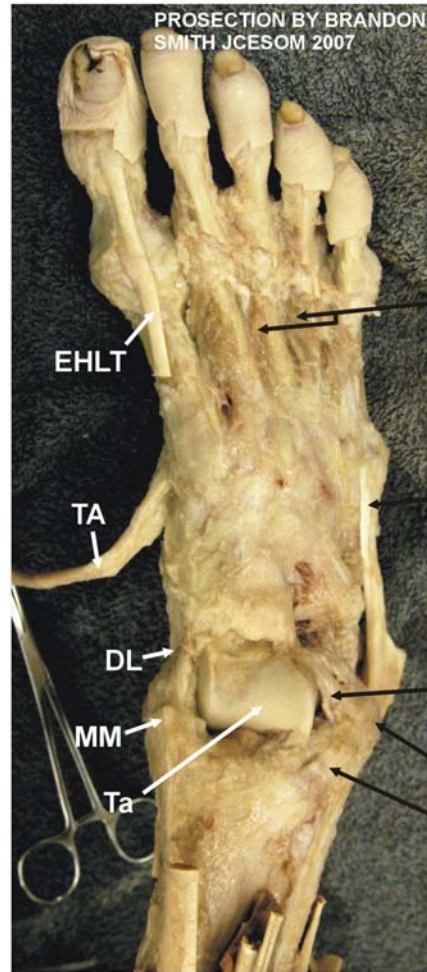
ANKLE JOINT: MEDIAL SIDE

220



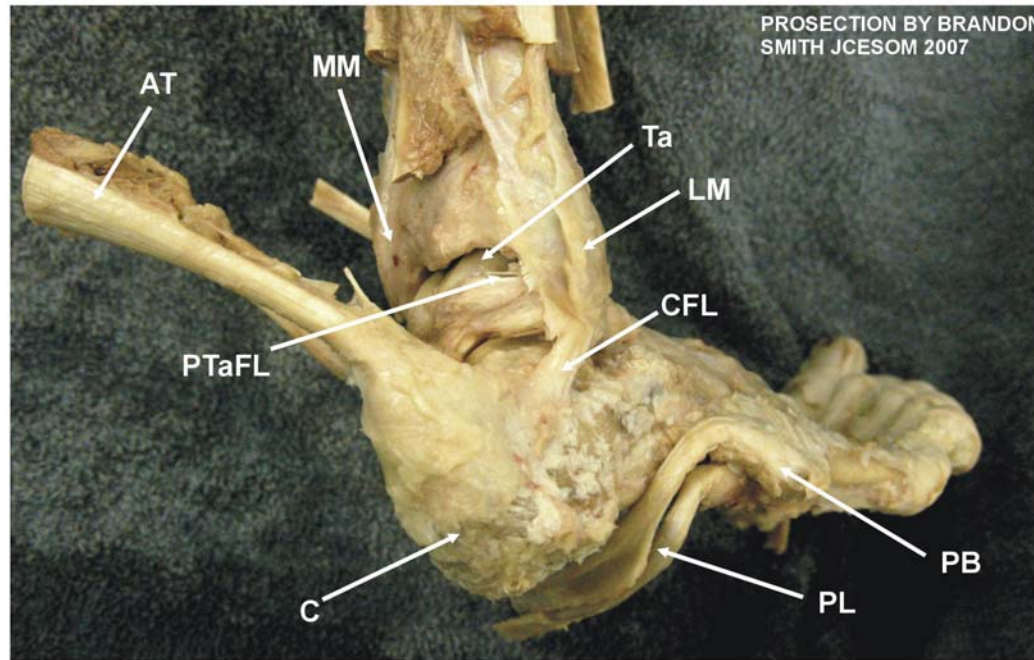
DL - DELTOID LIGAMENT
EHLT - EXTENSOR HALLUCIS LONGUS TENDON
MT I - FIRST METATARSAL
MM - MEDIAL MALLEOLUS
T - TROCHLEA OF TALUS
TAT - TIBIALIS ANTERIOR TENDON
TC - TENDO CALCANEUS
TPT - TIBIALIS POSTERIOR TENDON

ANKLE JOINT: ANTERIOR SIDE

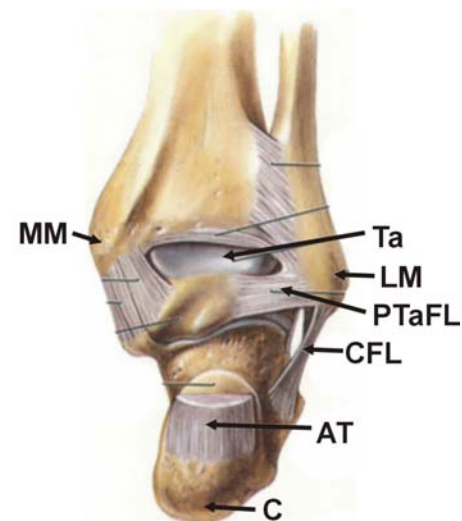


- ATiFL - ANTERIOR TIBIOFIBULAR LIGAMENT
- ATaFL - ANTERIOR TALOFIBULAR LIGAMENT
- Ta - TALUS
- DI - DORSAL INTERSOSSEUS MM.
- DL - DELTOID LIGAMENT
- EHLT - EXTENSOR HALLUCIS LONGUS TENDON
- LM - LATERAL MALLEOLUS
- MM - MEDIAL MALLEOLUS
- PB - PERONEUS BREVIS M.
- TA - TIBIALIS ANTERIOR M.

ANKLE JOINT: POSTERIOR SIDE 220



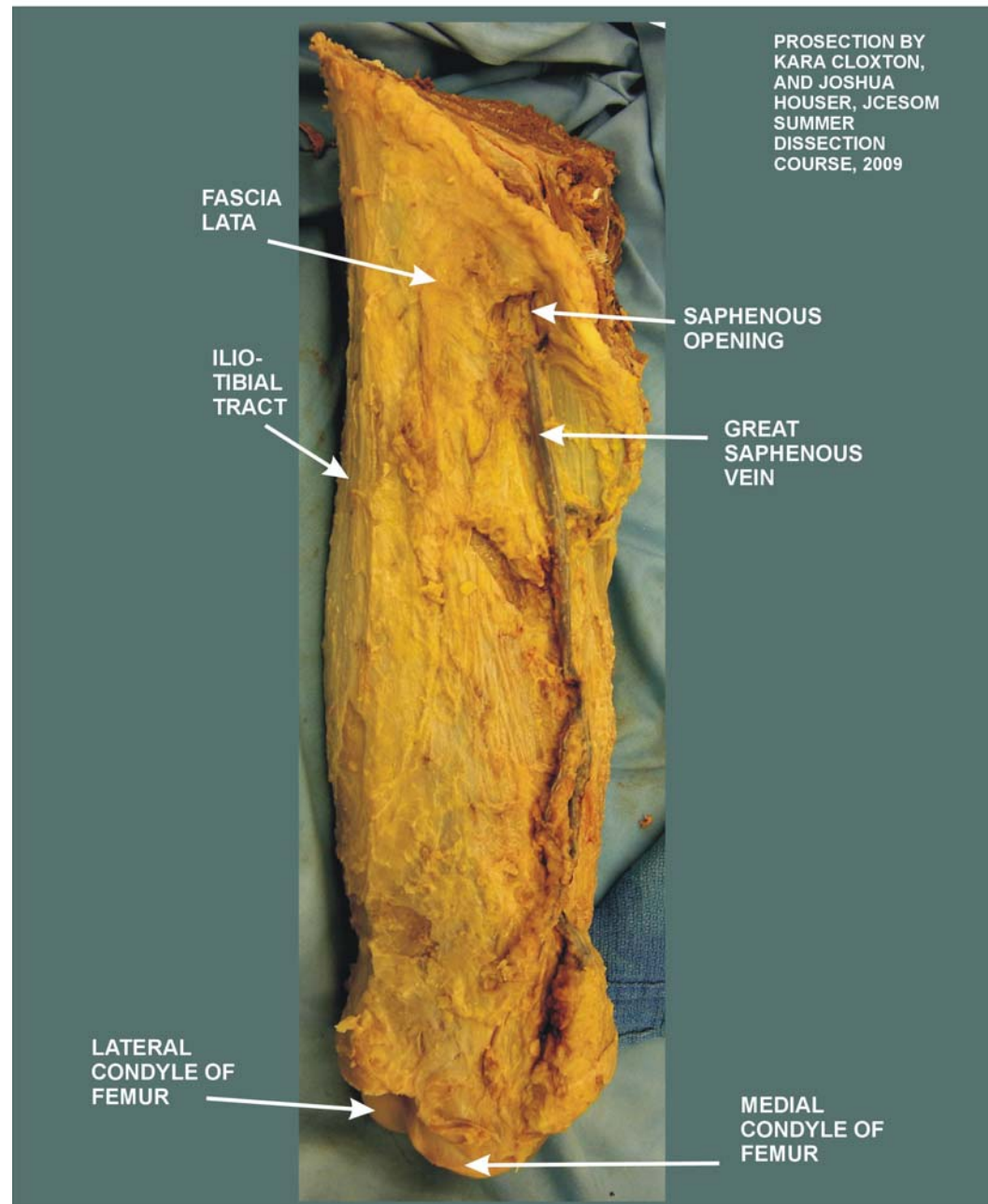
- AT - ACHILLES TENDON
- C - CALCANEUS
- CFL - CALCANEOFIBULAR LIGAMENT
- LM - LATERAL MALLEOLUS
- MM - MEDIAL MALLEOLUS
- PB - PERONEUS BREVIS M.
- PL - PERONEUS LONGUS M.
- PTaFL - POSTERIOR TALOFIBULAR LIGAMENT
- Ta - TALUS



SAPHENOUS OPENING

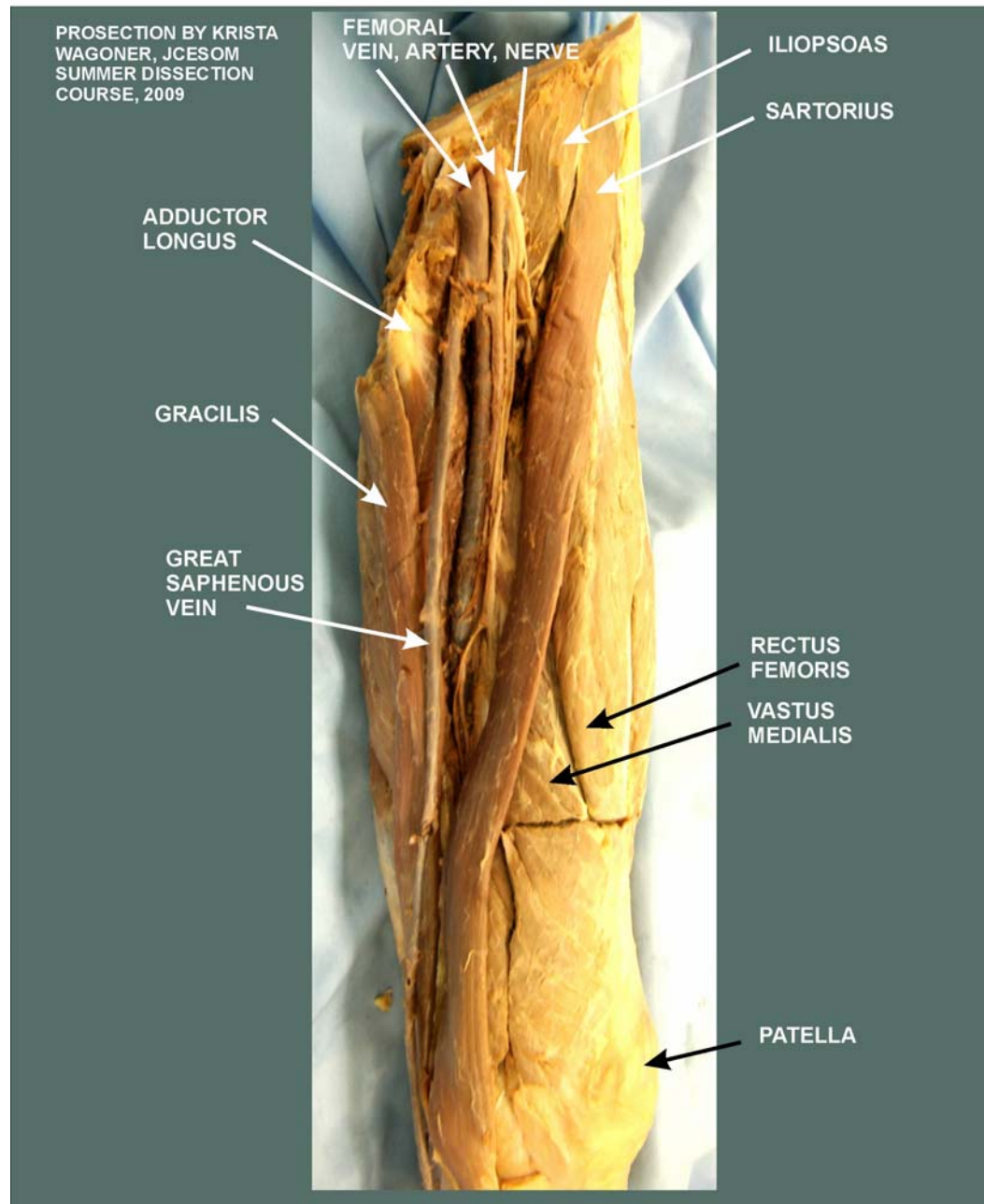
311

C. THIGH, LEG PROSECTIONS



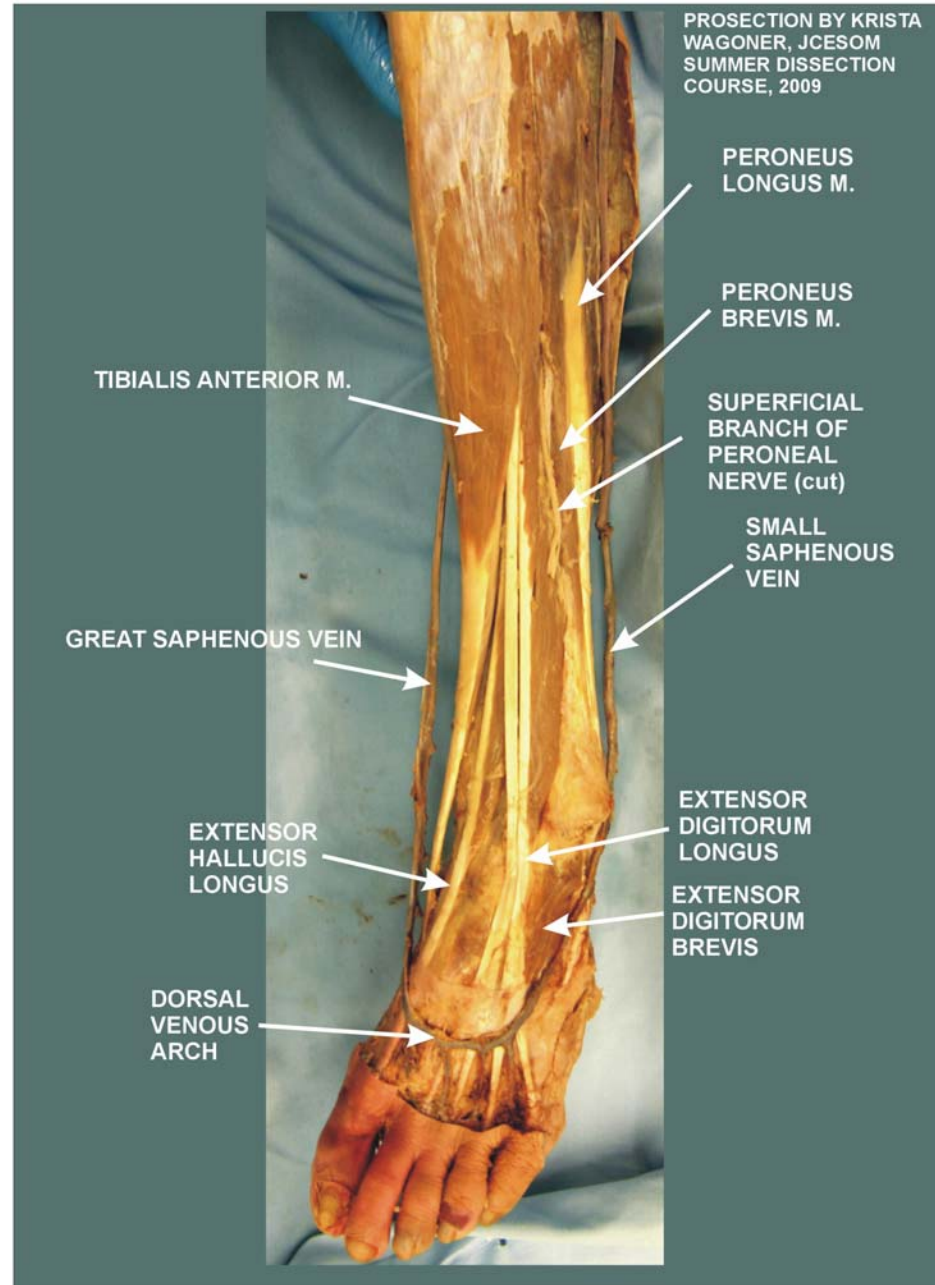
MEDIAL THIGH/GREAT SAPHENOUS VEIN

310

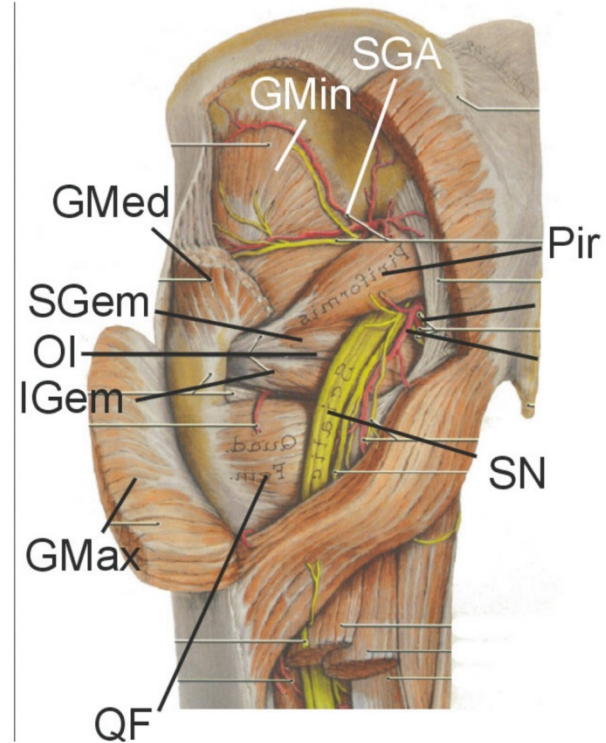
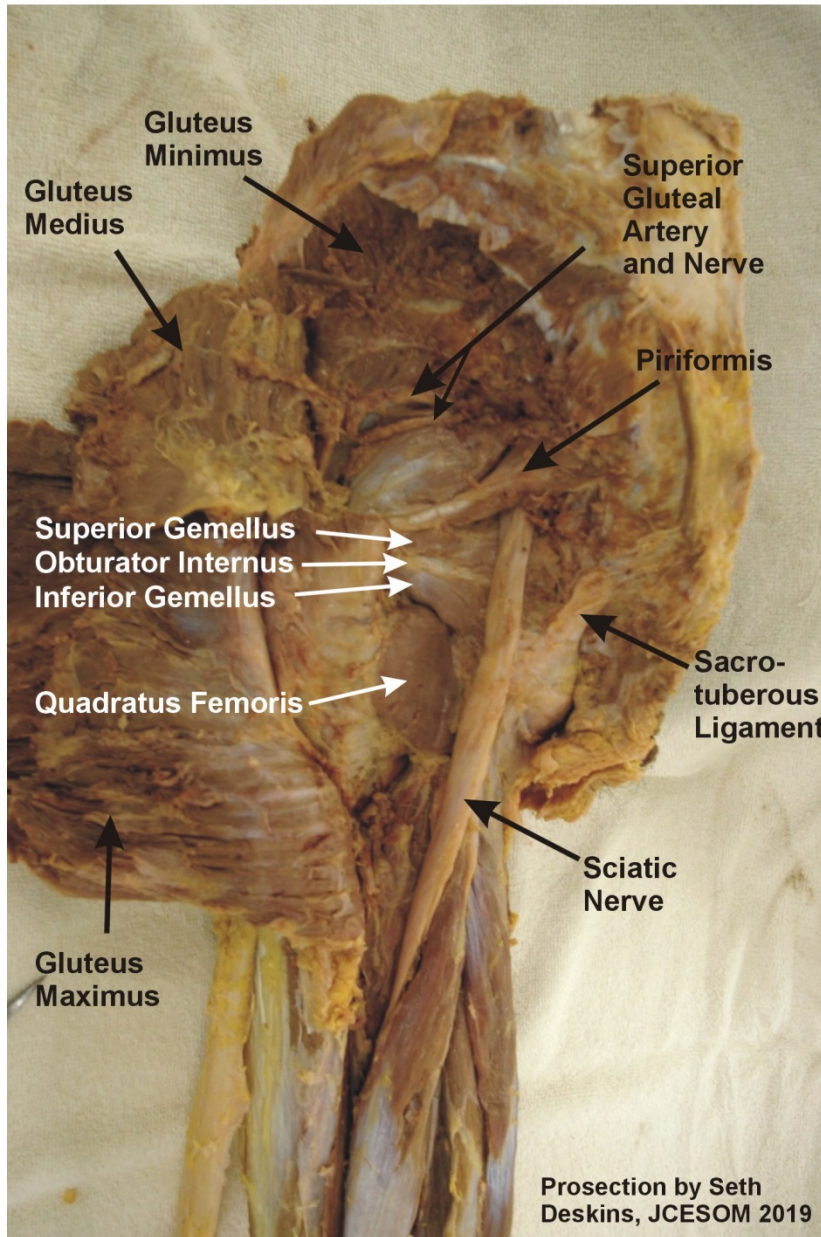


DORSUM OF LEG/VENOUS ARCH OF FOOT

310

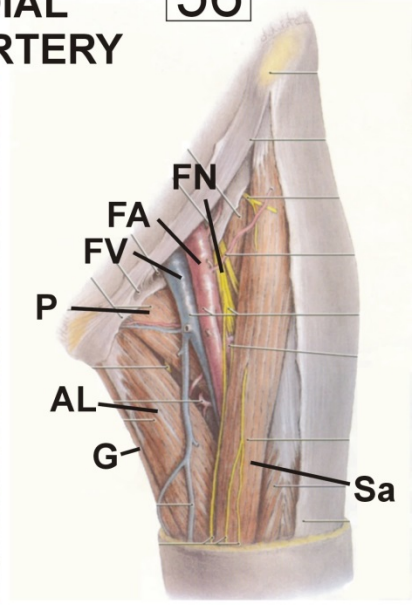
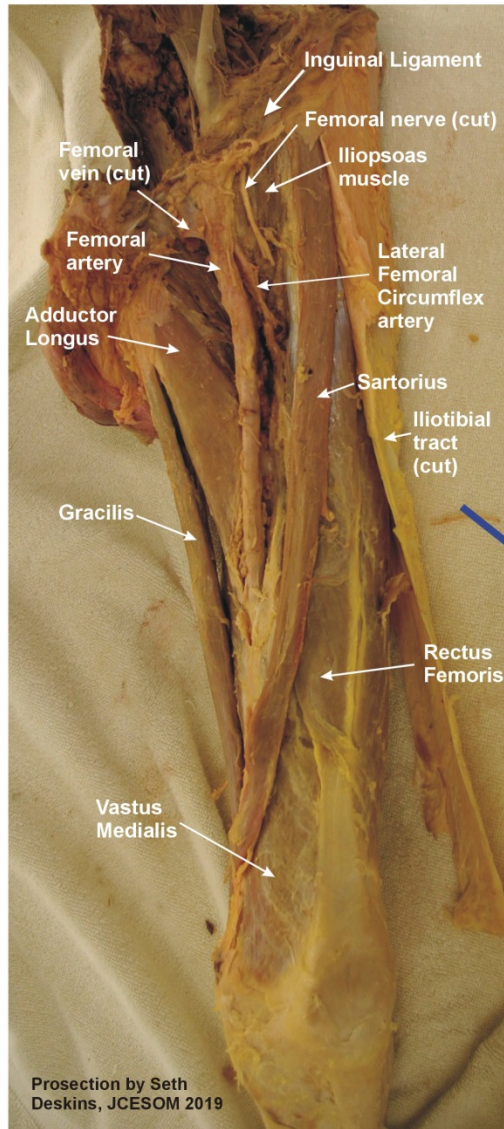


GLUTEAL REGION

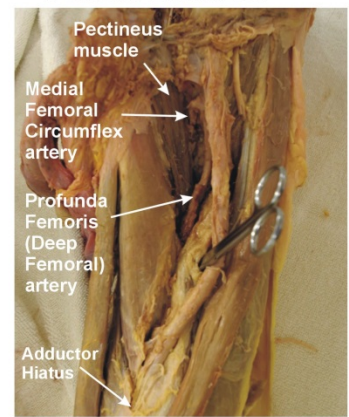


FEMORAL TRIANGLE: MEDIAL FEMORAL CIRCUMFLEX ARTERY

56



CAREFULLY REFLECT FEMORAL ARTERY



Prosection by Seth Deskins, JCESOM 2019