

NECK Part I

© 2021zillmusom

I. OVERVIEW OF NECK

A. Neck is compartmentalized:

1. Posterior compartment - contains
 - a. Vertebrae of neck = cervical vertebrae
 - b. Muscles which surround and move cervical vertebrae and neck: i. posterior to vertebrae, muscles are continuations of Muscles of Back and Suboccipital region; ii. laterally, muscles are called Scalenes; iii. anteriorly, muscles located directly anterior to vertebrae are called Prevertebral muscles
2. Anterior compartment contains
 - a. Viscera - in lower part of neck: Trachea, Thyroid gland and Esophagus.
 - b. Pharynx - in upper part of neck: Pharynx. Pharynx is a tube composed of muscles and fascia that is continuous anteriorly with the Oral and Nasal cavities; the Esophagus and the Larynx open into the pharynx.
3. Lateral compartment (lateral and posterior to pharynx) - Carotid Sheath contains blood vessels (Carotid arteries and Internal Jugular veins) and Vagus nerve; Sympathetic Chain is posterior to Carotid Sheath.

II. **MUSCLES OF NECK** - see Table of Muscles of Neck for actions and innervation.

A. Muscles not attached to hyoid bone

1. Sternocleidomastoid muscle

Note: **Torticollis** (L. torti, twisted; collum, neck) - Rotational torticollis can be congenital or acquired; associated with contracture of Sternocleidomastoid; **head is rotated so face is directed to opposite side (contralateral to lesion)** (BOARD QUESTION).

Note: Sternocleidomastoid is important landmark in diagnosis and procedures in neck. **Internal Jugular vein** can be accessed and catheterized between Sternal and Clavicular heads of Sternocleidomastoid; Thyroid gland and Jugular chain of Lymphatics are located anterior to Sternocleidomastoid; Branchial cleft cysts are lateral masses anterior to Sternocleidomastoid.

2. Scalenus anterior and medius

Note: Scalene muscles are important landmarks; Brachial plexus and Subclavian artery pass between Scalenus Anterior and Scalenus Medius; **Phrenic nerve (nerve to Diaphragm) passes anterior to Scalenus Anterior, posterior to Sternocleidomastoid** (BOARD QUESTION).

B. Hyoid bone - located in anterior part of neck; 'free-floating', attached to skull and skeleton only by muscles and ligaments; Stylohyoid ligament links hyoid to styloid process of temporal bone; Thyrohyoid membrane link hyoid to Thyroid cartilage; Hyoid bone has parts: body (central part),

Greater and Lesser horns (cornu); all Infrahyoid and Suprahyoid muscles (except Sternothyroid) attach to body of hyoid; Greater horns can be palpated in neck above thyroid cartilage and used as landmarks to locate surrounding structures.

Functional Note: **Hyoid bone anchors tongue and floor of mouth; also supports larynx;** muscles which move hyoid bone produce movements of larynx and tongue (as occur during swallowing and talking)

C. Infrahyoid muscles - all muscles act to depress hyoid bone: Omohyoid, Sternohyoid, Sternothyroid, Thyrohyoid.

D. Suprahyoid muscles - all act to elevate the hyoid bone: Digastric - also opens mouth; Stylohyoid - note: splits to surround digastric tendon; Mylohyoid - forms muscular floor of mouth; Geniohyoid - pulls hyoid forward.

III. NERVES OF NECK

A. Cervical plexus - formed from ventral primary rami of spinal nerves C2-C4, which emerge from posterior border of Sternocleidomastoid (near its mid-point); most branches are cutaneous:

1. Lesser Occipital nerve - innervates skin behind ear and skin of upper lateral neck
2. Great Auricular nerve - innervates skin over parotid gland and skin located inferior to ear.
3. Transverse Cervical nerve - innervates skin of anterior neck.
4. Supraclavicular nerves - innervate skin of lower lateral neck and shoulder
5. **Phrenic nerve** - (C3,4,5) provides motor innervation to the diaphragm, crosses anterior to Scalenus Anterior muscle, posterior to Sternocleidomastoid.

B. Ansa cervicalis – loop of fibers from **cervical spinal nerves that innervate neck muscles**; loop is attached to the Hypoglossal nerve; fibers from C1 travel with Hypoglossal nerve then leave and join fibers from C2 and C3 forming a loop; loop is located anterior to Carotid sheath and is attached to Hypoglossal nerve; however, **no fibers from the Hypoglossal nerve innervate neck muscles.**

IV. ARTERIES OF HEAD AND NECK

A. Subclavian artery - at root of neck; artery passes laterally toward arm, posterior to Scalenus Anterior muscle; Scalenus Anterior muscle is used as a landmark to divide the artery into three parts:

1. Part I (medial to Scalenus Anterior) - **three branches:** (1) **Vertebral artery**, which ascends into neck and enters foramina transversaria of vertebra C1-C6; (2) **Internal Thoracic artery** which descends into thorax posterior to sternum; (3) **Thyrocervical trunk** - branches into **Inferior Thyroid, Transverse (or Superficial) Cervical, and Suprascapular arteries.**

2. Part II (post. to Scalenus Ant.) - one branch: **Costocervical trunk** - which

branches into a. Superior Intercostal artery to supply first two intercostal spaces with Posterior Intercostal arteries and b. Deep Cervical Artery to deep neck muscles.

3. Part III (lat. to Scalenus Ant.) - no branches.

B. Carotid arteries - Common carotid artery arises from aorta on left, brachiocephalic artery on right; it ascends into neck and divides at level of upper border of thyroid cartilage (vertebral level C4) into Internal and External Carotid arteries; Internal Carotid artery ascends to skull without branching; **External Carotid branches** supply face and scalp; branches are (from inferior to superior):

Branches from Anterior side of External Carotid

1. Superior Thyroid artery - descends to thyroid gland - gives off Superior Laryngeal artery which courses to larynx.
2. Ascending Pharyngeal artery - small branch which ascends to pharynx.
3. Lingual artery - ascends to supply tongue.
4. Facial artery - arises below mandible; first courses medial to mandible to supply tonsils and salivary glands; then crosses over surface of mandible to supply face, lips and nose.

Branches from Posterior side of External Carotid

5. Occipital artery - small branch which arises on posterior side of ext. carotid (opposite Facial artery) and supplies posterior scalp.
6. Posterior Auricular artery - small branch from posterior side of External Carotid which supplies posterior ear and adjacent scalp.

Terminal branches of External Carotid - Ext. Carotid ends when it divides into:

7. Superficial Temporal artery - large terminal branch of External Carotid; arises opposite External Auditory meatus; ascends to supply scalp and Temporalis muscle.
8. Maxillary artery - second large terminal branch of External Carotid; many branches (considered in lecture on Infratemporal region).

Clinical Note: **Carotid Artery Stenosis is a major cause of ischemic stroke of the brain.** MRI and CT angiography are the principal diagnostic tools for diagnoses and surgical intervention (Carotid Endarterectomy).

V. VEINS OF HEAD AND NECK

A. Overview - most arterial branches have accompanying veins (venae comitantes); branching pattern is variable; normally:

1. Superficial Temporal and Maxillary veins unite to form Retromandibular vein.
2. Retromandibular vein divides at angle of mandible into Anterior and Posterior divisions.
3. Anterior division joins Facial Vein to form Common Facial vein which drains into Internal Jugular vein.

4. Posterior division joins Posterior Auricular vein to form External Jugular vein.
5. External Jugular vein descends across Sternocleidomastoid muscle to drain into Subclavian vein.
6. Anterior Jugular vein forms from small veins below mandible; descends to join Ext. Jugular vein above clavicle.

VI. FASCIA OF NECK

A. Superficial fascia - loose connective tissue below dermis; in neck generally thin and hard to demonstrate; contains platysma muscle and superficial veins.

B. Deep cervical fascia - layers of connective tissue; one layer completely surrounds neck; other layers form tubes contained within that layer; names of some layers are confusing

1. Investing layer of Deep cervical fascia - completely surrounds neck; splits into 2 layers to enclose Trapezius, Sternocleidomastoid, Suprahyoid and Infrahyoid muscles.
2. "Prevertebral" layer of deep cervical fascia - forms a tube which completely surrounds vertebral column, muscles of back of neck, prevertebral, lateral vertebral and suboccipital muscles (not Trapezius).
3. "Pretracheal" (visceral) layer of deep cervical fascia - actually completely surrounds cervical viscera, including thyroid gland, trachea, and esophagus; inferiorly it enters mediastinum.

Clinical Note: Retropharyngeal space - potential space between "prevertebral" and "pretracheal" layers; **infection (Retropharyngeal abscess)** can spread from head (as in tonsillitis) and neck via retropharyngeal space into mediastinum; George Washington may have died from this.

4. Carotid sheath - paired; on each side surrounds Common and Internal Carotid arteries, Internal Jugular vein, Vagus nerve, and Deep Cervical lymph nodes (sympathetic chain is posterior to carotid sheath); **infections tend to remain localized within the sheath.**

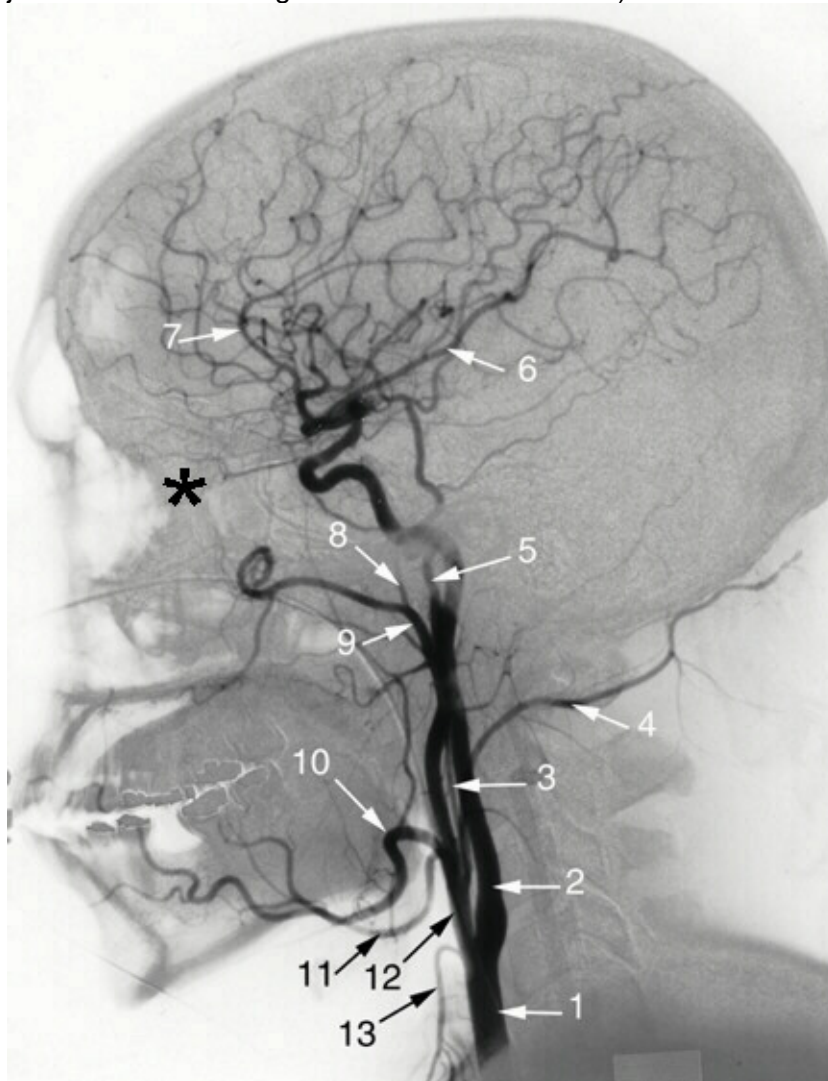
Clinical Note: Infections within Carotid sheath and Opioid drug use - Heroin (and fentanyl) addicts can cause infections within the Carotid sheath by attempting to inject drugs intravenously into the Internal Jugular vein.

Anatomical Note: The Internal Jugular Vein courses inside the Carotid Sheath. The External Jugular vein is NOT in the sheath but typically courses on the surface of the Sternocleidomastoid muscle.

VII. **LYMPHATICS OF HEAD AND NECK** - described as three groups of lymphatics and nodes: Superficial and Deep Rings of nodes and Deep Cervical chain

- A. Superficial Ring of nodes - drain areas adjacent to their location: consist of Submental, Submandibular, Buccal, Parotid, Retroauricular and Occipital nodes.
- B. Deep Ring of nodes - consist of Retropharyngeal and Pretracheal nodes.
- C. Deep Cervical Chain of lymph nodes - chain of nodes along Internal Jugular vein; receive lymph vessels from all nodes of head and neck.

D. Jugular lymph trunk - efferent lymph vessels from deep cervical nodes drain into Thoracic Duct (on left), Right Lymphatic Duct (on right); these drain into Brachiocephalic veins (at junction of Internal Jugular and Subclavian Veins).



1. COMMON CAROTID
2. INTERNAL CAROTID
3. ASCENDING PHARYNGEAL
4. OCCIPITAL
5. SUPERFICIAL TEMPORAL
6. MIDDLE CEREBRAL
7. ANTERIOR CEREBRAL
8. MIDDLE MENINGEAL
9. MAXILLARY
10. FACIAL
11. LINGUAL
12. EXTERNAL CAROTID
13. SUPERIOR THYROID

*- OPHTHALMIC ARTERY ARISING FROM CAROTID SIPHON