

ORBIT, EYE STRUCTURES AND EYE MUSCLES

© 2024zillmusom

I. **FORAMINA OF ORBIT** - openings which transmit nerves and vessels to structures in orbit (eye, extraocular muscles and lacrimal gland (tears)); also **IMPORTANTLY**, orbit serves as passageway for nerves that are sensory to face, scalp and nasal cavity - (same information in Foramina handout)

1. Optic foramen and canal - located at base of Lesser wing of sphenoid bone in middle cranial fossa; connects middle cranial fossa to orbit; contains Optic nerve (II) and Ophthalmic artery.

2. Superior Orbital fissure - located between Greater and Lesser wings of Sphenoid bone in Middle Cranial fossa; connects middle cranial fossa and orbit; contains Oculomotor (III), Trochlear (IV), Abducens (VI) nerves and Ophthalmic division of Trigeminal nerve (V1) and Ophthalmic veins.

3. Supraorbital notch or foramen - located in frontal bone; connect orbit and forehead; contain Supraorbital n., a. and v.

4. Infraorbital foramen - in maxillary bone; connects orbit and face; contains Infraorbital n., a. and v.

5. Anterior and Posterior Ethmoidal Foramina - located between ethmoid and frontal bones; connect orbit and nasal cavity; contain (respectively) Anterior and Posterior Ethmoidal nerves (branches of V1), arteries (branches of Ophthalmic artery), and veins.

6. Nasolacrimal duct - located in maxillary, lacrimal bones and Inferior nasal concha; connects orbit and nasal cavity; contains Membranous Nasolacrimal duct and tears.

II. **EYELIDS** - layered, moveable structures which protect eye, keep cornea (outermost layer) of eye moist.

A. Layers

1. Skin - contains eyelashes (cilia), openings of sebaceous and sweat glands.

2. Subcutaneous layer - connective tissue containing sebaceous glands;

Clinical: **Obstruction of sebaceous glands in subcutaneous layer of eyelid called a sty (hordeolum).**

3. Orbicularis oculi muscle - skeletal muscle which surrounds eyelid; closes eyelids; innervated by Facial nerve (VII); damage to facial nerve paralyzes muscle; patient unable to close eyelids and spread tears over cornea; can result in corneal damage.

4. Orbital septum, tarsal plate and Levator Palpebrae Superioris muscle.

a. Orbital septum - fascial layer inside eyelid, is continuous with

connective tissue lining orbit (periorbita).

b. Tarsal plate - dense fibrous connective tissue, located deep to orbital septum; forms 'skeleton' of eyelid; contains **tarsal glands**.

Clinical: Obstruction of **tarsal glands in eyelid called a chalazion**.

c. Levator palpebrae superioris muscle - muscle composed of both smooth and skeletal muscle components; origin - Tendinous ring (see below); insertion - skin and tarsal plate of upper lid; action - opens eyelids; **innervation - skeletal part by Oculomotor nerve (III), smooth part by Sympathetics**.

Clinical – Ptosis = eyelid droop, important clinical sign; can result from damage to Oculomotor Nerve (III) or sympathetics.

5. Conjunctiva - membrane covering inner side of eyelid; conjunctiva continues as a layer over sclera of eye and fuses to cornea; reflection of conjunctiva from eyelid to eye called Superior and Inferior fornices of conjunctiva; very sensitive.

III. **LACRIMAL APPARATUS** - tears are constantly produced in lacrimal gland, drain to nasal cavity via lacrimal duct.

A. Lacrimal gland - located in superolateral orbit; have numerous ducts (about 12) which open through conjunctiva; produce tears;

Flow of tears: circulate over conjunctiva and wash out dirt; drain through **lacrimal puncta** (openings) in medial part of upper and lower eyelids (you can see these on yourself in a mirror); puncta drain to **lacrimal sac** which drains via **Nasolacrimal duct** to **Inferior Meatus of nasal cavity** (this is why you blow your nose when you are crying)

B. Innervation of lacrimal gland - **Parasympathetics from Facial nerve (VII)** via a complicated pathway in which fibers hitch-hike with branches of the Trigeminal nerve (V) (more in future Cranial nerve lecture).

Clinical: **Obstructed Nasolacrimal Duct** - Nasolacrimal duct develops embryologically as a solid cord between maxillary and nasal processes; cord then becomes canalized; failure of canalization is Obstructed Nasolacrimal duct; tears flow onto face of neonate.

IV. **FASCIAL SHEATH OF EYEBALL** - thin fascial membrane surrounding eye (also called Tenon's capsule); thickenings of sheath attach to bones and form Medial and Lateral Check ligaments which prevent excess movement of eye.

V. **LAYERS OF EYE**

A. Structure of eyeball - described as three layers

1. Fibrous layer

a. Sclera - tough, smooth fibroelastic layer surrounding eye (continuous anteriorly with cornea); functions to protect eye and maintain shape; provides attachment of extraocular muscles; pierced by nerves and vessels of eye.

b. Cornea - avascular, transparent layer covering anterior eye; important in focusing light; **Clinical: irregularities in cornea responsible for astigmatism.**

2. Vascular layer

Note: Blood supply to eye is derived from branches of **Ophthalmic artery** (from Internal Carotid Artery); major branches to eye: 1. Choroidal arteries (Anterior and Posterior) - to choroid; 2) Central Artery of Retina - to retina.

a. Choroid - highly vascular (Choroidal arteries and veins), pigmented membrane; provides nutrients and oxygen to other layers of eye.

b. Ciliary body - attaches to suspensory ligament of lens; hold lens taut; contains ciliary muscles.

i. Ciliary muscles - smooth muscles attached to suspensory ligaments of lens; **contraction of muscles produces relaxation of suspensory ligaments; causes lens to thicken for near vision (accommodation)**; innervation - **Parasympathetics from Ciliary ganglion (nerve III)** cause contraction of ciliary muscles (parasympathetics travel in **Short Ciliary nerves**).

c. Iris - pigmented, contractile layer surround pupil (opening); controls amount of light entering eye; contains two muscles

i. Constrictor pupillae - circular smooth muscle which constricts iris, pupil; innervated by Parasympathetics (from Ciliary ganglion of III).

ii. Dilator pupillae - radial smooth muscle which dilates pupil; innervated by sympathetics.

3. Retina - contains photosensitive rods and cones and many neurons which process visual information; artery - **Central Artery of Retina** (branch of Ophthalmic artery), classically thought to have no anastomoses (occlusion results in blindness).

New Anatomy: imaging has shown that branches of Ciliary Arteries (**Cilioretinal arteries**) are present in about 20% of people; can provide partial sparing of retina in cases of

Central Retinal Artery Occlusion (CRAO).

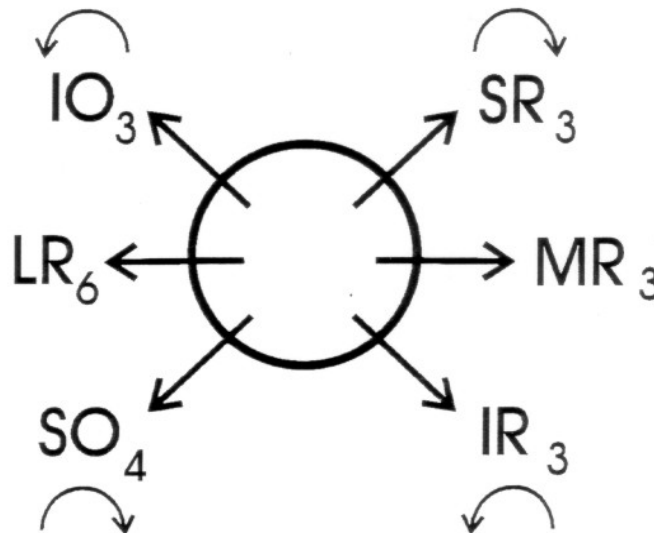
Note: **Subarachnoid space extends around optic nerve** up to its junction with sclera in back of eyeball; optic nerve can be viewed in ophthalmoscope as optic disc; **changes in intracranial pressure (ex. hydrocephalus) can be diagnosed by viewing optic disc.**

VI. EXTRAOCULAR MUSCLES

A. Origins - all take origin from Tendinous ring (except Inferior Oblique which has origin on floor of orbit); Tendinous ring is ring of connective tissue surrounding opening of Optic canal and Superior Orbital Fissure.

B. Actions and Innervation

Muscle	Nerve	Action
Medial rectus	III	Adduct eye
Lateral rectus	VI	Abduct eye
Inferior rectus	III	Adduct, lower and laterally rotate eye
Superior rectus	III	Adduct, raise and medially rotate eye
Superior oblique	IV	Abduct, lower and medially rotate eye
Inferior oblique	III	Abduct, raise and laterally rotate eye.



VII. NERVE DAMAGE

A. **Abducens** nerve (VI) - damage causes **Medial Strabismus** (cross-eyed).

B. **Trochlear** nerve (IV) - damage results in **inability to turn eye down and out;**
ALSO Head Tilt: at rest, **patient tilts head to opposite side (compensate for unilateral eye rotation)**

C. **Oculomotor** nerve (III) - damage causes **ptosis (drooping eyelid** from paralysis of skeletal component of Levator palpebrae superioris), **Lateral Strabismus** (wall-eyed, from damage to Medial rectus), **dilated pupil** (from paralysis of Constrictor pupillae) and **diplopia** (double vision)

VIII. **CILIARY GANGLION** - parasympathetic ganglion of Oculomotor nerve (III)

A. Contains - parasympathetics for Ciliary muscles and Sphincter Pupillae; parasympathetics travel in Short Ciliary nerves.

B. Nerves passing to back of eye (in addition to Optic Nerve)

1. Short Ciliary nerves - parasympathetics from III to Ciliary muscles and constrictor pupillae

2. Long ciliary nerves - sensory branches of Ophthalmic division (V1) of Trigeminal nerve which innervate cornea.

Clinical: 'Blown' Pupil = Pupil Dilated (Mydriasis) - pupil unable to constrict in response to light; indicates catastrophe (stroke, herniation, etc.);

Clinical: Anisocoria – pupils of unequal size (can be normal or abnormal)

SUMMARY OF NERVE DAMAGE TO EYE/ORBIT/EYE MUSCLES

Nerve	Structures damaged	Symptoms
II (Optic Nerve) (Complete cut or block at Optic Foramen)	Denervate whole retina in one eye	Blind in One Eye
III (Oculomotor Nerve)	1) Eye muscles (Medial Rectus, Superior Rectus, Inferior Oblique) 2) Pupillary constrictor muscle (smooth muscle, parasympathetic) 3) Levator Palpebrae Superioris muscle - skeletal muscle part (normally acts to raise upper eyelid)	1) Upper eyelid droops (Ptosis) 2) Lateral Strabismus (wall-eye) 3) Pupil Dilated (mydriasis)
IV (Trochlear Nerve)	Superior Oblique muscle	1) Unable to look Down and Out 2) Head tilted to <u>Opposite Side</u> (away from side of lesion)
VI (Abducens)	Lateral Rectus muscle	Medial Strabismus (cross-eyed)
Sympathetics to eye	1) Pupillary dilator muscle (smooth muscle, sympathetic) 2) Levator Palpebrae Superioris muscle - smooth muscle part (normally acts to raise upper eyelid)	1) Upper eyelid droops (Ptosis) 2) Pupil constricted (meiosis)

Note: Ptosis - is pronounced Tosis (p is silent)

Mydriasis - is pronounced my-dry-asis

Meiosis - is pronounce my-oh-sis