ORIENTING TO BISECTED SPECIMENS ON THE PELVIS PRACTICAL

The Pelvis is just about as complicated as head and neck and considerably more mysterious. You have to be able to visualize (imagine) the underlying structures when looking at the dissections or prosections. This review will first go through some of these structures in a kind of reverse dissection to appreciate the view in bisected specimens.

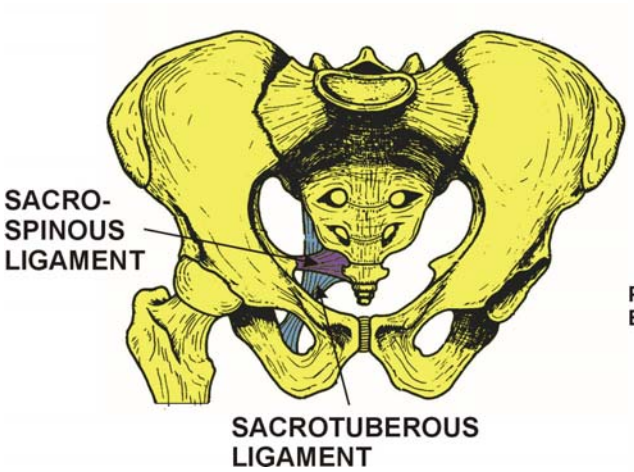

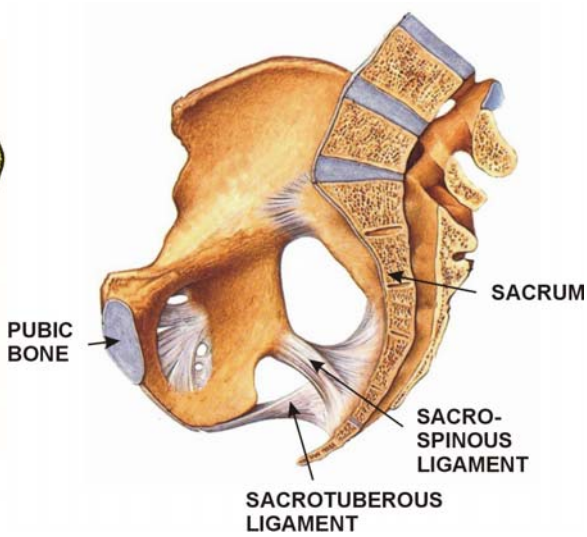

The Sacrotuberous and Sacrospinous ligaments are the most important landmarks for orientation. They are easy to see on the skeleton. However, the ligaments are really deep in a medial view of a bisected pelvis (diagram at right). The Sacrospinous ligament attaches to the Ischial spine, the Sacrotuberous ligament to the Ischial tuberosity. The ligaments form the margins for the Greater and Lesser Sciatic Foramina through which many structures will leave the pelvis (see list below).

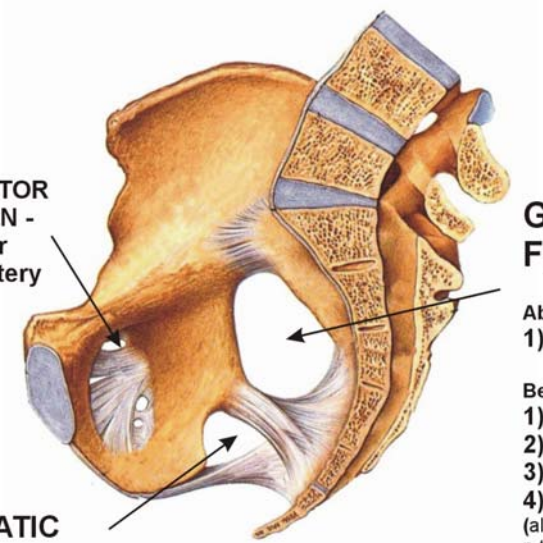

Two important muscles have tendons that leave by the foramina. The Piriformis leaves by the Greater Sciatic Foramen. The Obturator Internus tendon leaves via the Lesser Sciatic Foramen. (Note tilted orientation of diagram below). .

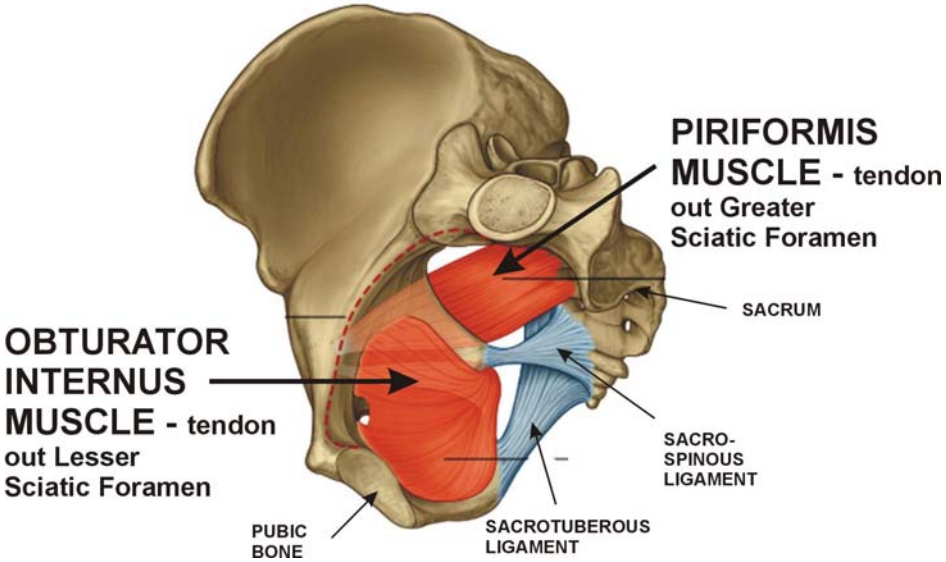

The muscular floor of the Pelvis is formed by the Pelvic Diaphragm (Levator ani and Coccygeus, diagram below). The Levator ani attaches anteriorly to the pubic bone, to a **tendinous arch (inscription)** on the **inner side of the Obturator Internus muscle and posteriorly the to ischial spine**. The **Puborectalis** is part of the Levator that forms a sphincter around the anorectal junction (often asked). The posterior part of the diaphragm is formed by the **Coccygeus** muscle which can be identified by its **attachments to the sacrum and coccyx**.

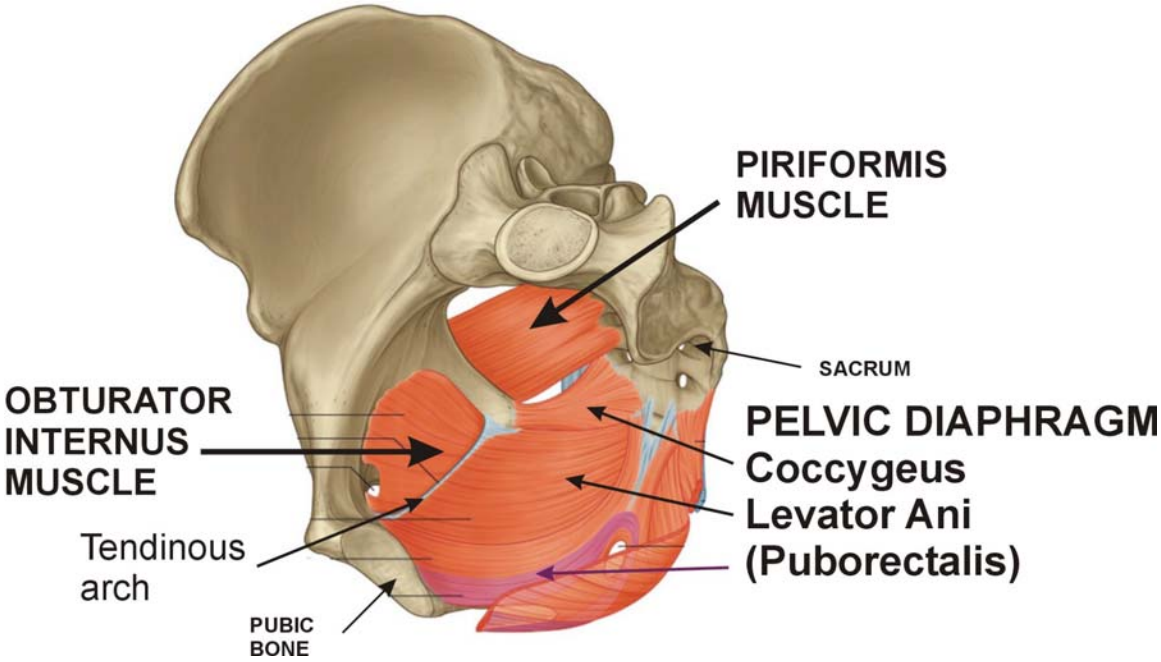

These structures are deep in dissected specimens but you can get orientation from the arteries and nerves. The diagram below is now a strictly sagittal view. Look first for the pubic bone and sacrum. It is easy to see the **Internal and External Iliac arteries** bifurcating from the Common Iliac. You can identify the **level of the Inguinal ligament** (and potentially structures entering the Inguinal canal) by **following the External Iliac**. Follow down the Internal Iliac and you should first see the Posterior division giving rise to the **Superior Gluteal artery** (as well as the Iliolumbar and Lateral Sacral not labeled). The Superior Gluteal is the largest branch and it passes into the Greater Sciatic foramen above the piriformis. You can also see the **Sacral Spinal nerves** joining the Lumbosacral trunk to form the Sciatic nerve inferior to the Piriformis.

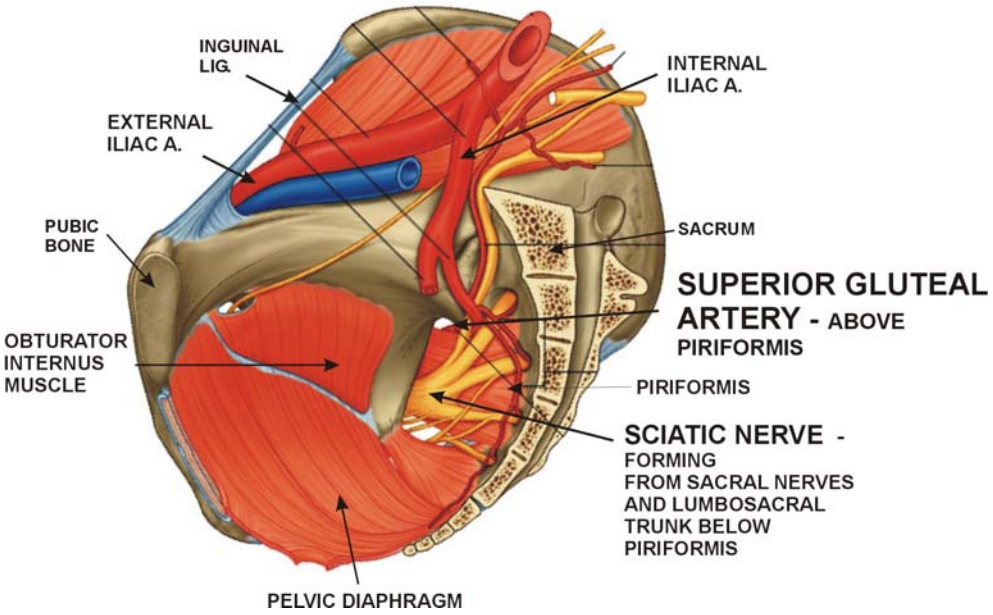

Now we can add back the Viscera (below) to the reverse dissection. posterior to the pubic bone is the urinary bladder. In females, the Uterus and Vagina are posterior to the bladder and the Rectum is posterior to the Vagina. The **Rectouterine pouch** (lowest point in female pelvis) can be accessed through the Posterior Fornix of the Vagina. The **Perineal body** is located between the Vagina and the Rectum. In males, there is no Uterus and the perineal body is identified as the point anterior to the Rectum.

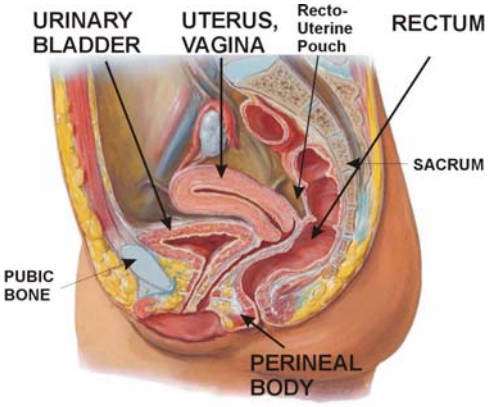

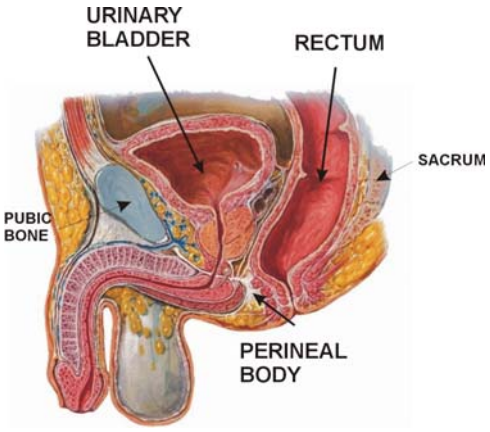

Now look at the dissected specimens.

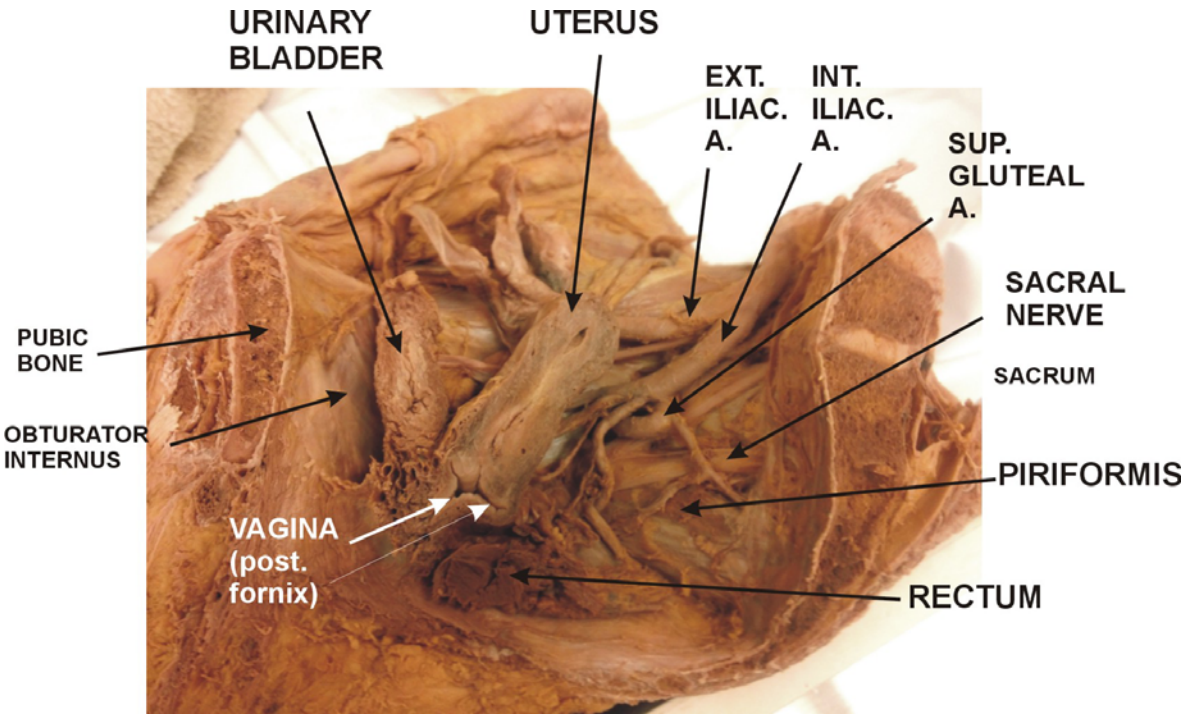

For orientation, first look for **pubic bone** and the **sacrum**. Then figure out if it is a male or a female by identification of the internal organs. Then find and trace the External and Internal Iliac arteries. Following down the Internal Iliac you can identify the **Superior Gluteal artery** which should disappear above the Piriformis. Look for the **Sacral spinal nerves** overlying Piriformis muscle.

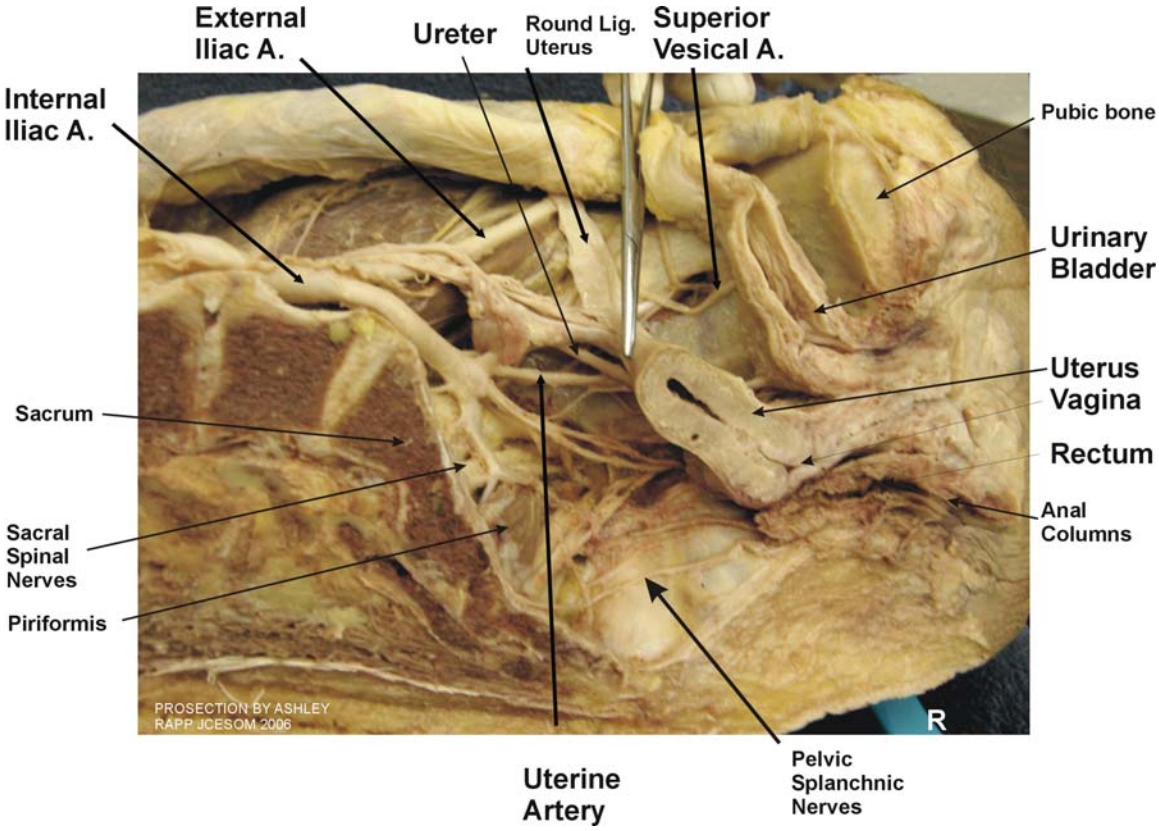

You can see other branches of the Internal Iliac on the picture above from the prosection that was done by Ashley Rapp Parker (class of 2009, not 2006, and now a Surgeon). Again orient to the sacrum and pubic bone. Find the Urinary bladder, Uterus, Rectum and follow the Iliac arteries. The anterior division of the Internal Iliac artery gives rise to a number of branches that are identified by following them to the structures they supply. Look for the branch that is going to the upper part of the Urinary bladder. It is the **Superior Vesical artery**. It can have something branching from it (not shown in this picture): it is the **Median Umbilical ligament** that represents the **fetal Umbilical artery**. Then look for **Uterine artery**. it courses toward the body of the Uterus but importantly **crosses over (superior to) the Ureter** (which looks like it is coming from the pelvis and heading toward the bladder). In this picture you can also see the **Round ligament of the Uterus** which looks like it is disappear next to the External Iliac (it is entering the Inguinal Canal). Last, you can see the **Pelvic Splanchnic nerves**. They look like strings coming from the other nerves but ending in the back of the Pelvic viscera.