

# **PROSECTIONS OF SPINAL CORD AND VERTEBRAE**

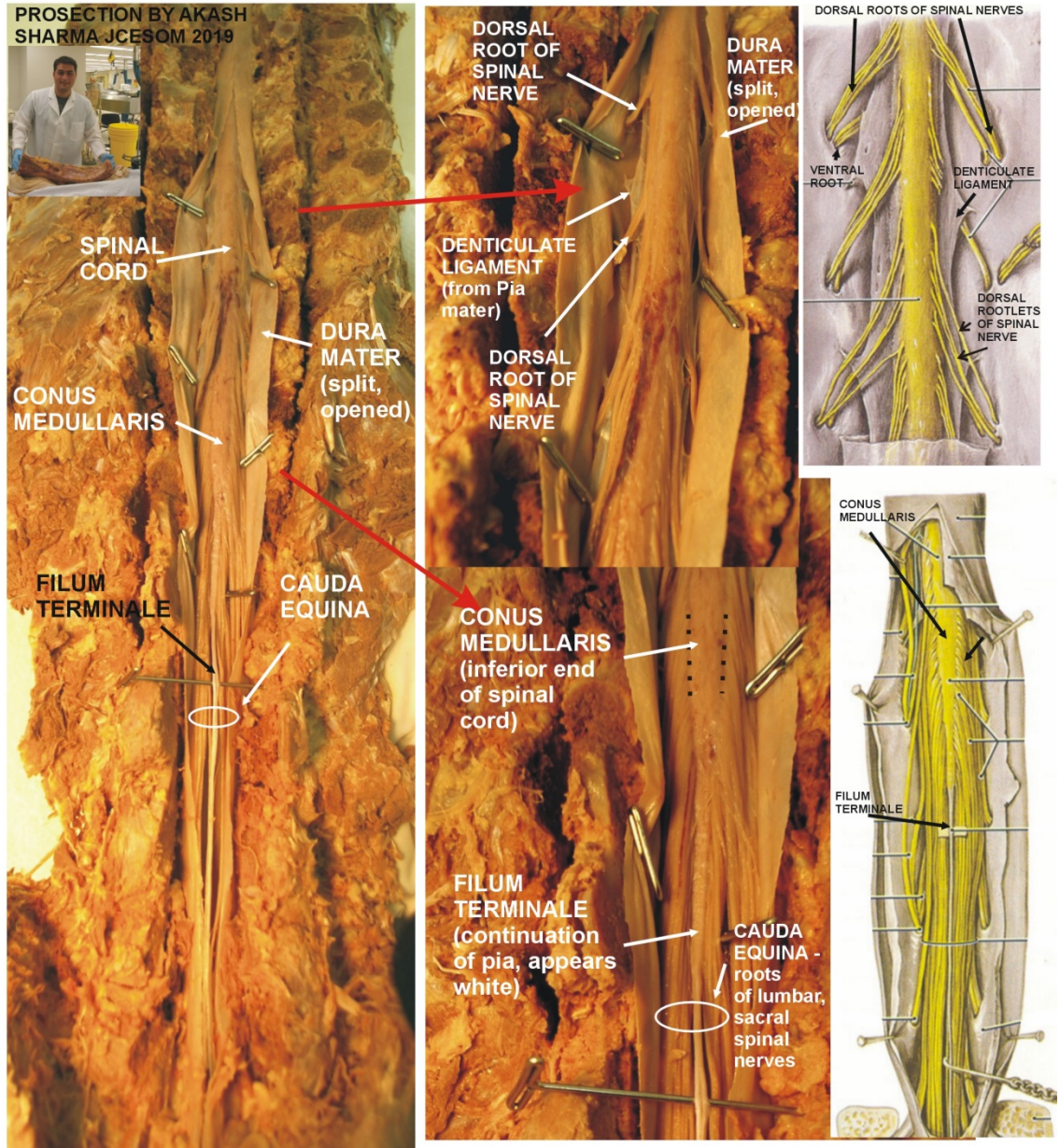
**2021**

# SPINAL CORD

44

PROSECTION PICTURES:  
SPINAL CORD AND  
MENINGES

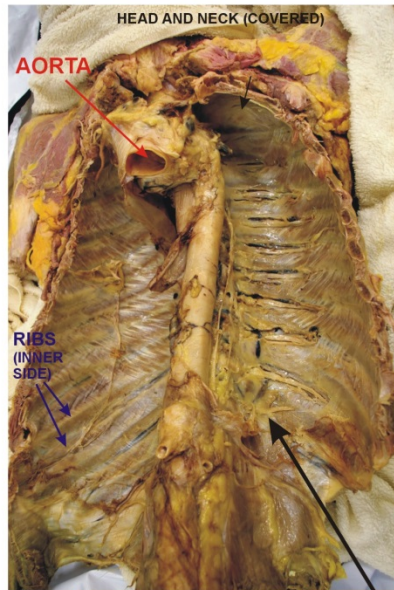
PROSECTION  
44



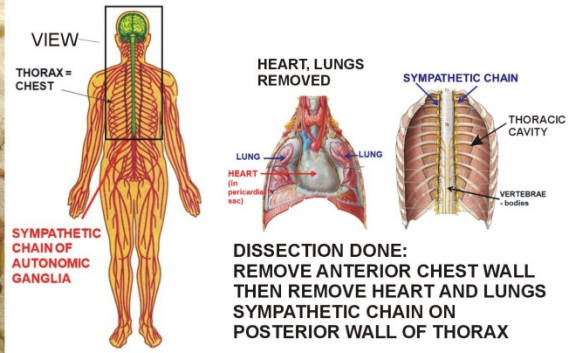
# SYMPATHETIC CHAIN AND SPINAL NERVES IN THORAX

80

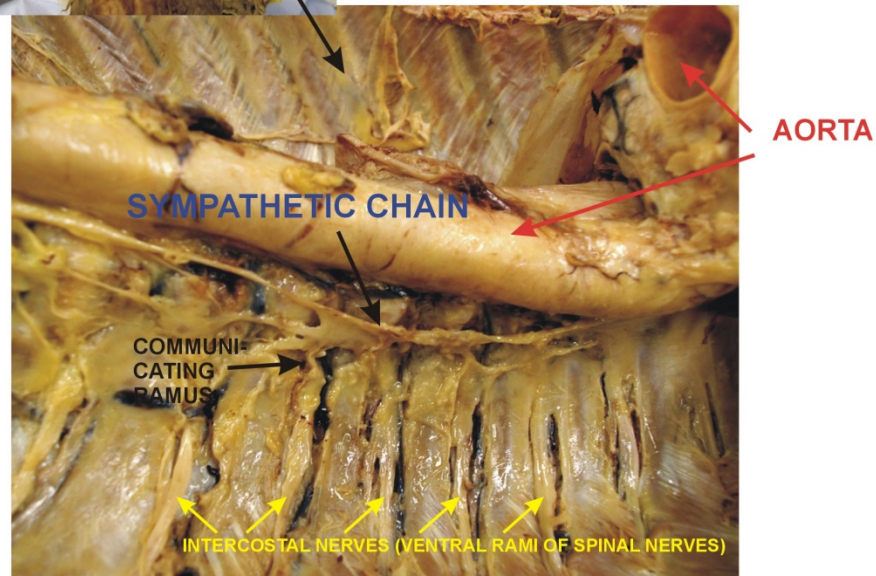
## PROSECTION 80 SYMPATHETIC CHAIN IN THORAX



WHAT IS THIS?  
ORIENT - ISOLATED THORAX (HEAD NECK STILL ATTACHED, UNDER SHEET); HEART, LUNGS REMOVED; LOOKING AT POSTERIOR WALL OF MOSTLY EMPTY THORACIC CAVITY



VIEW BELOW: LEFT SIDE OF SPECIMEN (TILT)

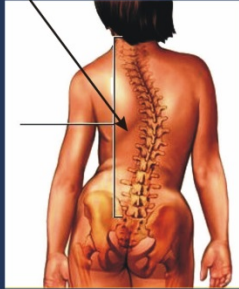




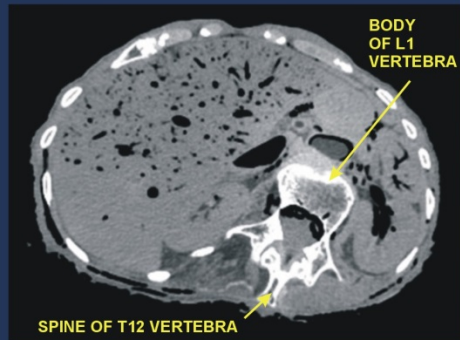
# SCOLIOSIS

138

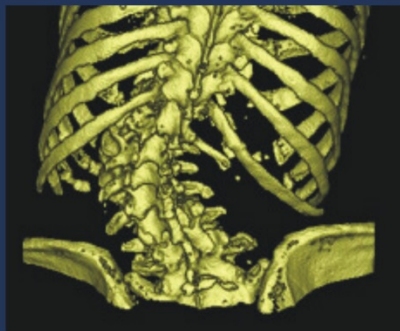
ABNORMAL LATERAL CURVATURE OF SPINE



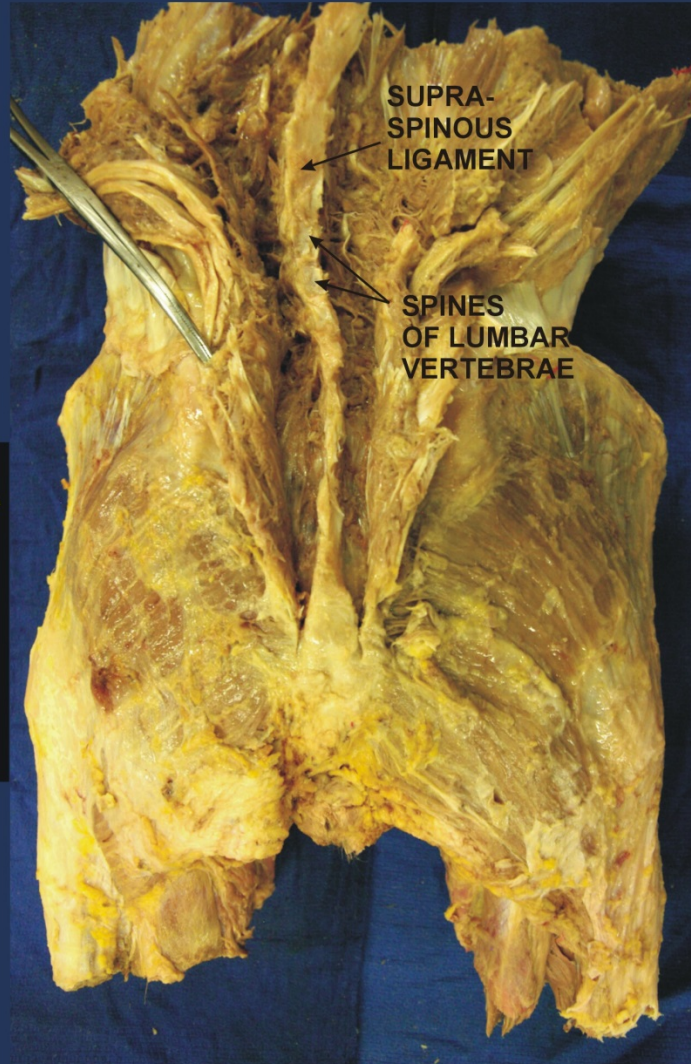CT OF THIS SPECIMEN



NOTE: ABNORMAL POSITION OF VERTEBRA



3D RECONSTRUCTION FROM CT SERIES



CLINICAL - THIS WAS AN ELDERLY FEMALE. THE VERTEBRAE SHOWED TORSION AS WELL AS LATERAL DEVIATION. THERE WAS NO EVIDENCE OF A HEMI-VERTEBRA.

PROSECTION  
138  
SCOLIOSIS  
IN LUMBAR  
VERTEBRA  
(WITH CT IMAGE  
OF CADAVER AND  
3D  
RECONSTRUCTION  
OF SKELETON)

## NOTE: PROSECTON PROCEDURE: LAMINECTOMY

