REVIEW OF LOWER EXTREMITY

I. OVERVIEW - UPPER AND LOWER EXTREMITY ROTATION, DERMATOME MAP, REFLEXES

II. REGIONS - HIP, KNEE, ANKLE, FOOT

DEVELOPMENT OF EXTREMITIES: ROTATION

CLAPPING BABY'S HANDS AND FEET

Arms and legs initially have same orientation, perpendicular to spinal column (think of a baby sitting - palms touch, soles of feet touch).

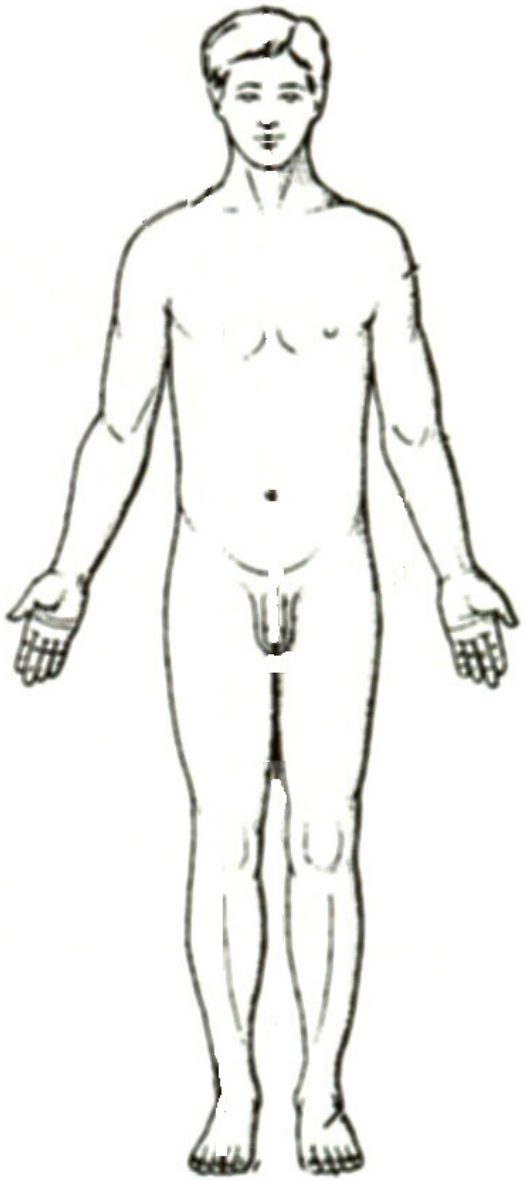

upper extremity rotates laterally

THUMB IS LATERAL

lower extremity rotates medially

BIG TOE IS MEDIAL

MOVEMENTS OF LOWER LIMB

Hip joint - ball and socket
Flexion - Anterior
Extension - Posterior
Adduction - Medial
Abduction - Lateral
Rotation - movement about long axis of femur

Knee joint - condylar joint
Flexion - Posterior
Extension - Anterior
Rotation (small) - movement about long axis of leg (tibia)

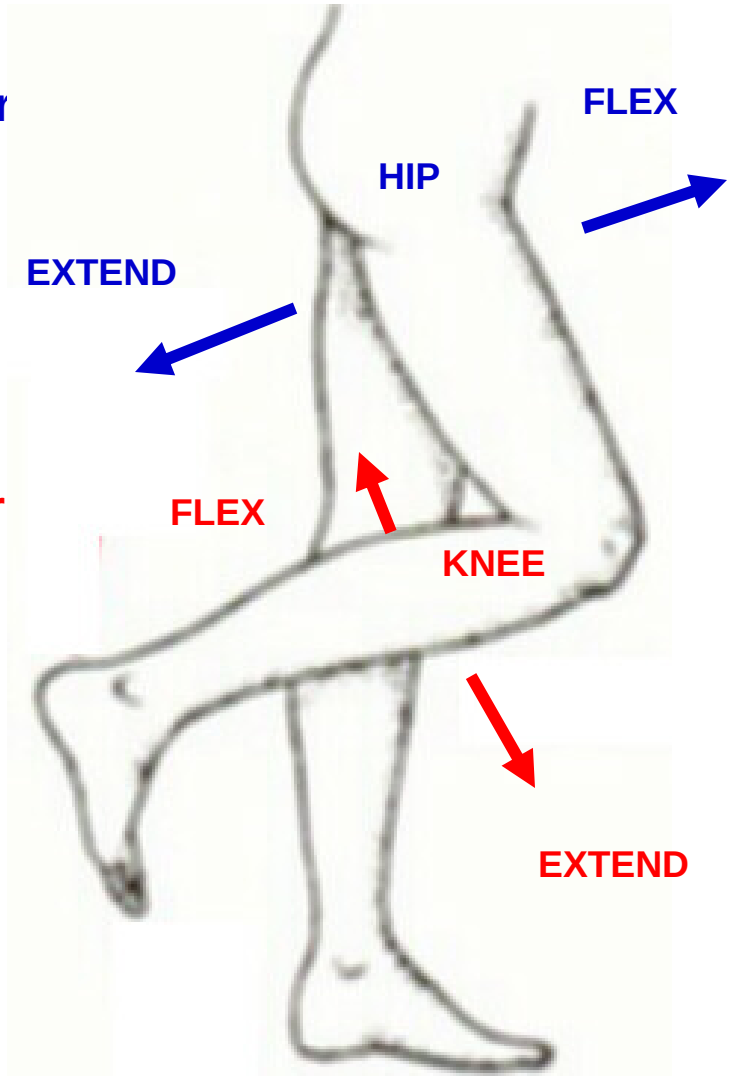

Ankle and Foot

Inversion - sole faces medially

Eversion - sole faces laterally

DERMATOME MAP IN ADULT - REFLECT ROTATION

DERMATOMES OF LOWER EXTREMIY

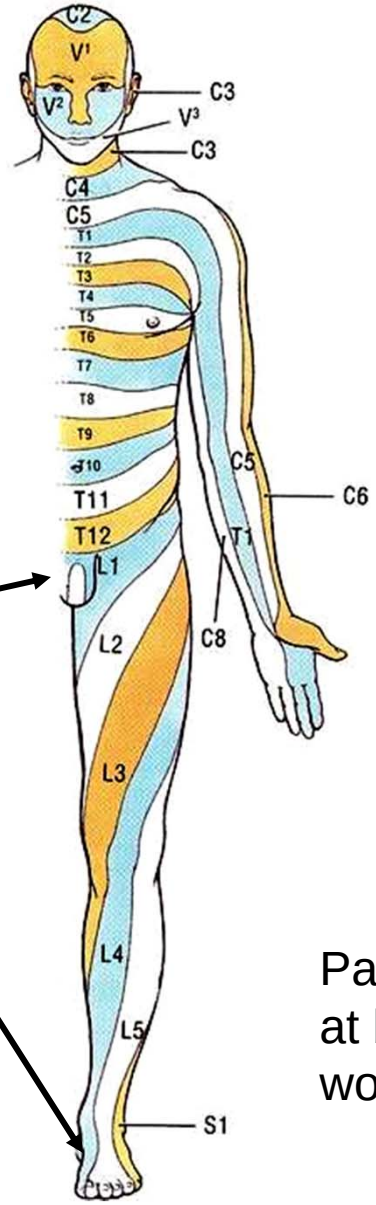

L1- inguinal ligament
L3, L4 - anterior knee (patella)
L4 - medial side of foot, big toe
S1 - lateral side of foot
S1, S2 - posterior side of leg and thigh

Hand - higher spinal levels lateral

C6 thumb lateral
C8 little finger medial

Foot - higher spinal levels medial

L4 big toe medial
S1 little toe lateral

Patient: Complete lack of sensation at big toe. Which spinal nerve would be compressed? L4

STRETCH (TENDON TAP) REFLEXES OF LOWER EXTREMITY

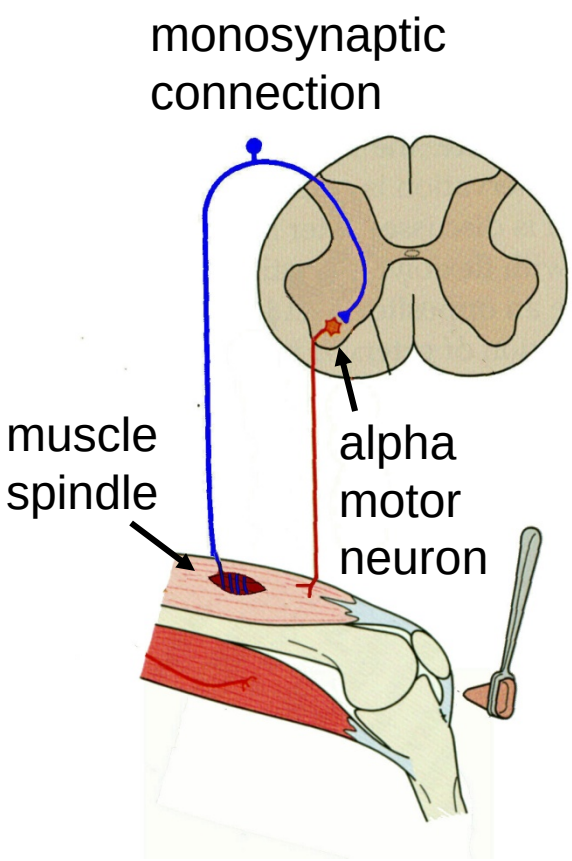

KNEE JERK - QUADRICEPS MUSCLE

L3, L4

ANKLE JERK - GASTROCNEMIUS MUSCLE

S1

TENDON TAP (STRETCH OR DEEP TENDON) REFLEXES - TEST SPINAL LEVEL

CLINICAL - Patient has numbness of skin overlying little toe. Ankle jerk reflexes reduced. What spinal level affected? S1

OVERVIEW OF ARTERIAL SUPPLY: COURSE REFLECTS ROTATION

HIP (ANTERIOR VIEW)

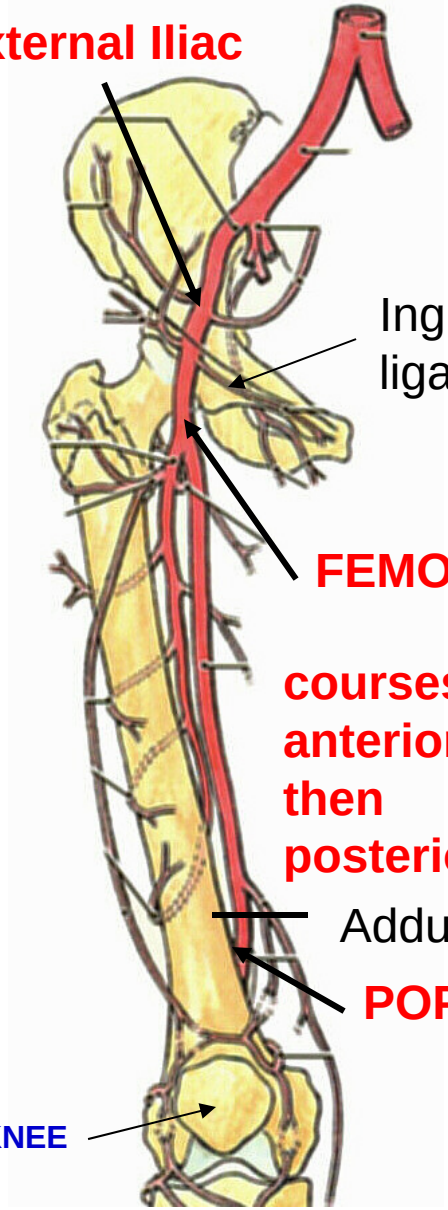

LEG AND FOOT

POST. VIEW

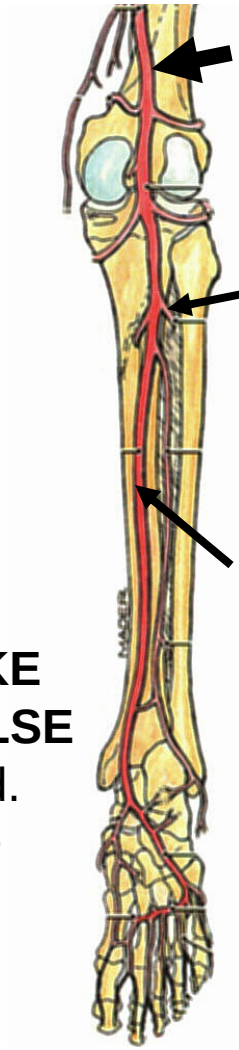

ANT. VIEW

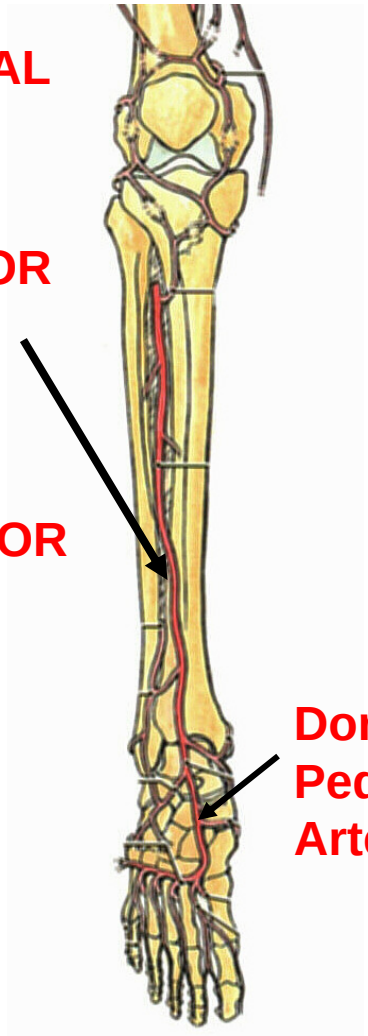

TAKE PULSE med. side

HIP: FEMORAL HERNIA

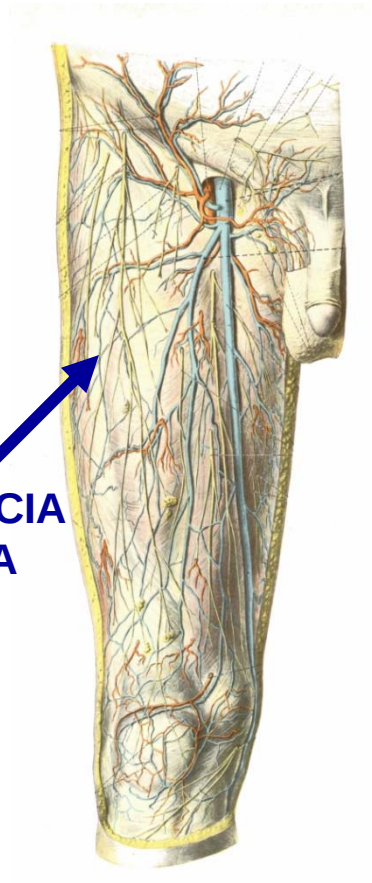

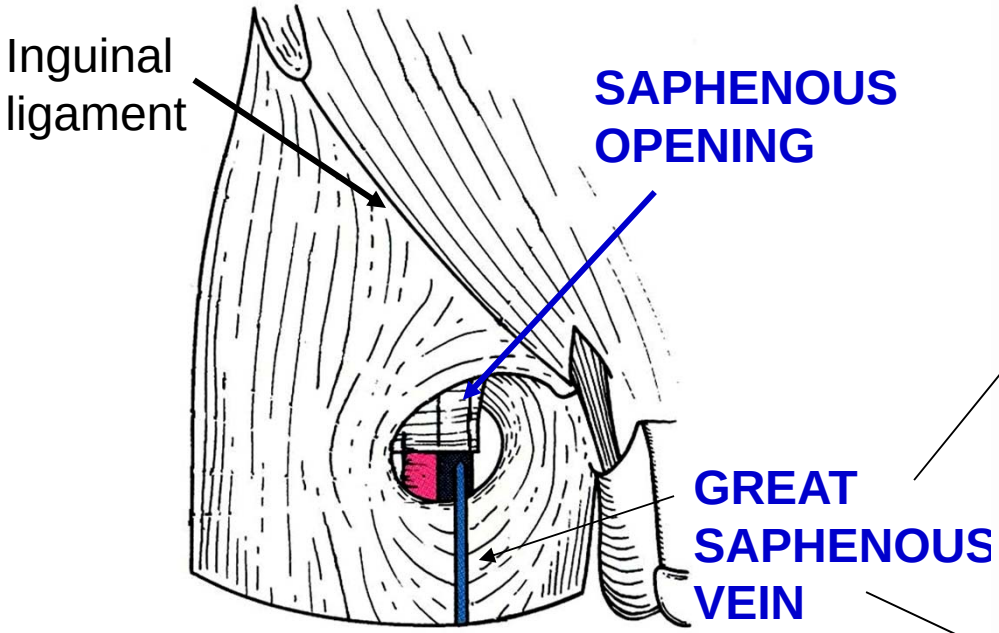

FASCIA LATA- deep fascia of thigh is thick; superiorly attached to the pelvis, Scarpa's fascia and the inguinal ligament.

Saphenous opening - allows for passage of Great Saphenous vein; located inferior to inguinal ligament, anterior to Femoral artery and vein

GREAT SAPHENOUS VEIN courses on medial side of leg (SMALL SAPHENOUS VEIN is on post side of leg)

FEMORAL TRIANGLE

LATERAL - SARTORIUS

SUPERIOR - INGUINAL LIGAMENT

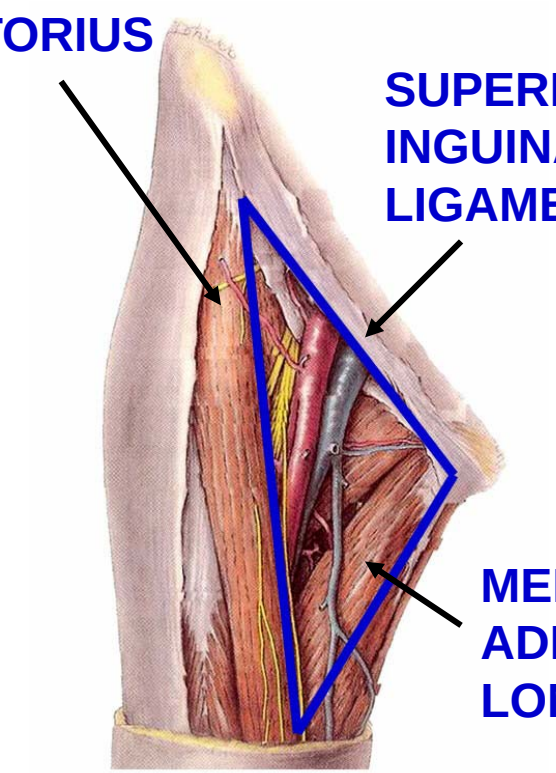

MEDIAL - ADDUCTOR LONGUS

CONTAINS - LATERAL TO MEDIAL
<u>FEMORAL</u> NERVE, ARTERY
VEIN, LYMPHATICS -

REMEMBER **NAVL**

FEMORAL SHEATH

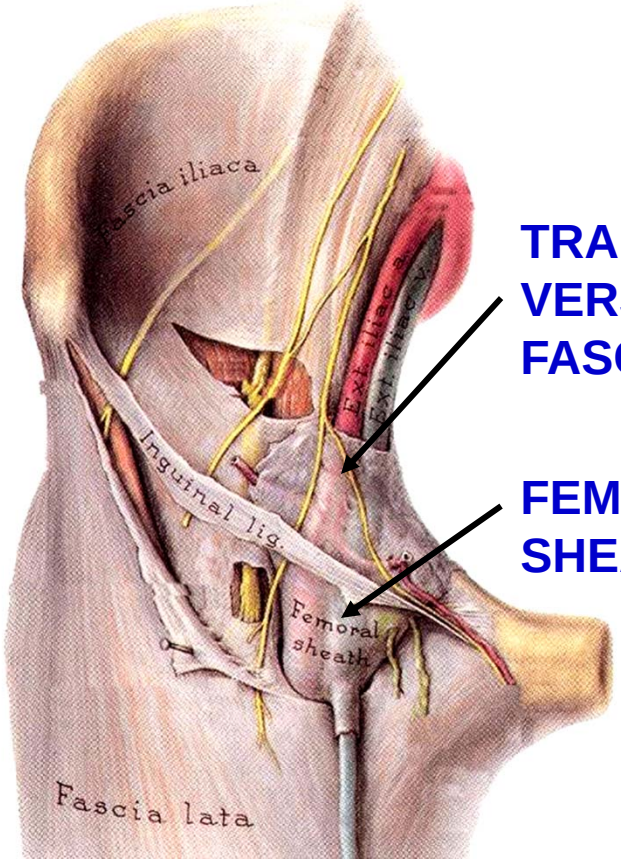

TRANS-VERSALIS FASCIA

FEMORAL SHEATH

- SHEATH IS CONTINUATION OF TRANSVERSALIS FASCIA OF ABDOMEN
- SURROUNDS ARTERY, VEIN, LYMPHATICS NOT NERVE

FEMORAL CANAL

transversalis fascia

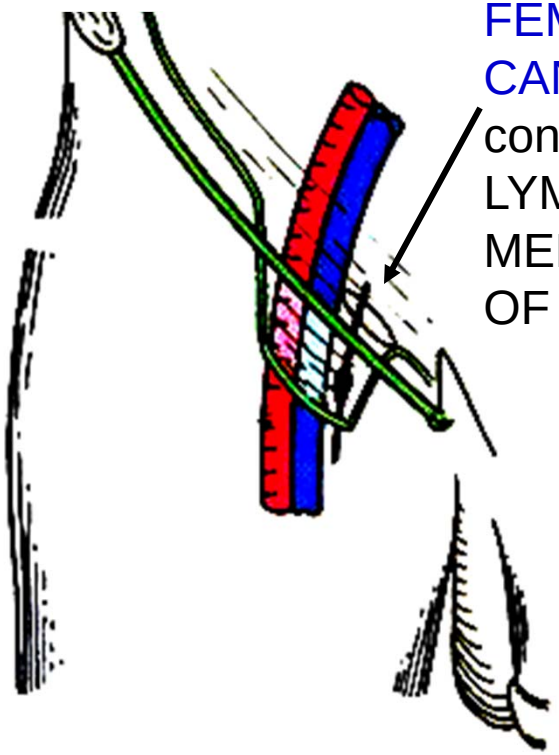

FEMORAL CANAL - contains LYMPHATICS IN MEDIAL PART OF SHEATH

Femoral Canal - is contained in medial part of femoral sheath; contains lymph vessels from lower limb that drain to external iliac nodes ; opening is called **Femoral Ring**.

FEMORAL HERNIA

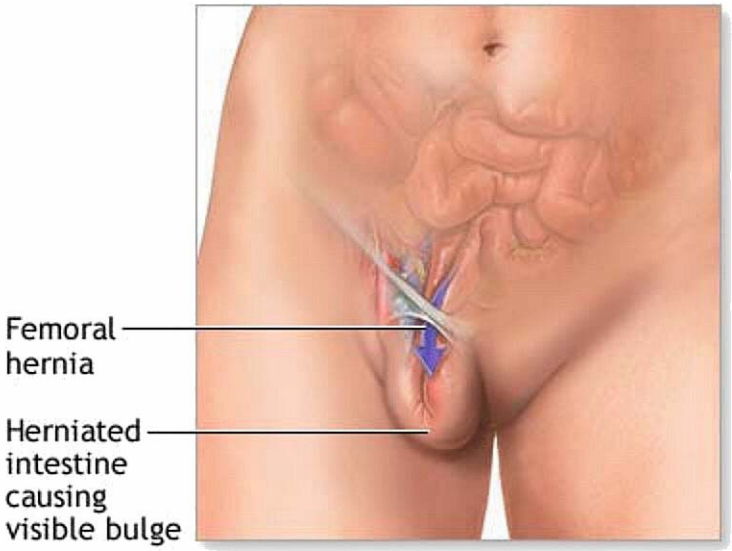

Femoral Hernia - Femoral ring is point of potential weakness of abdomino/pelvic wall; loop of bowel can protrude into Femoral Canal and become strangulate; more common in females (inguinal hernias more common in males).

CLINICAL QUESTION:

Mother of 4 children lifts heavy load and feels bulge on anterior groin or thigh.

CAUSES OF FEMORAL HERNIA:

1) carrying or pushing heavy loads
2) more frequent in older females
3) more common in women who have had one or more pregnancies
4) overweight (obese)
5) cough
6) constipation

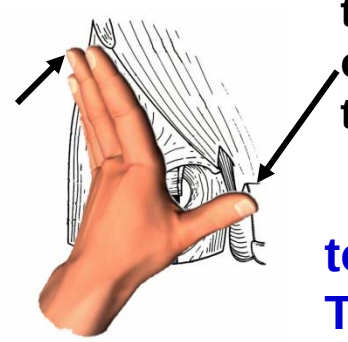

to locate - VEE TECHNIQUE

Differentiating Femoral and Inguinal Hernias - reference is INGUINAL LIGAMENT

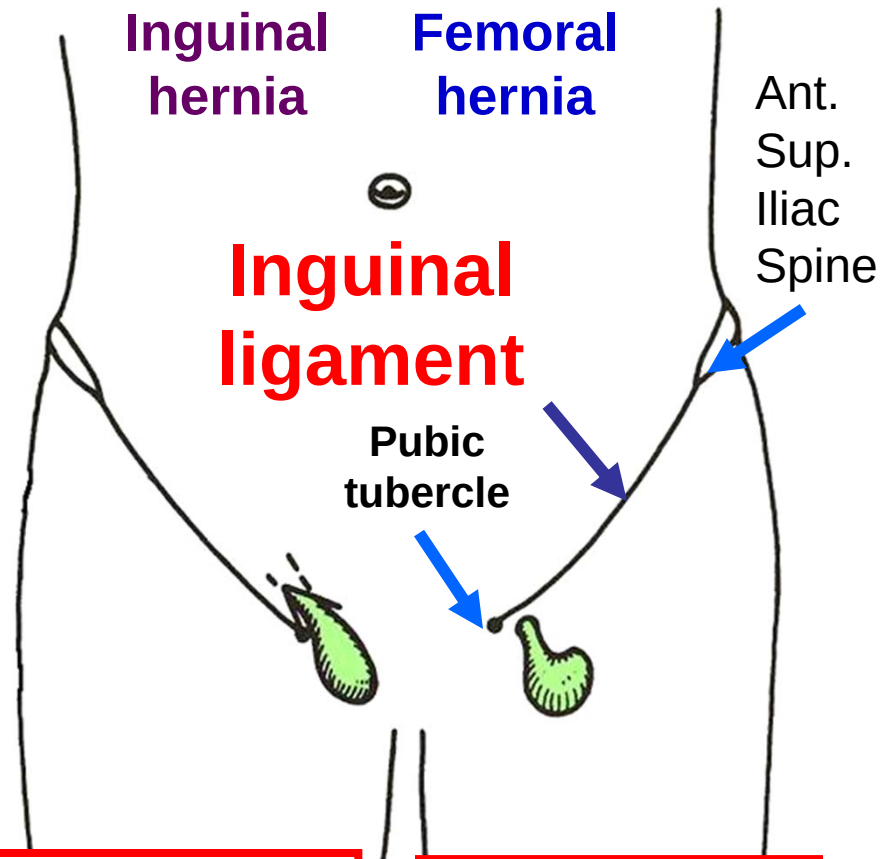

Inguinal Hernia - neck of hernia is ABOVE inguinal ligament.

Femoral Hernia - neck of hernia is BELOW inguinal ligament

ANTERIOR THIGH: 'HIP POINTER'

SARTORIUS -
Origin - Ant. Sup. Iliac Spine
Insert - Tibia

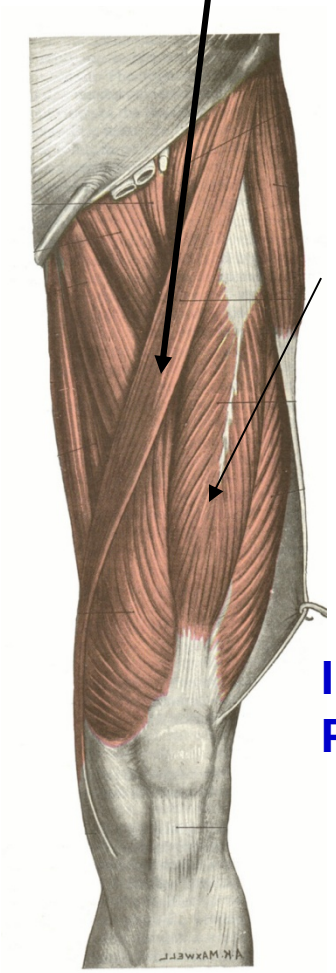

QUADRICEPS FEMORIS -
Insert - to Patella to Tibia

INNERVATION: FEMORAL NERVE

ANT. SUP. ILIAC SPINE

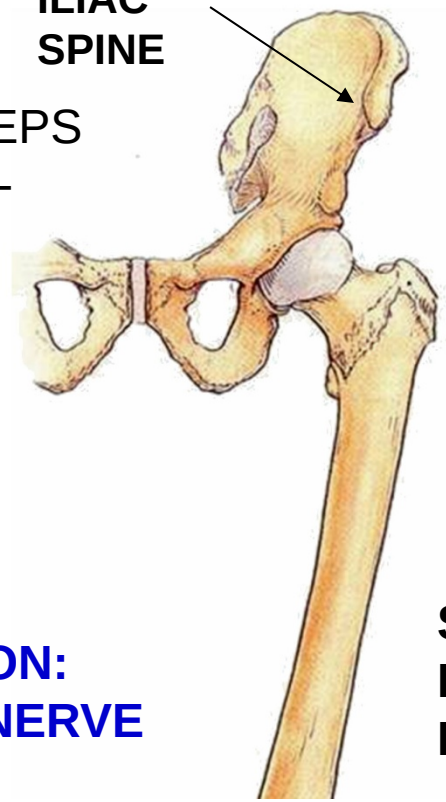

Clinical Note: Contusion of muscles at **Anterior Superior Iliac spine** (origin of Sartorius and Tensor Fascia Lata) is called a **Hip Pointer - Symptom - Bruise on Hip**

SOCCER PLAYER FALL

MUSCLES OF MEDIAL THIGH: PULLED GROIN

Clinical: PULLED GROIN - Tear of Adductor Muscle group at PUBIS; PLAYING SPORTS, INTENSE PAIN IN GROIN, DIFFICULTY WALKING

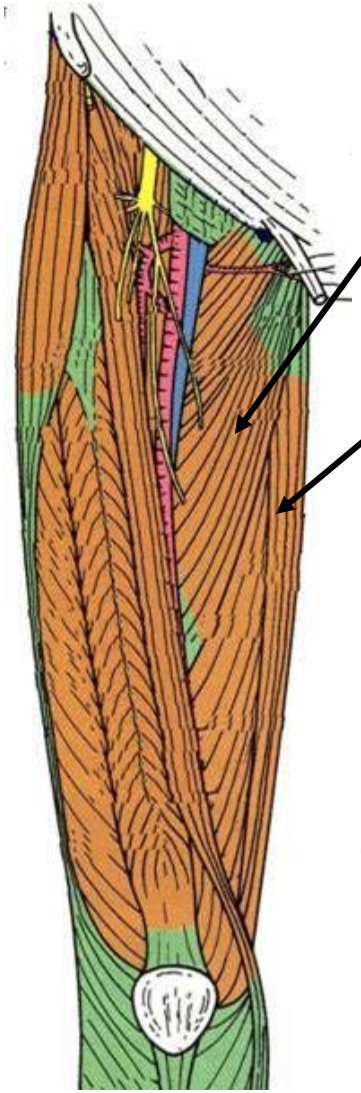

ADDUCTORS:
LONGUS
BREVIS

GRACILIS

ORIGIN:
PUBIS

INNERVATION:
OBTURATOR
NERVE

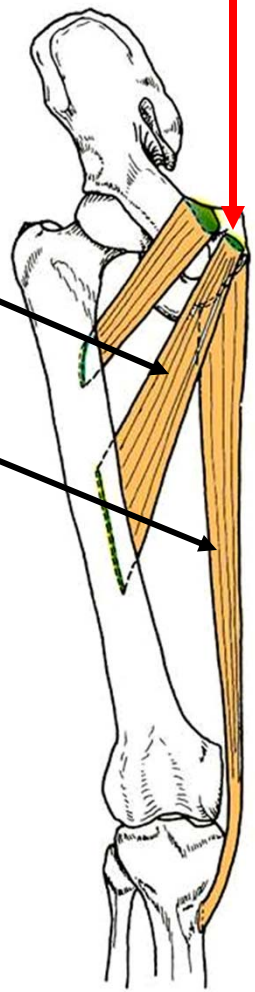

ADDUCTOR
MAGNUS

ORIGIN:
PUBIS,
ISCHIAL
TUBER-
OSITY

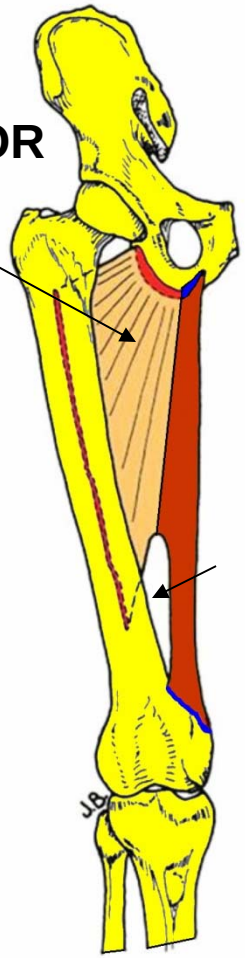

HIATUS -
passage
FEM. A.
AND V.

POSTERIOR THIGH - PULLED HAMSTRINGS

ORIGIN ALL - Ischial Tuberosity

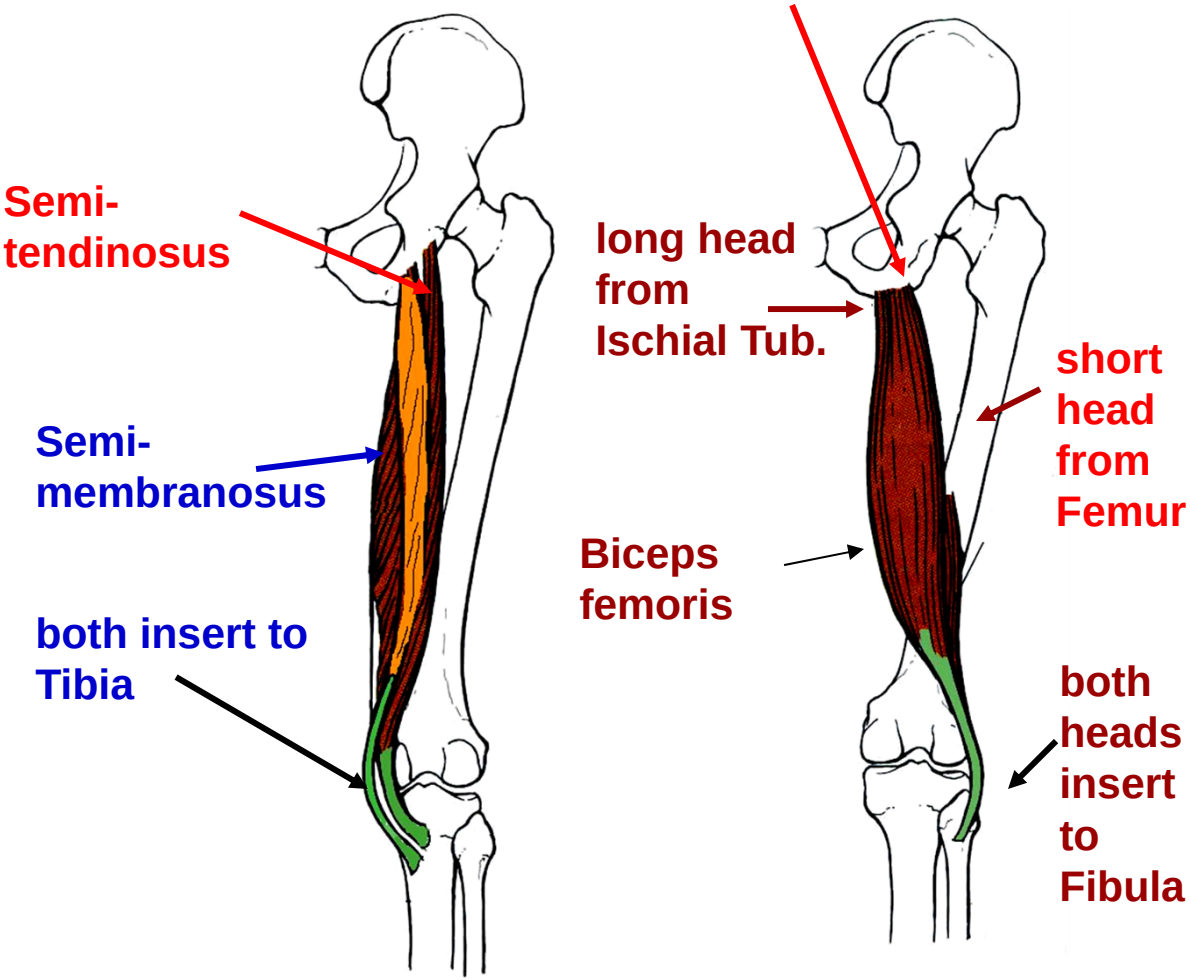

Action - All Extend thigh and flex leg except Biceps Short head only flex leg

PULLED HAMSTRINGS - TEAR MUSCLE OR AVULSE FROM ISCHIAL TUBEROSITY

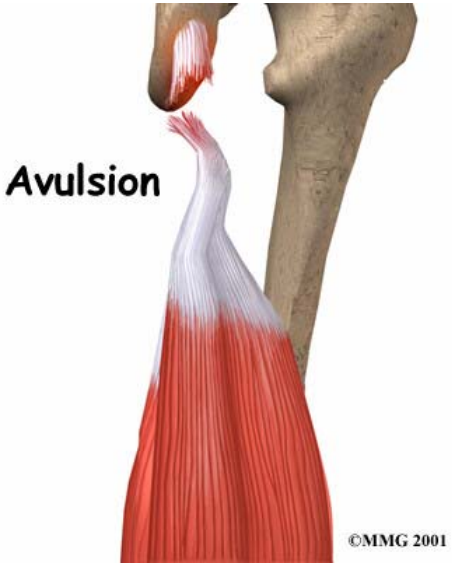

Clinical - ex. Tear when running; sudden excruciating pain in back of thigh

GLUTEAL MUSCLES

ORIGIN - ILIUM

Medius +

Minimus

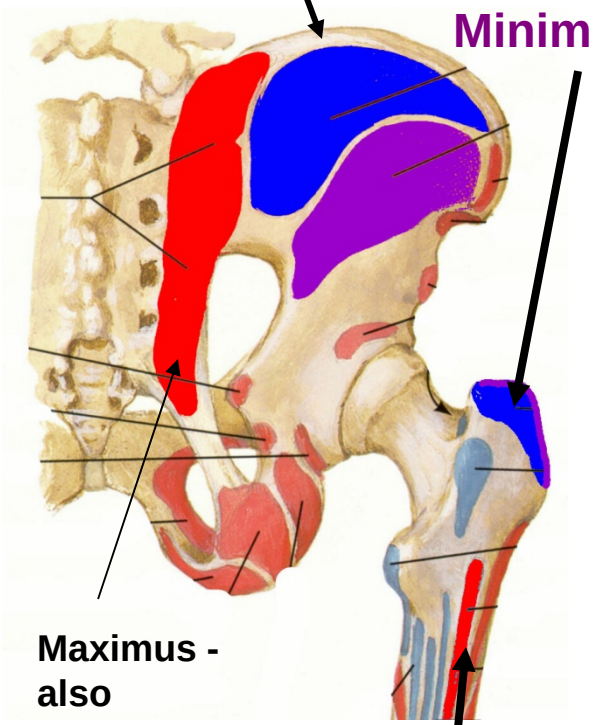

Maximus - also sacrum, coccyx sac.tub.lig

Maximus

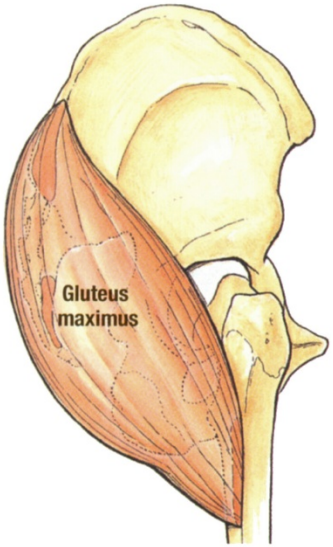

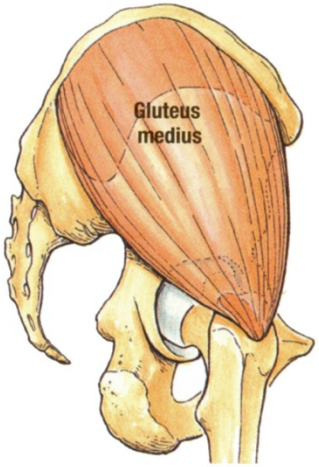

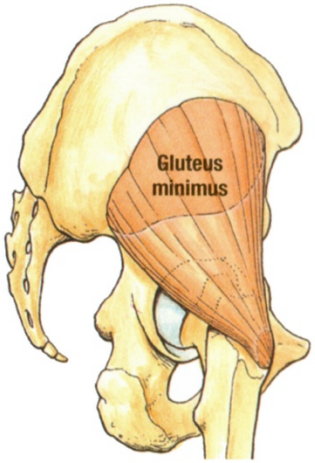

Gluteus Maximus

I - Femur, IT tract
Act - Extend, Laterally rotate

Gluteus Medius

I - Femur (Greater Trochanter)
Act - Abduct, Medially rotate

Gluteus Minimus

I - Femur (Greater Trochanter)
Act - Abduct, Medially rotate

Inn - Inferior Gluteal N.

Inn both - Superior Gluteal N.

GLUTEAL GAIT

Clinical - caused by injury to Superior Gluteal nerve or poliomyelitis (also congenital dislocation of hip joint). Paralyze Gluteus Medius and Minimus. In walking, pelvis tilts down on non-paralyzed side when lift foot of opposite, non-paralyzed leg.

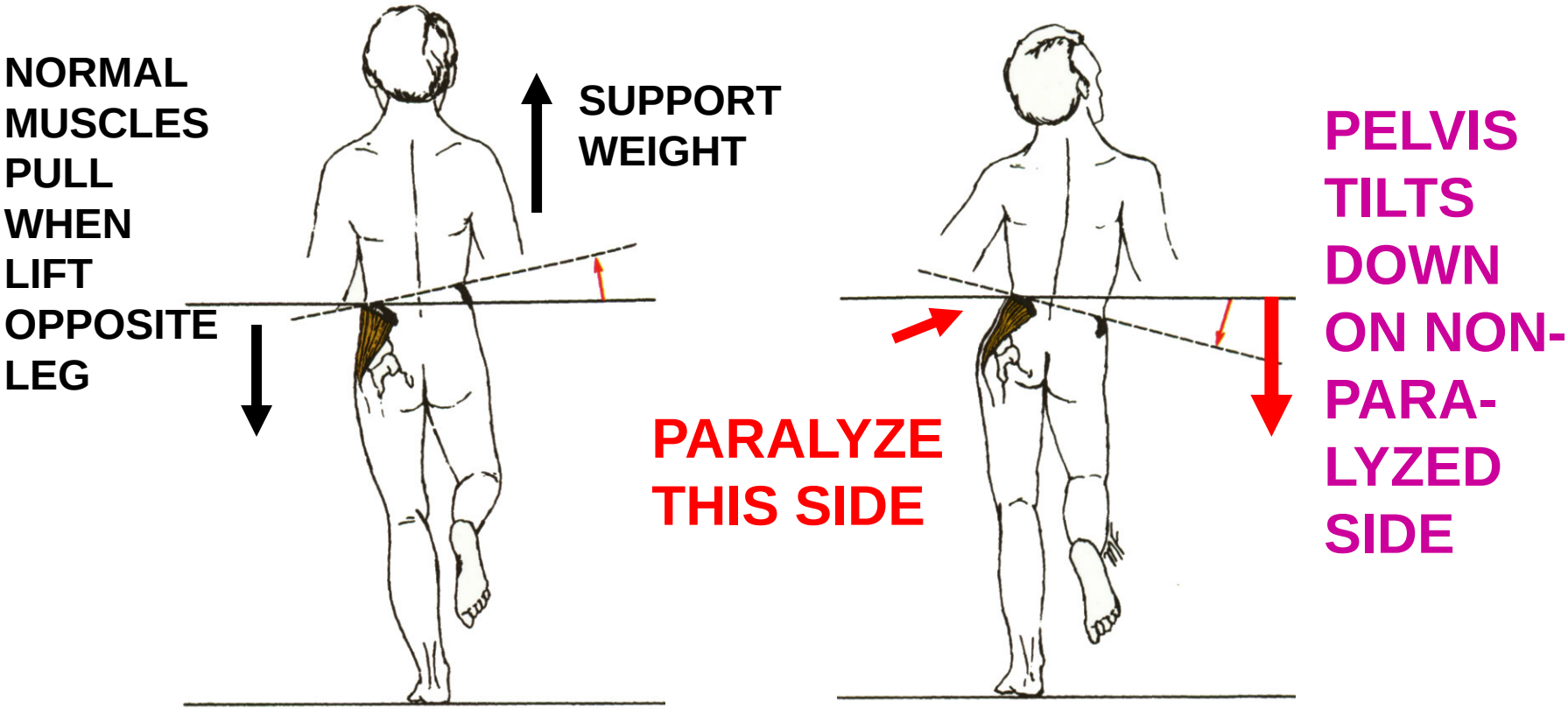

Positive Trendelenburg sign - WHEN LIFT OPPOSITE LEG, PELVIS TILTS DOWN ON (NON-PARALYZED) OPPOSITE SIDE.

FEMORAL ARTERY

Profunda Femoris - largest branch of femoral; branches:

a. Medial Femoral Circumflex - provides most of blood supply to head of femur.

b. Lateral Femoral Circumflex - supplies lateral side of thigh, neck of femur; has **Descending branch** that is part of Genicular anastomosis at knee joint.

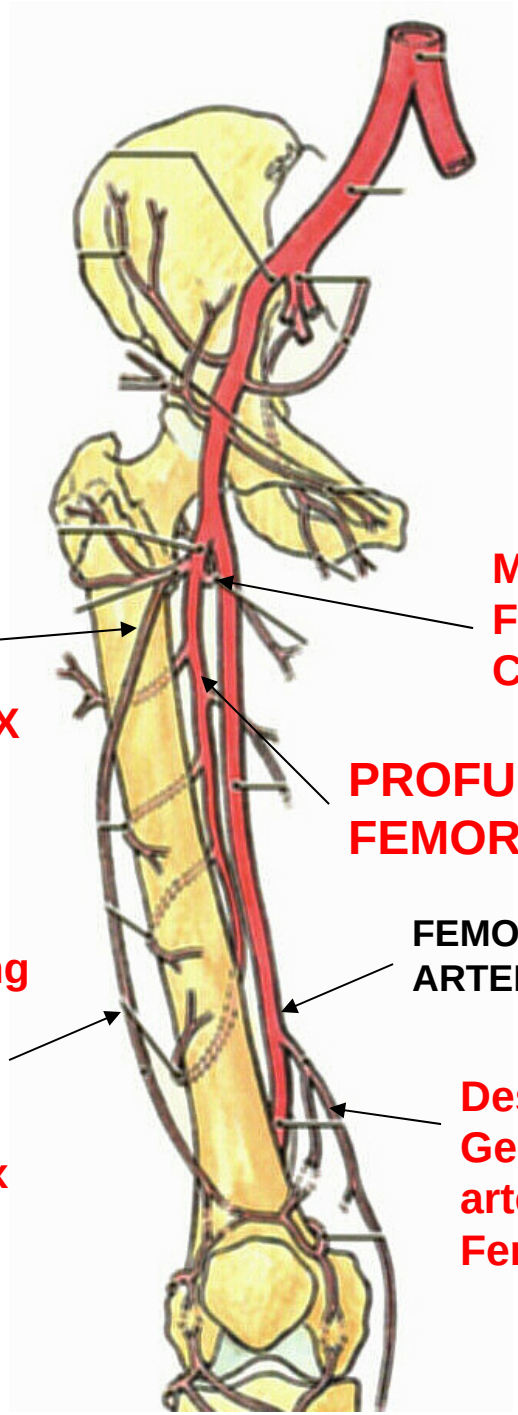

CLINICAL: CRUCIATE ANASTOMOSIS

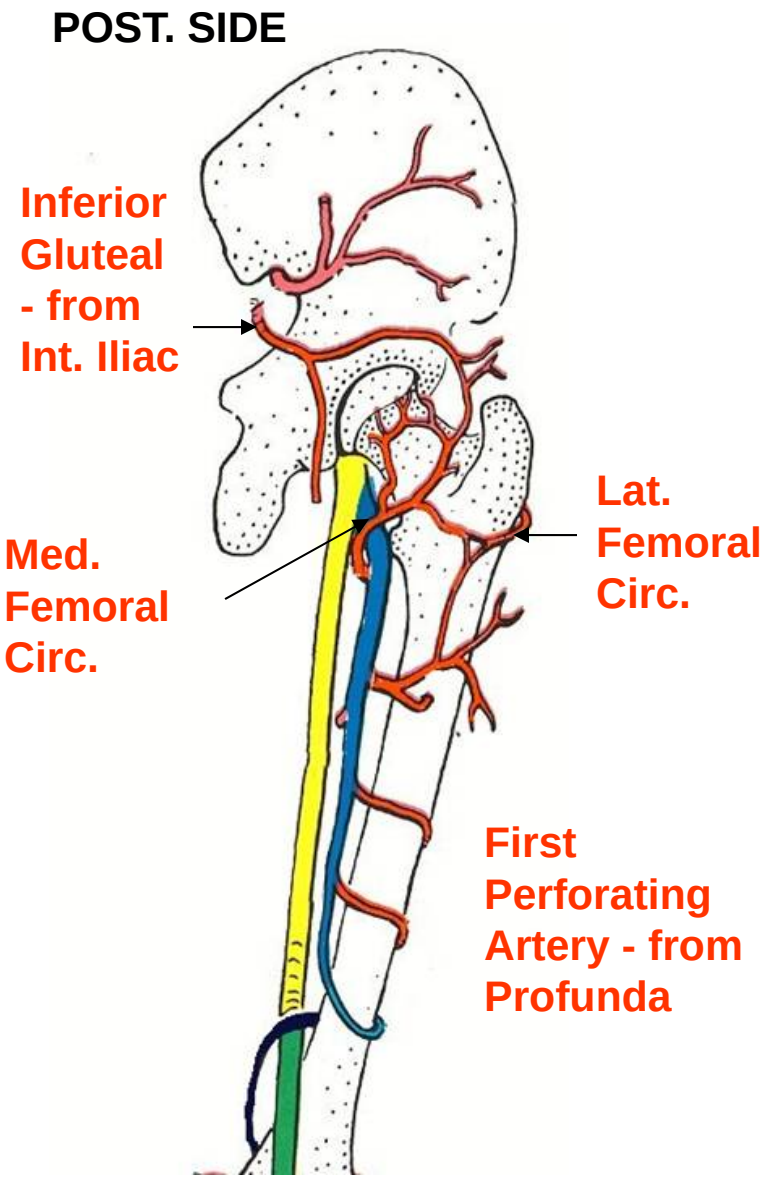

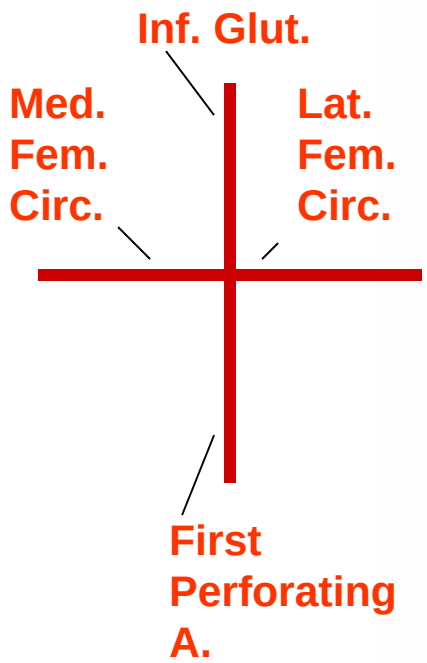

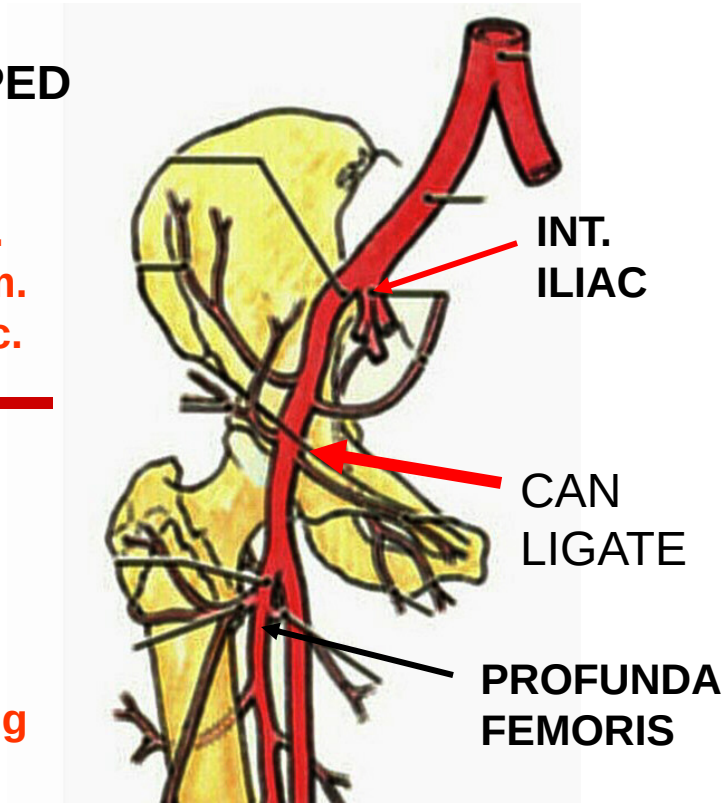

Clinical - Stab wound or bleeding in Femoral Artery
Can: Ligate External Iliac or Femoral between
1) Internal Iliac
2) Profunda femoris

FRACTURE OF NECK OF FEMUR

Note: **Fracture of neck of femur** - common in the elderly; leg is rotated laterally due to action of gluteus maximus and short rotators of hip.

post. view of hip

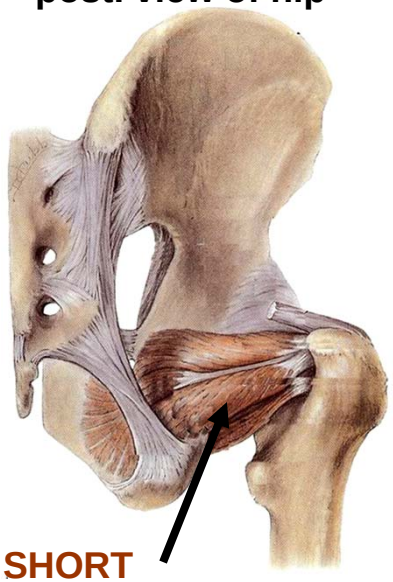

SHORT LATERAL ROTATORS OF HIP

laterally rotate femur

Leg is rotated laterally

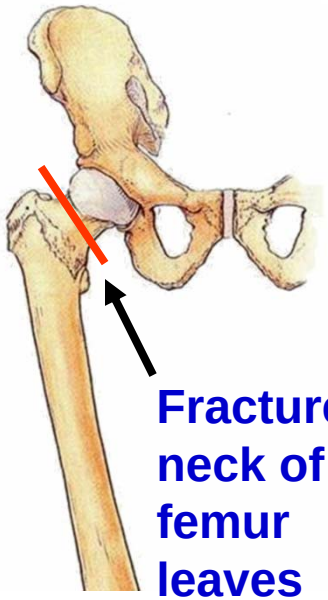

Fracture of neck of femur leaves Greater Trochanter attached to femur

FRACTURE CAN PRODUCE AVASCULAR NECROSIS OF HEAD OF FEMUR

Obturator Artery branches through Ligament of head of femur

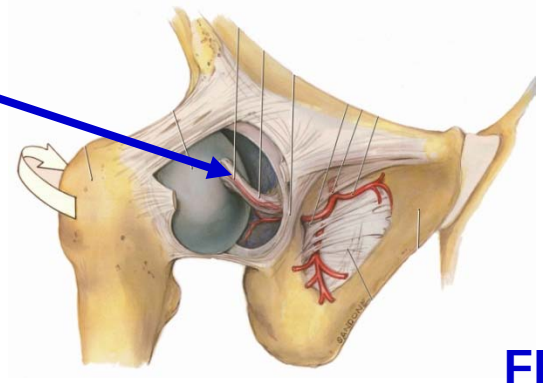

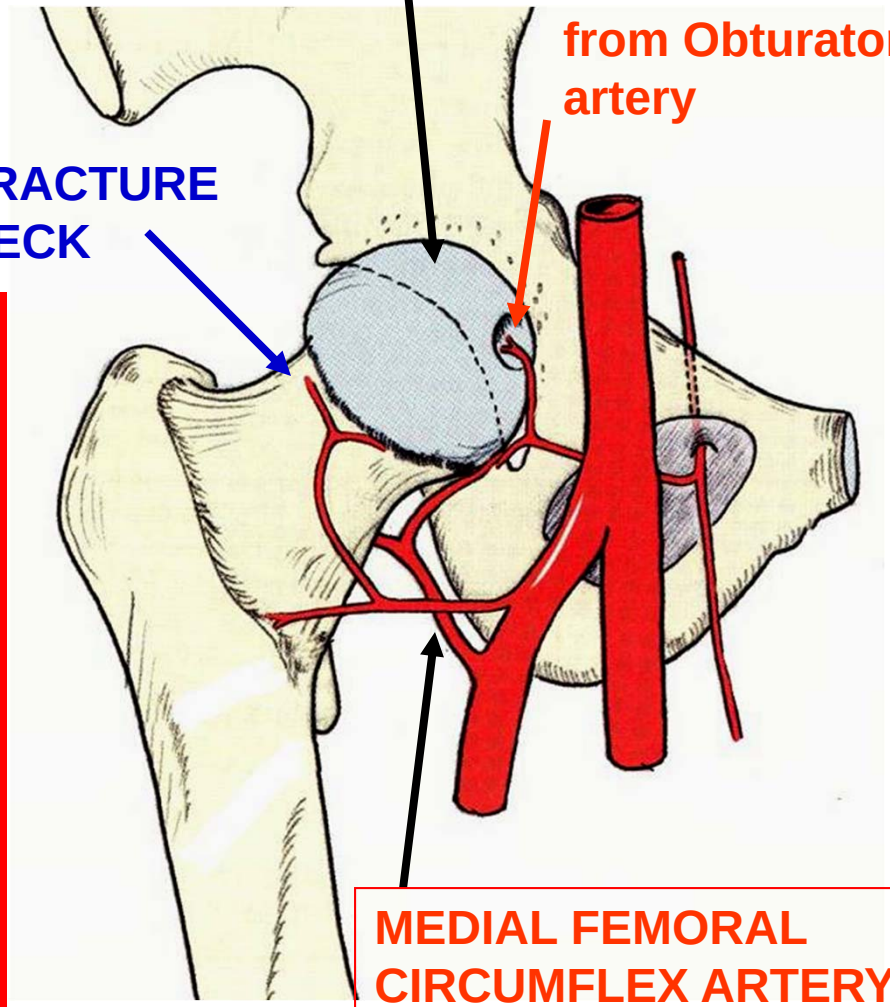

Note: **Fracture of neck of femur** - head and neck of femur receive blood from branches of **Obturator artery** (through ligament of head) and branches of **Medial and lateral femoral circumflex**; after fracture, supply from circumflex arteries is disrupted; if obturator supply is inadequate, **avascular necrosis may occur requiring artificial replacement of head and neck of femur**.

HIP JOINT - LIGAMENTS STRONG

ILIO-
FEMORAL
LIG.

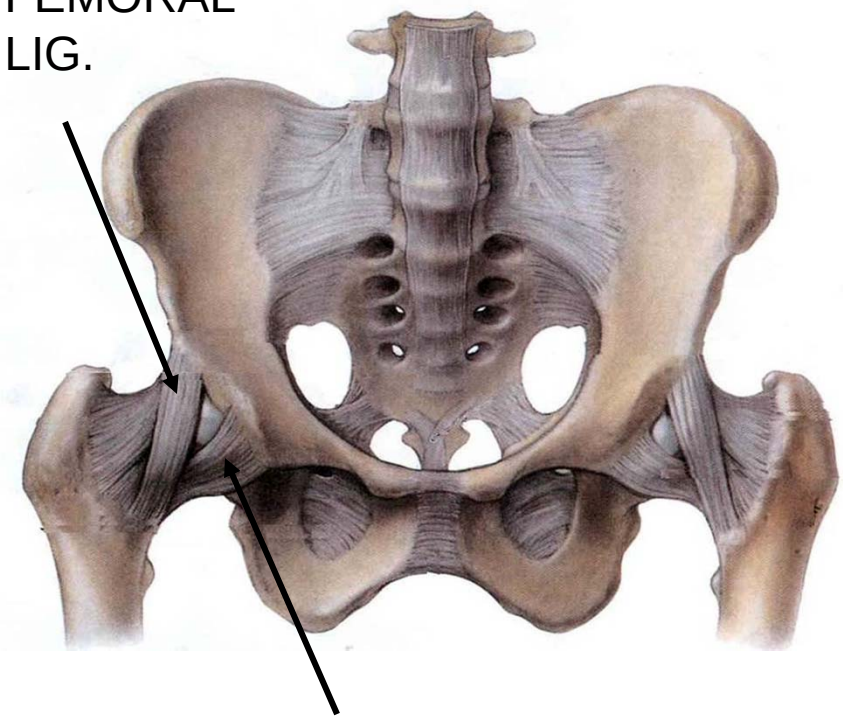

PUBOFEMORAL
LIGAMENT

DISLOCATE HIP JOINT

Note: **Dislocation** - traumatic dislocation is rare due to strength of intrinsic ligaments; **congenitally, upper lip of acetabulum may fail to form and head of femur may dislocate superiorly**; leg is **rotated medially** (action gluteus medius and minimus); also appears to be shorter

Leg is rotated medially and appears to be shorter

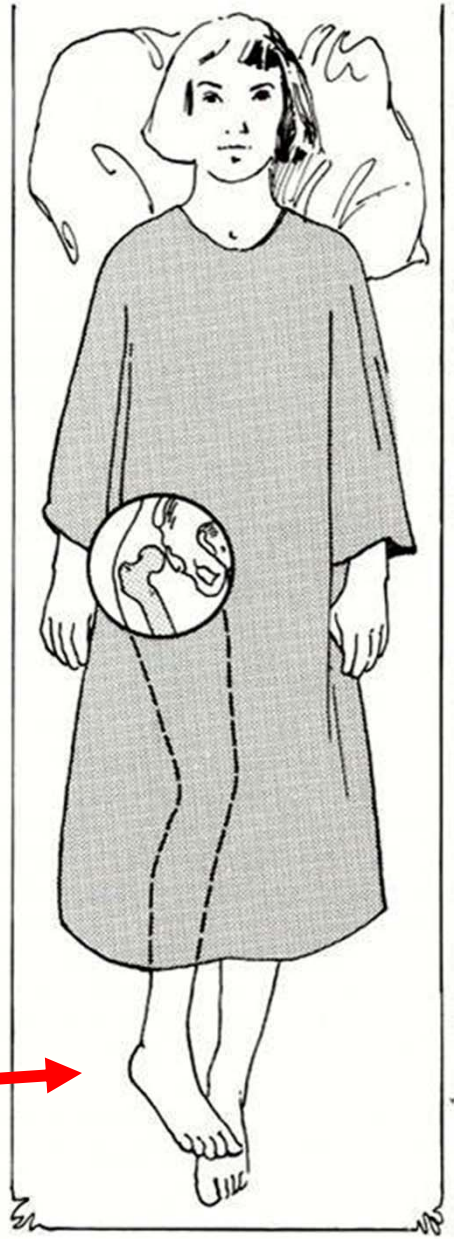

KNEE JOINT -
femur abuts against tibia; fibula not part of joint

Femur

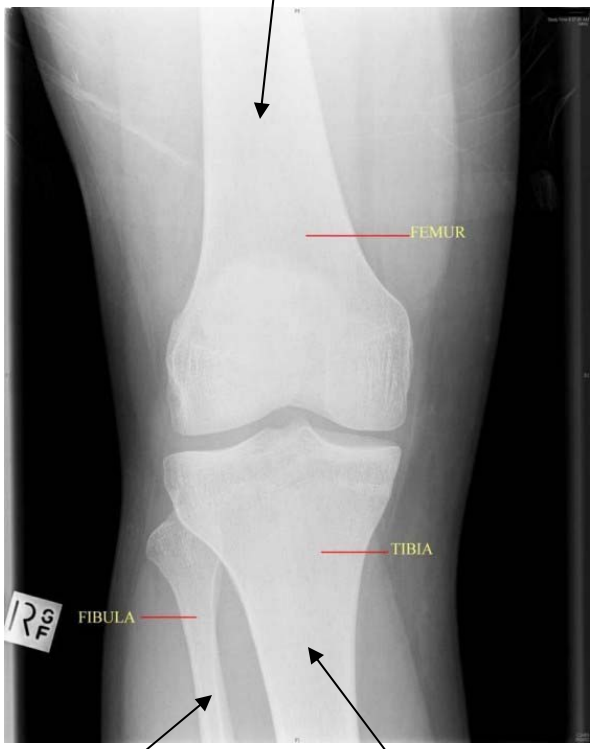

Fibula

Tibia

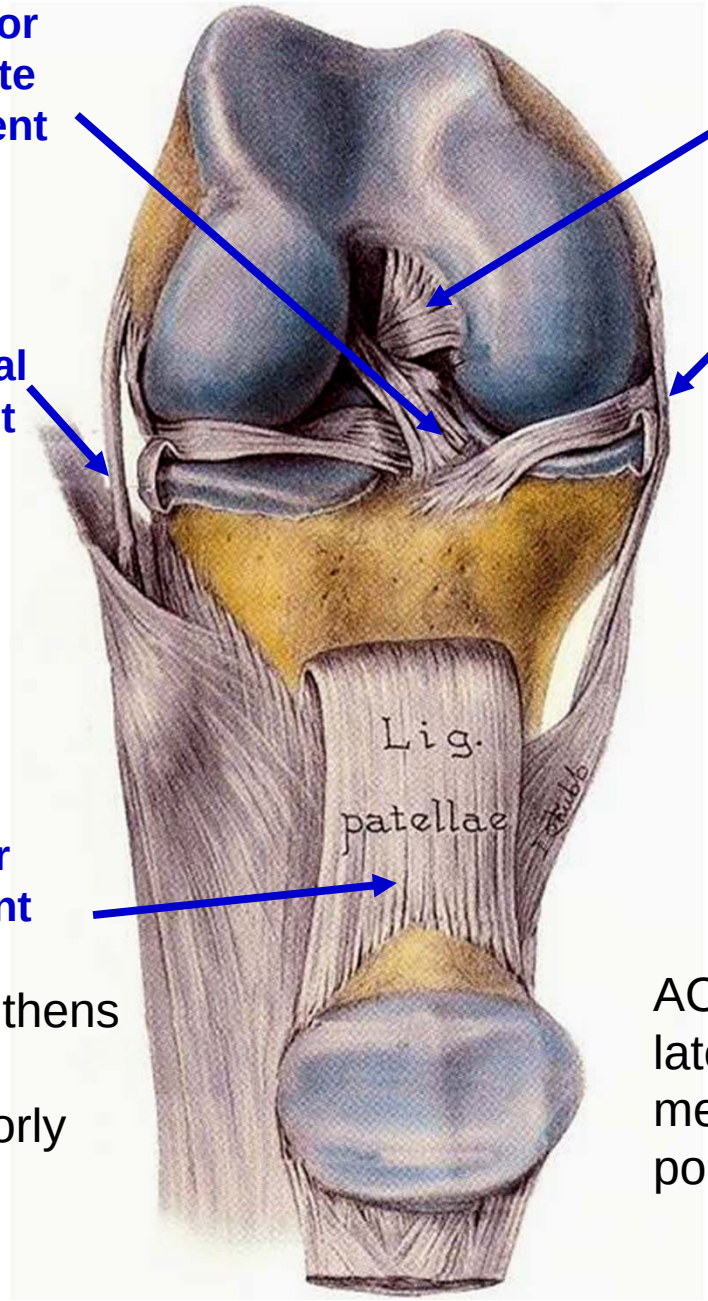

Anterior cruciate ligament

Posterior cruciate ligament

Lateral (fibular) collateral ligament

Medial (tibial) collateral ligament

Patellar ligament

strengthens joint anteriorly

ACL - lateral to medial; points forward

ANTERIOR AND POSTERIOR CRUCIATE LIGAMENTS ALLOW FOR FREE FLEXION AND EXTENSION OF KNEE

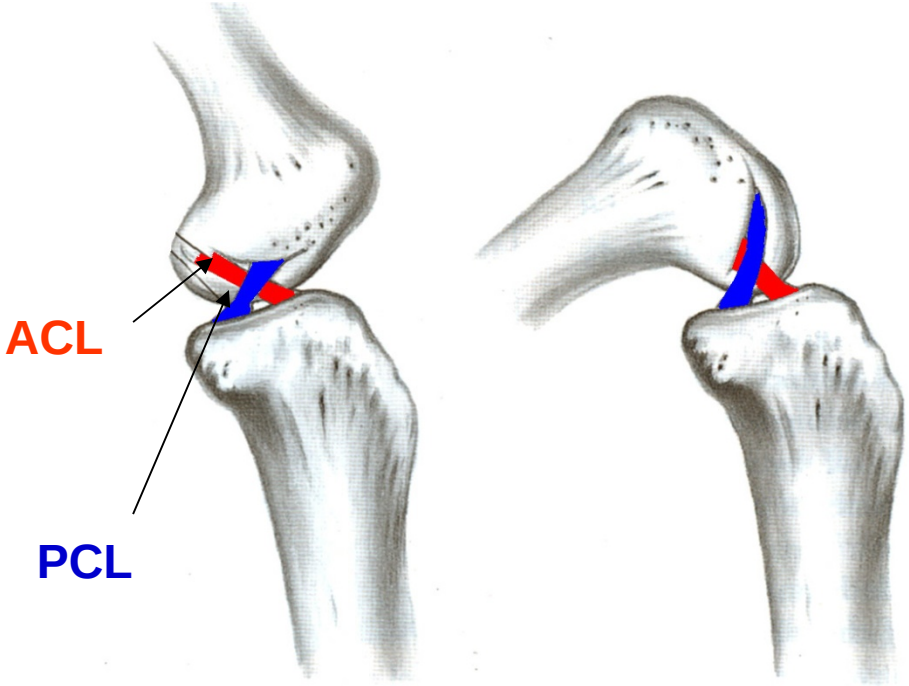

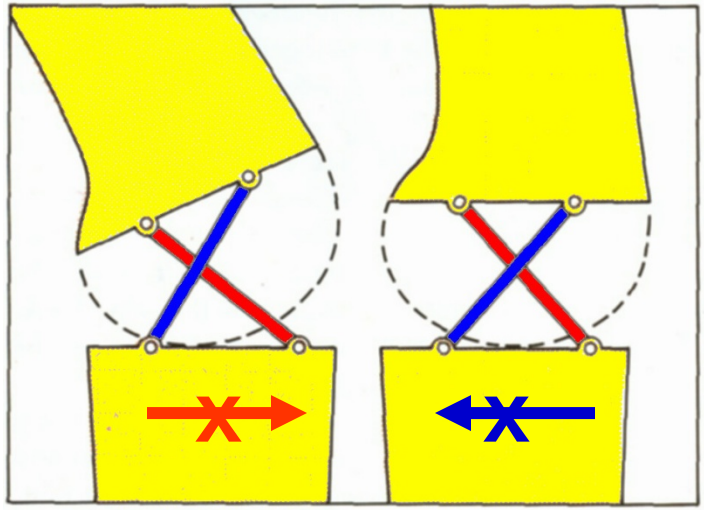

ACL - PREVENTS ANTERIOR MOVEMENT OF TIBIA

PCL - PREVENTS POSTERIOR MOVEMENT OF TIBIA

TESTS FOR TEARS IN CRUCIATE LIGAMENTS

ANTERIOR DRAWER SIGN - pull tibia anteriorly

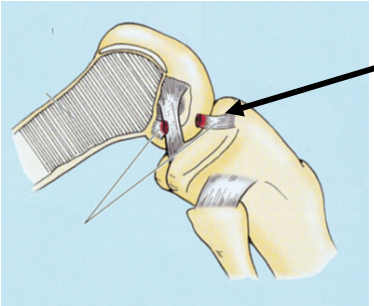

Tear Anterior Cruciate

POSTERIOR DRAWER SIGN

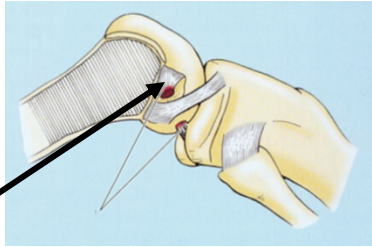

Tear Posterior Cruciate

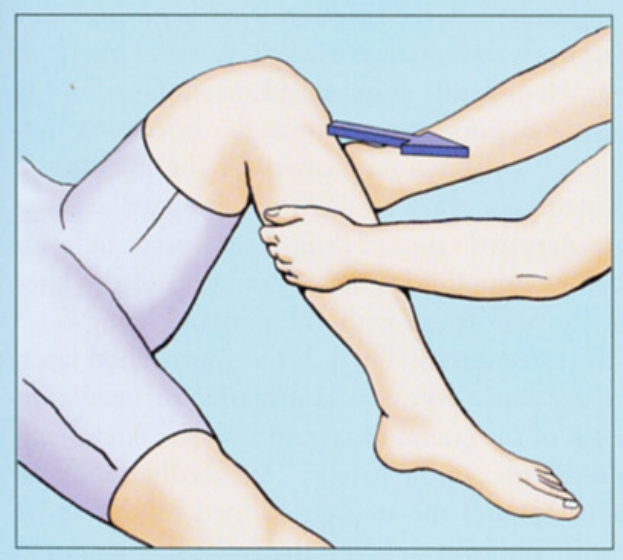

Tear Anterior Cruciate Ligament - can **draw tibia anteriorly**.

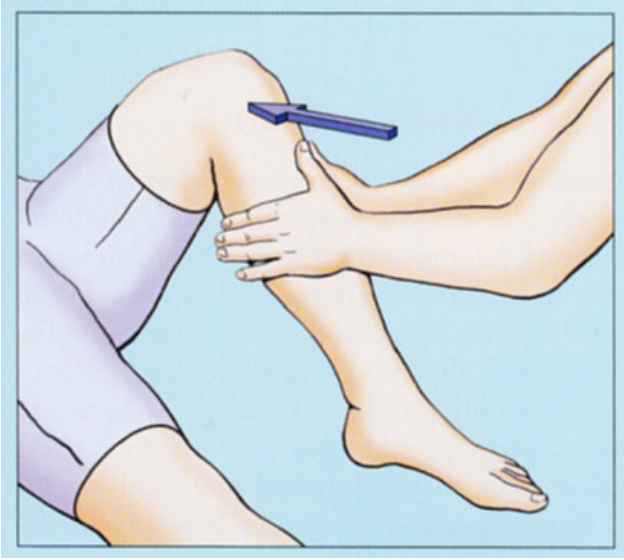

Tear Posterior Cruciate Ligament - can **push tibia posteriorly**

TERRIBLE TRIAD OF KNEE JOINT



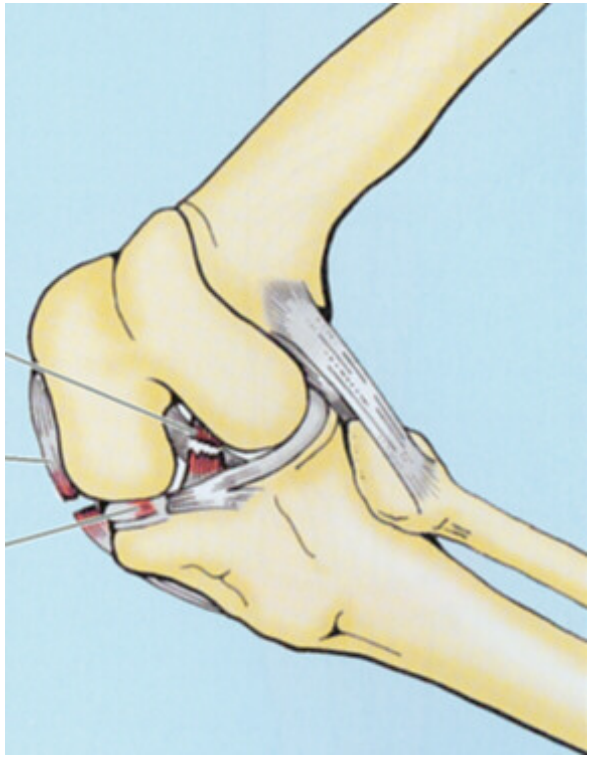

Clinical Note: **Terrible Triad of the Knee joint**: Knee joint is stable in extension but ligaments are slackened by joint flexion; **blow to lateral side** of the knee when the leg is flexed (as can occur in football tackles) or rotate and force lateral movement of body; can tear **Tibial (Medial) collateral ligament, Anterior cruciate ligament and Medial meniscus** (because it is firmly fixed to the medial collateral ligament).

BURSAE OF KNEE CAN BECOME INFLAMMED

Prepatellar bursa in subcutaneous tissue between skin and patella; **inflammation - HOUSEMAID'S KNEE**

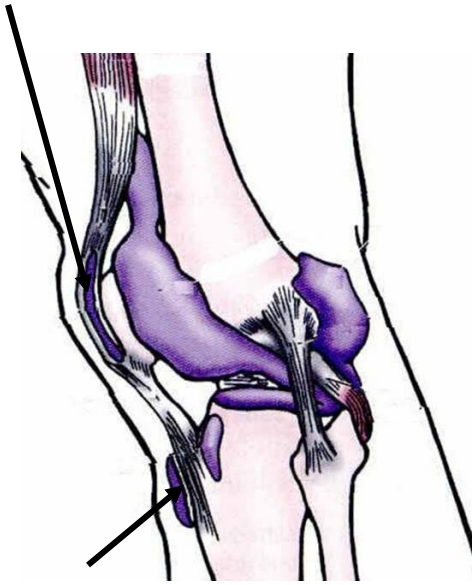

Superficial infrapatellar bursa between skin and patellar ligament - **CLERGYMAN'S KNEE**

Inflammation of Prepatellar bursa - HOUSEMAIDS KNEE

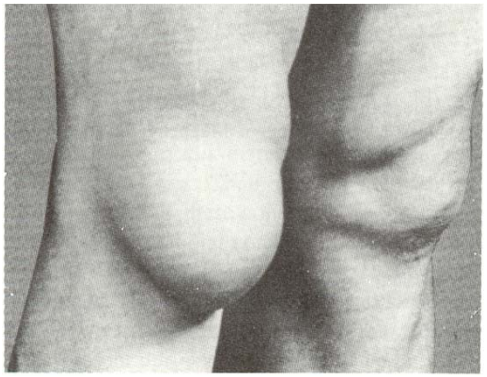

HOUSEMAID'S KNEE.

CLERGYMAN'S KNEE

LEG

POSTERIOR

Gastrocnemius
Soleus
Flexors
Tibialis Posterior

PLANTAR FLEX FOOT

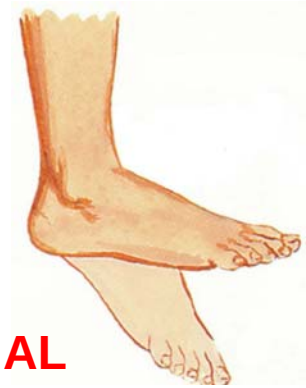

INN - TIBIAL NERVE

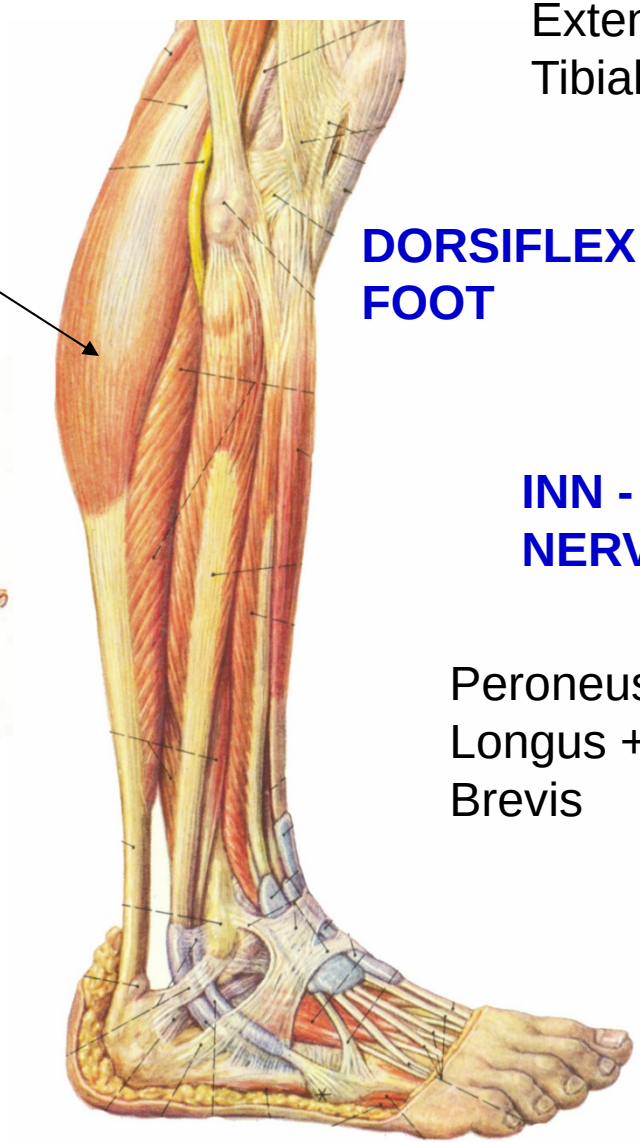

ANTERIOR

Extensors
Tibialis Anterior

DORSIFLEX FOOT

INN - DEEP PERONEAL NERVE

LATERAL

Peroneus Longus + Brevis

EVERT FOOT

INN - SUPERFICIAL PERONEAL NERVE

DAMAGE TO COMMON PERONEAL NERVE - FOOT DROP

Clinical Note: Damage to **Common Peroneal Nerve - most commonly damaged nerve** in lower extremity; very superficial when winds around **neck of fibula**; can be severed by fracture of fibula or damaged from tight plaster cast; sign is **FOOT DROP**; patient cannot lift foot

FOOT DROP

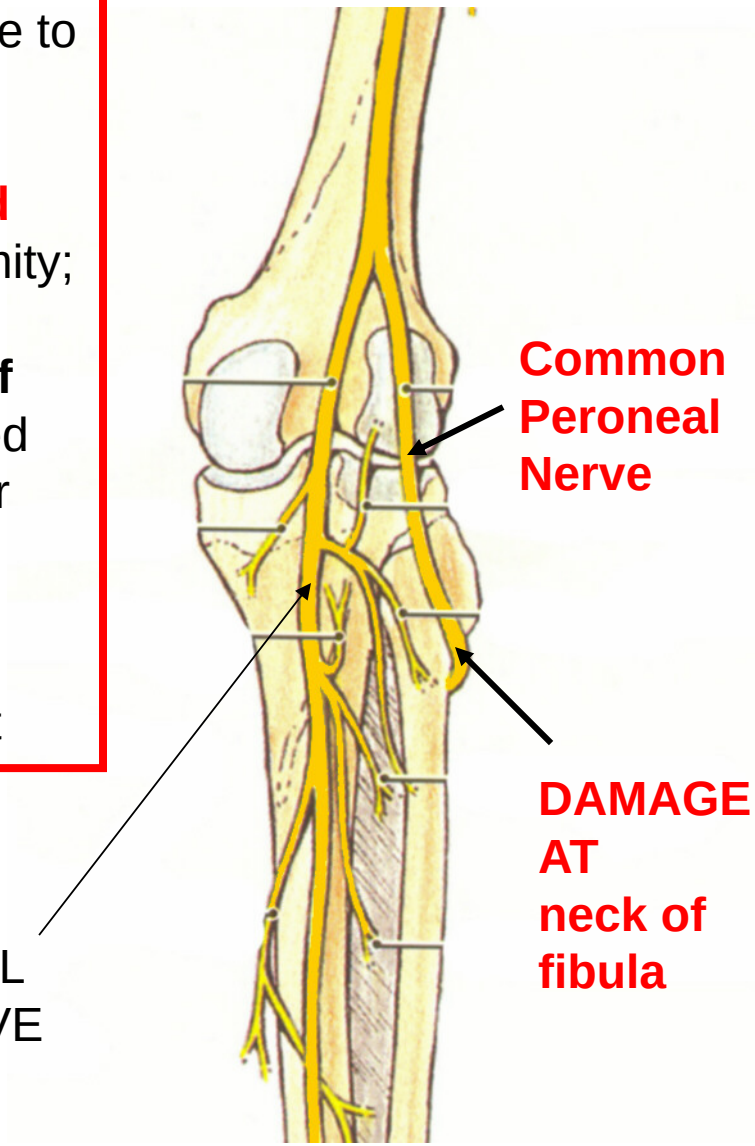

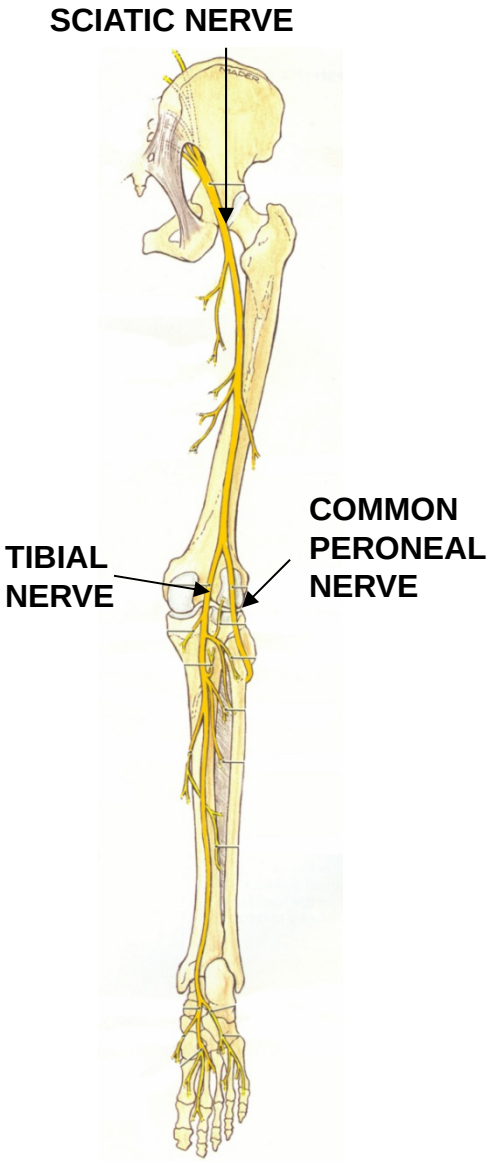

ANTERIOR LEG SYNDROME

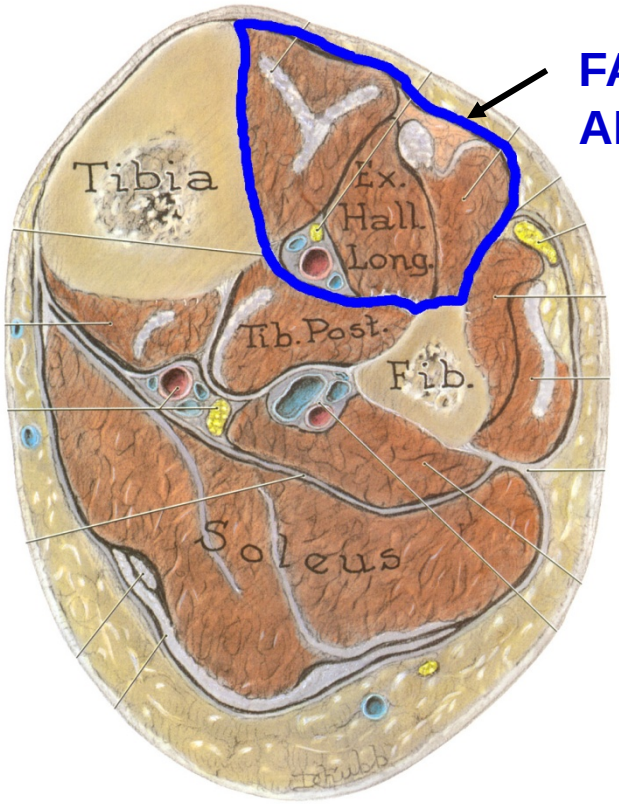

FASCIA IS TOUGH AND TIGHT

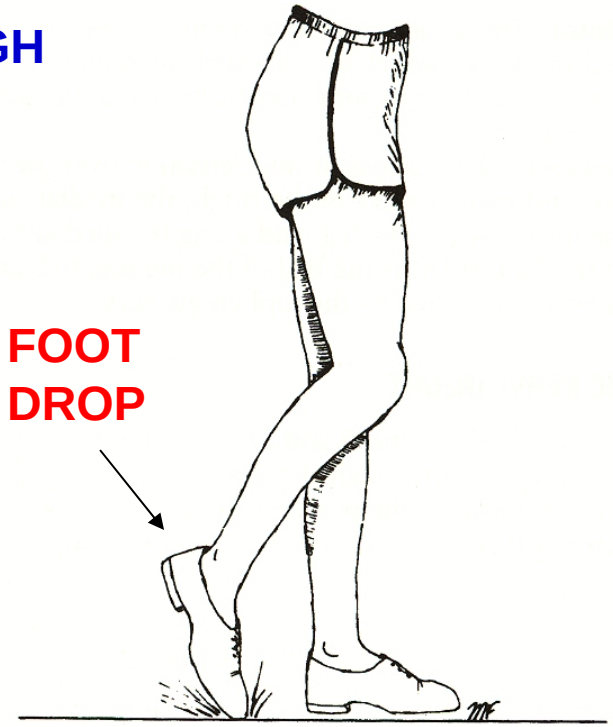

FOOT DROP

Clinical Note: **Anterior Leg Syndrome** - fascia surrounding anterior leg muscles is very tough and tight; muscles can swell in compartment due to exercise or when fracture tibia; symptom is **FOOT DROP** (=loss of dorsiflexion of foot) due to compression of **Deep Peroneal Nerve**; treated by fasciotomy (surgically splitting fascia). (Note: 'shin splints' is different term, inflammation of the periosteum of the tibia)

DEEP MUSCLES: TOM, DICK AND HARRY

ORDER OF STRUCTURES ON MEDIAL SIDE OF ANKLE - **TOM, DICK AND HARRY** - **T**ibialis posterior (tendon), Flexion **D**igitorum Longus, Posterior Tibial **A**rtery, Tibial **N**erve and Flexor **H**allucis Longus.

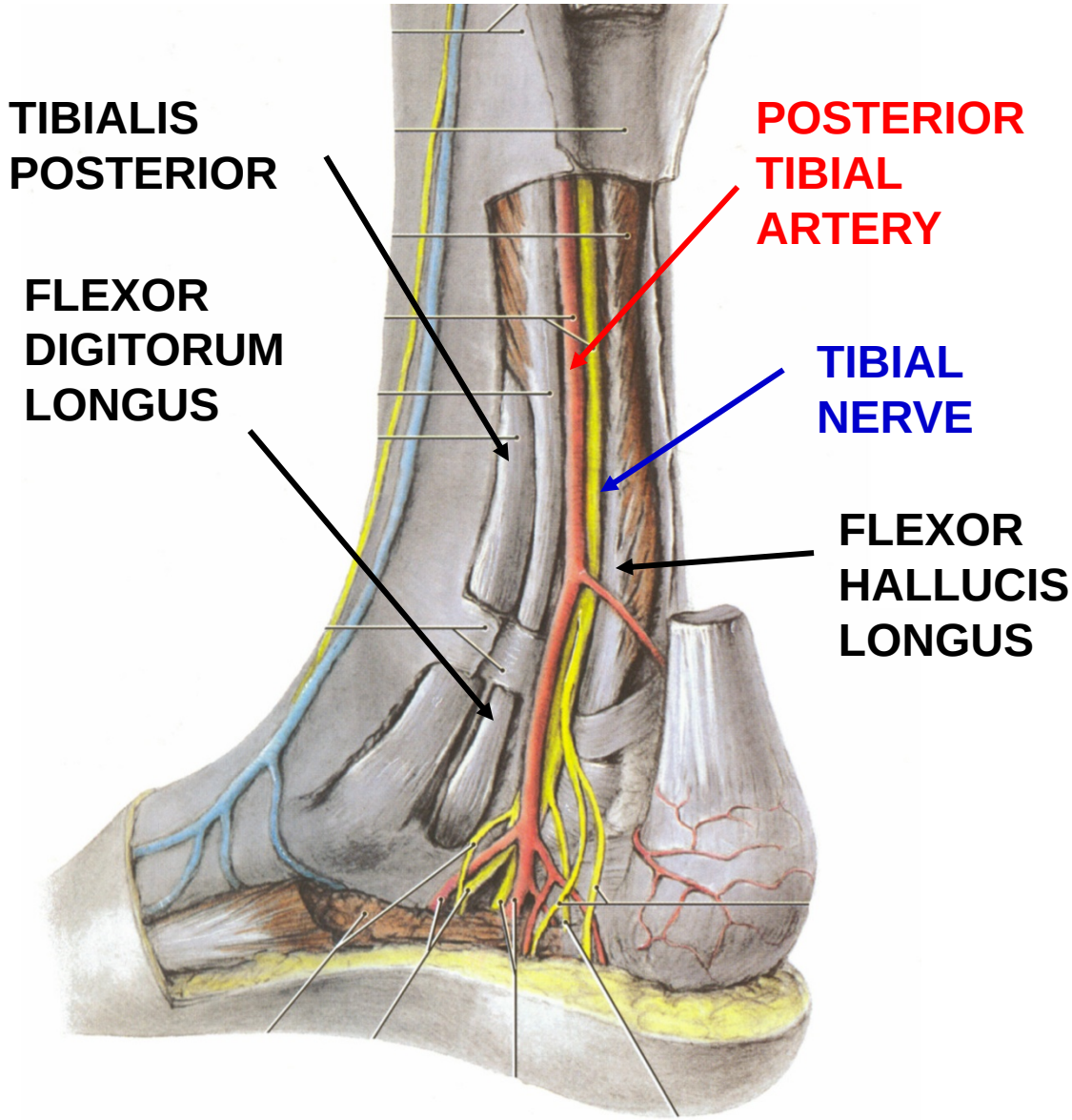

Note: Order is important as accidents can happen that sever tendons (i.e. ax strikes ankle when chopping wood).

FLEXOR RETINACULUM AND TARSAL TUNNEL SYNDROME

Note: **Flexor Retinaculum** - tendons of deep muscles pass beneath flexor reticulum on medial side of ankle joint; muscle tendons are covered **synovial sheaths** under retinaculum

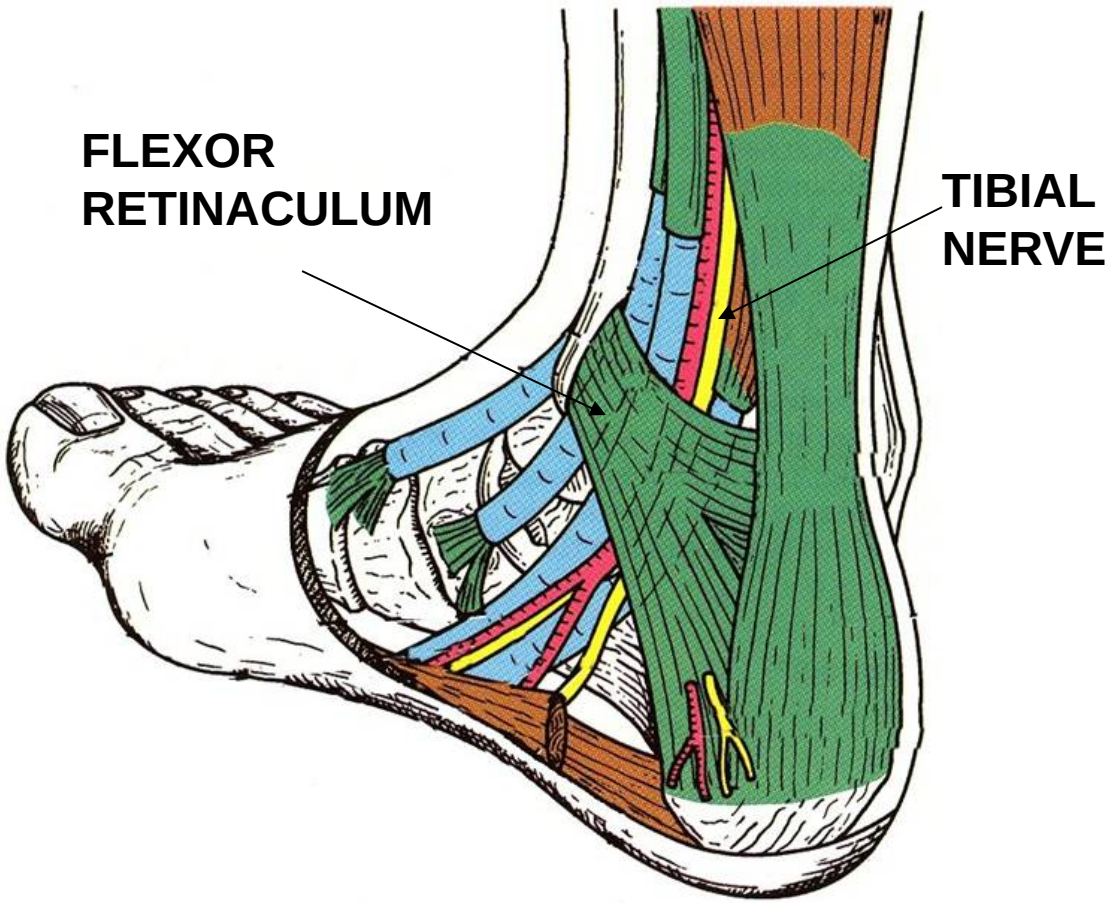

Clinical Note: **Tarsal Tunnel Syndrome** - Tarsal Tunnel is area beneath flexor retinaculum; Tarsal Tunnel Syndrome results from **swelling of synovial sheaths**; can compress **Tibial Nerve**; symptoms are **numbness of sole of foot, toes and weakened flexion of toes** (intrinsic muscles of foot).

INTERMITTENT CLAUDICATION

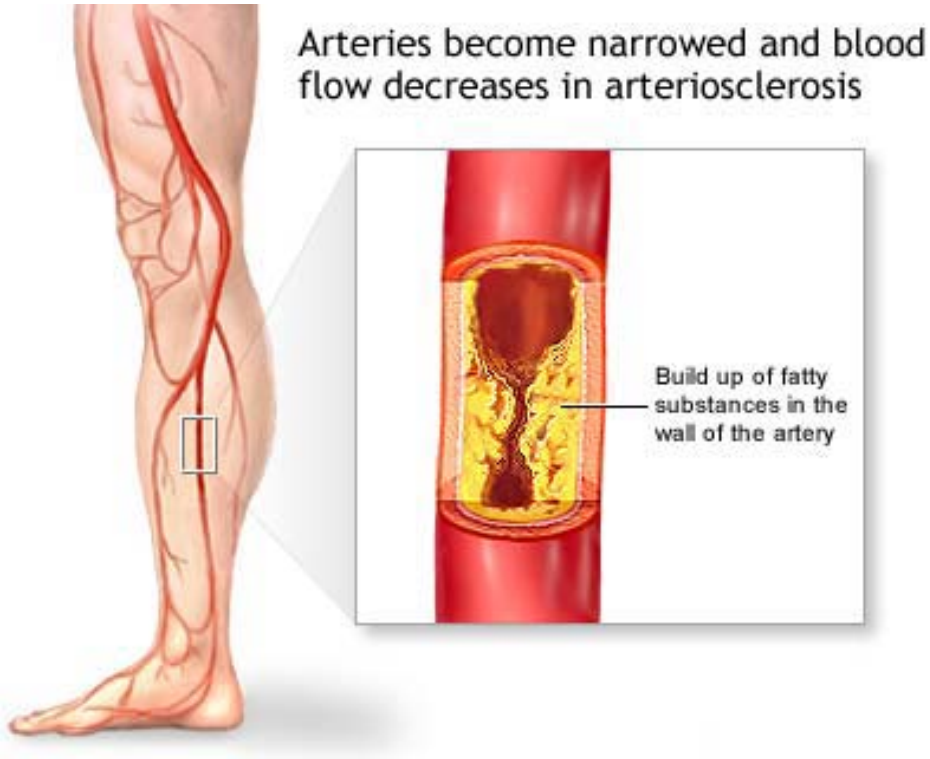

Note: **Intermittent Claudication** (L. claudico, limping) - Narrowing of posterior tibial artery due to arteriosclerosis; produces ischemia; patients have painful cramps when walking but subsides after rest.

ARTERIES

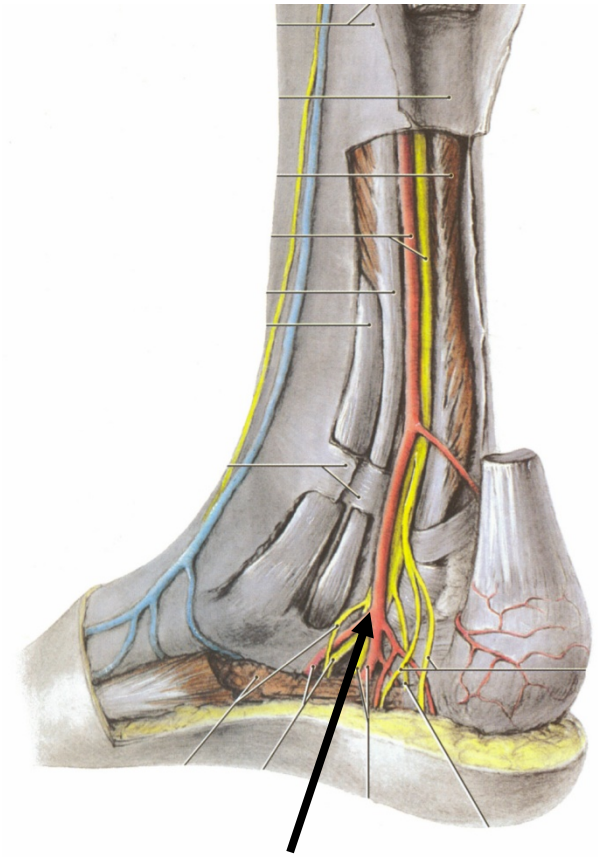

Note: **Pulse of Posterior Tibial Artery** - taken between medial malleolus and tendo calcaneus.

BONES OF FOOT

MED. VIEW

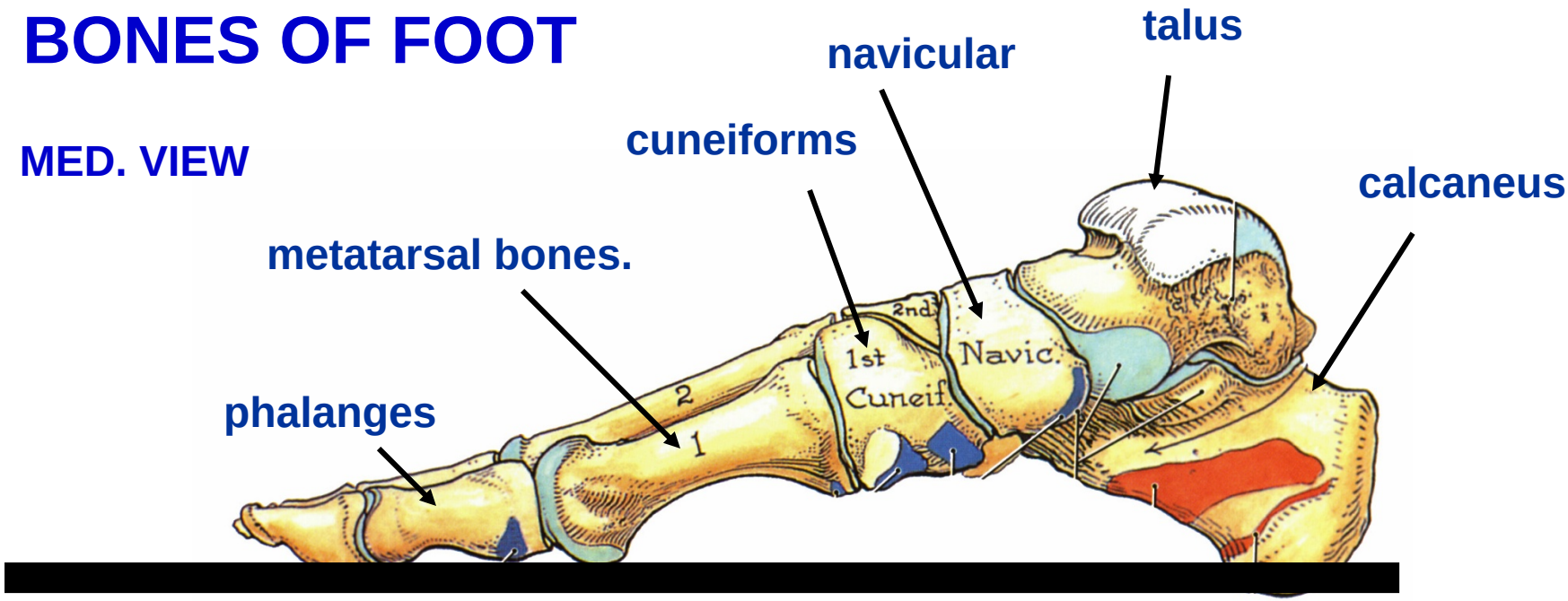

LAR. VIEW

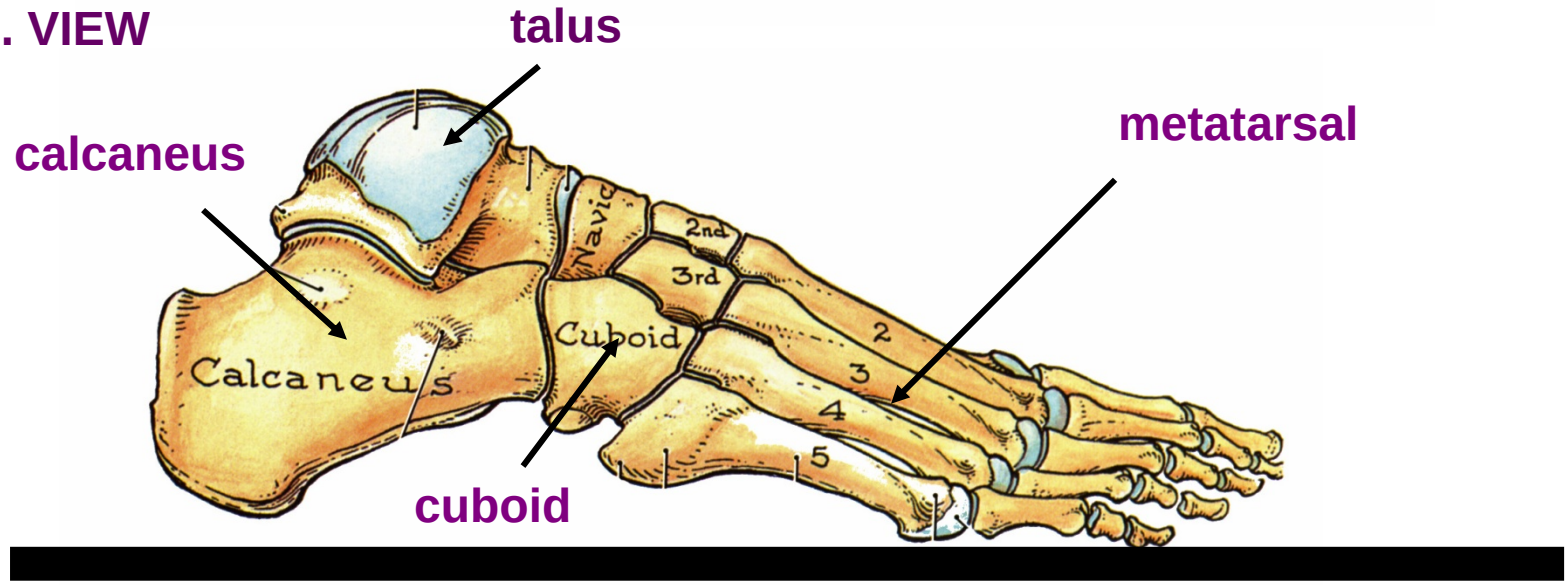

ANKLE JOINT: DORSIFLEXION/PLANTAR FLEXION

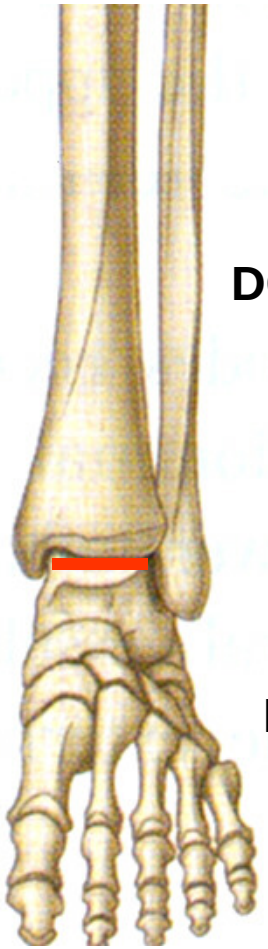

DORSIFLEXION

PLANTAR FLEXION

TIBIA AND FIBULA AND TALUS

JOINTS OF INVERSION AND EVERSION

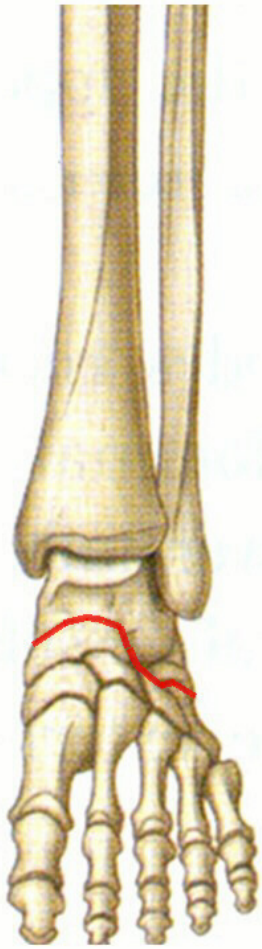

INVERSION

EVERSION

1) **Subtalar joint** (between **talus and calcaneus**)
2) **Transverse tarsal joint** (between **talus and navicular** bones medially, **calcaneus and cuboid bones** laterally.

ANKLE JOINT: LIGAMENTS

MEDIAL - LIGAMENT STRONG

LATERAL - LIGAMENTS WEAKER

DELTOID LIGAMENT

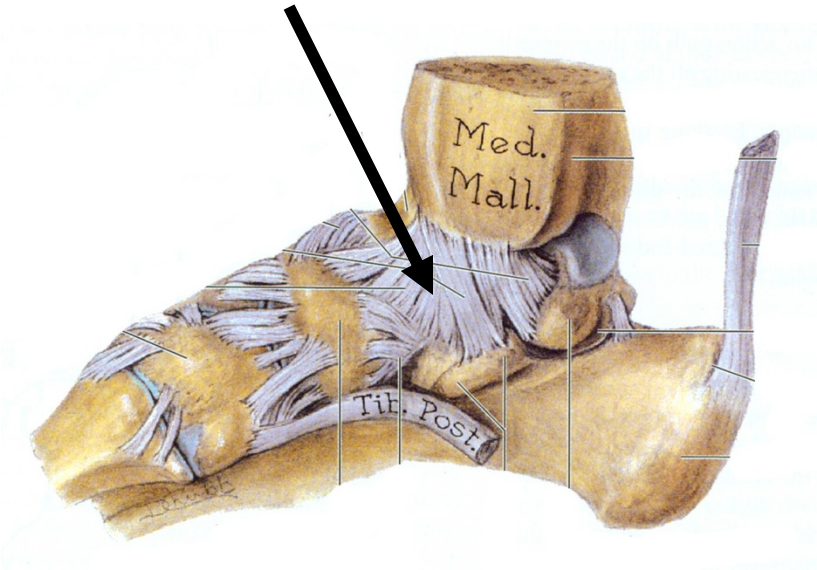

Posterior Talofibular

Anterior Talofibula

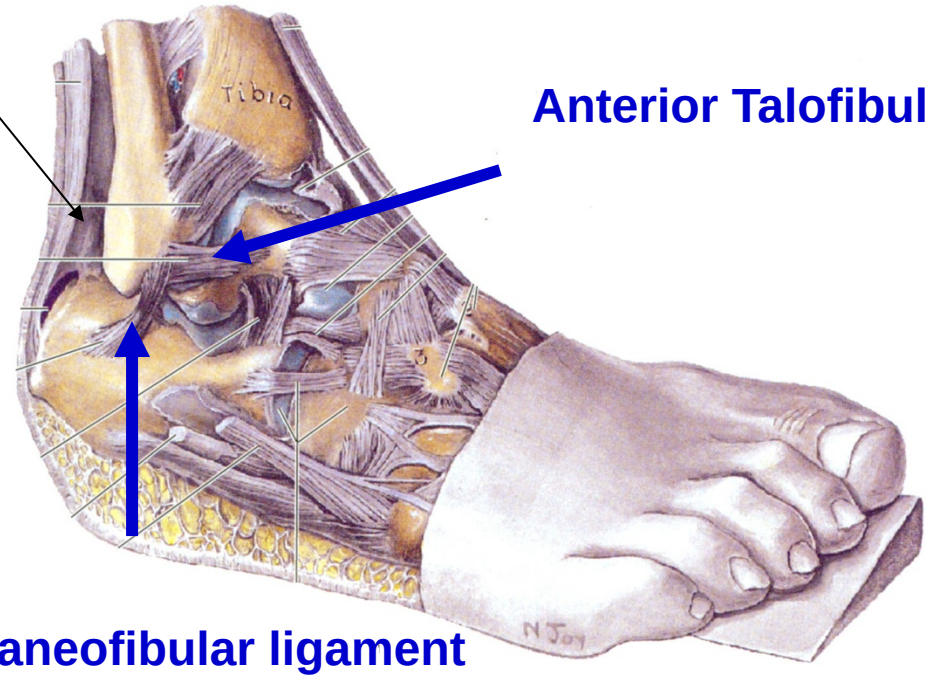

Calcaneofibular ligament

LIGAMENTS ALLOW FREE DORSIFLEXION AND PLANTAR FLEXION
PREVENT EXCESSIVE EVERSION AND INVERSION

SPRAINED ANKLE: EXCESSIVE INVERSION

Note: **Sprains** of ankle are usually caused by **excessive inversion**; **Anterior talofibular** and **Calcaneofibular ligaments** are commonly **stretched or partially torn**.

Symptom - pain on LATERAL side of ANKLE

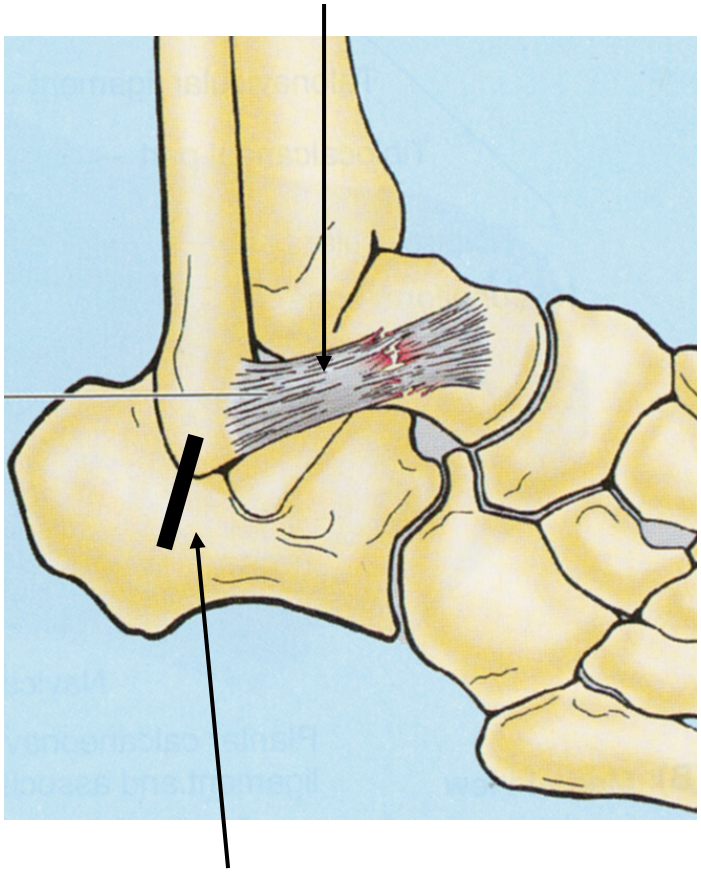

POTT'S FRACTURE: EXCESSIVE EVERSION

Note: **Pott's fractures** are caused by **excessive eversion**; strong **Deltoid ligament does not rupture** but **medial malleolus is fractured**; also **break shaft of fibula.**

SYMPTOM - pain in ankle

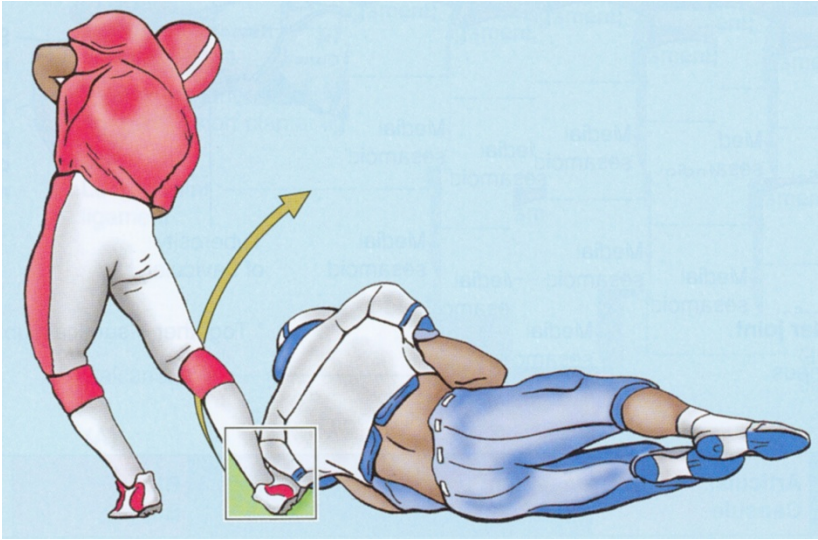

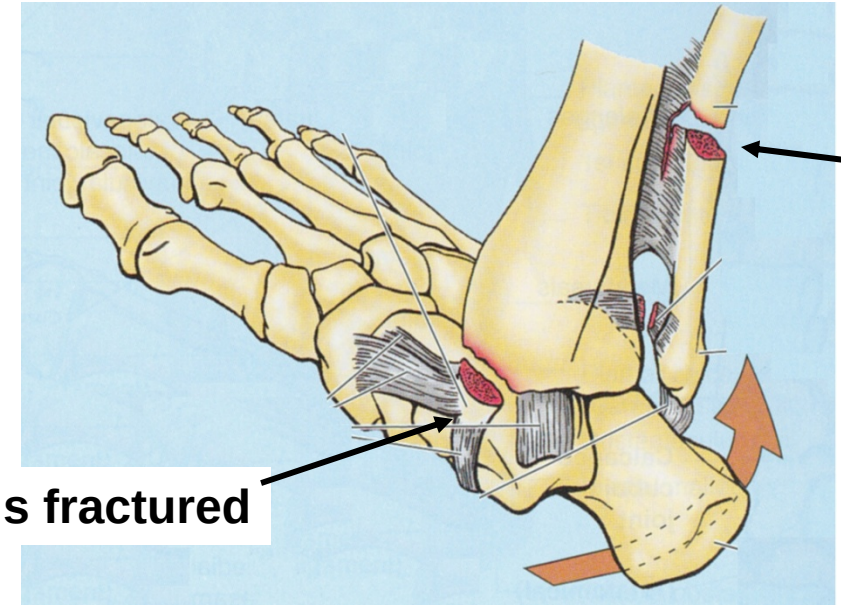

Fibula is fractured

Medial malleolus is fractured

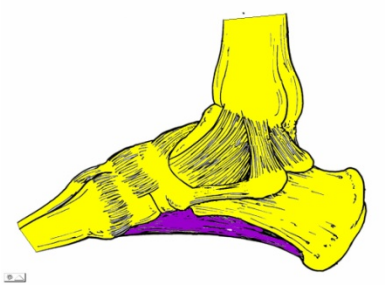

MEDIAL ARCH

Medial Longitudinal arch - highest arch, responsible for 'fallen arches'
-formed by - **calcaneus, talus, navicular, cuneiforms and medial three metatarsal bones.**

F = k*x

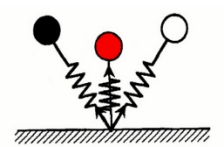

Load springs when put weight on foot on ground

F = force
x = vertical displacement

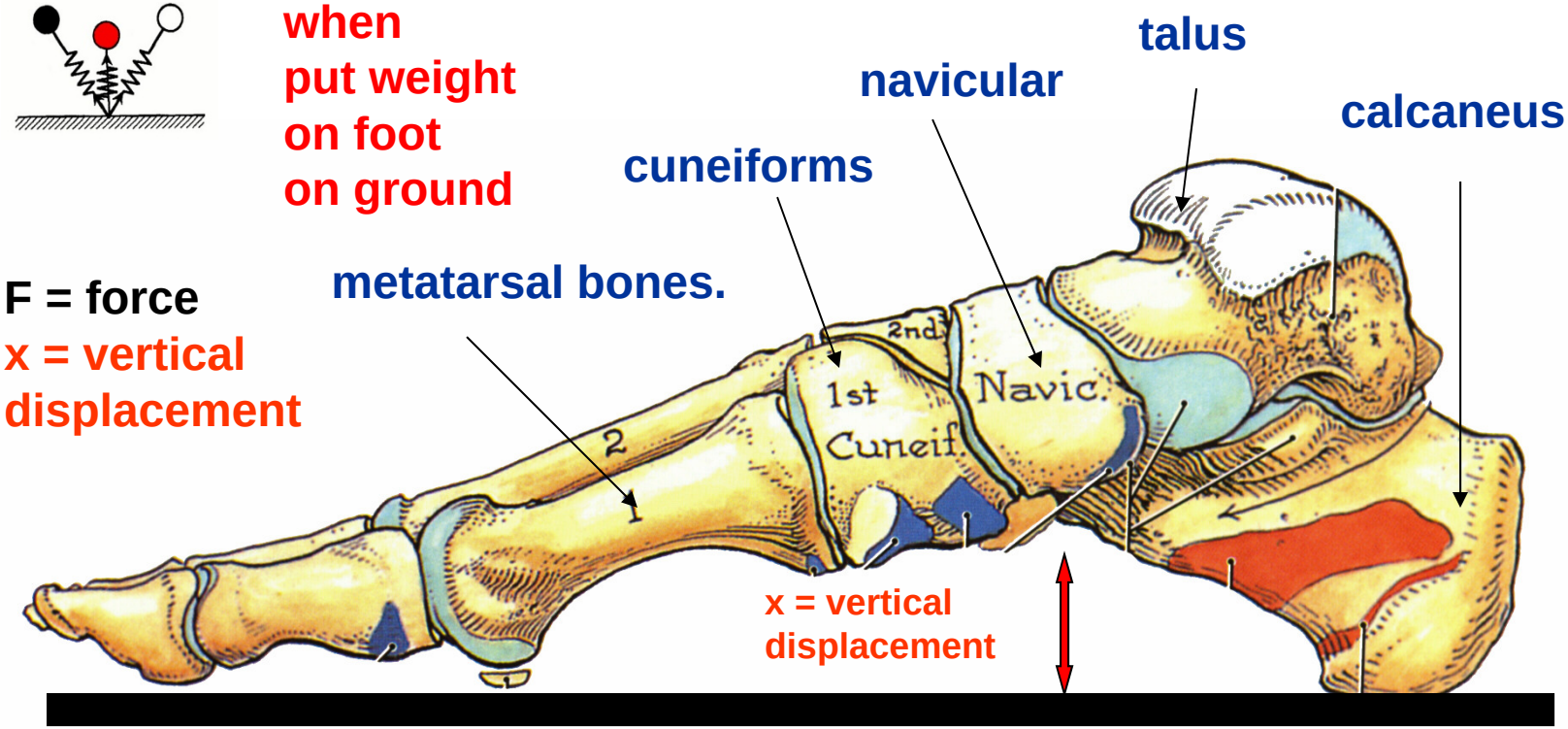

MEDIAL ARCH

- supported by ligaments and muscles

i. **Plantar Calcaneonavicular Ligament - 'Spring' ligament,** most important ligament, keeps head of talus high off ground.

ii. **Tibialis Posterior and Tibialis Anterior** - insert to medial side of foot and support arch.

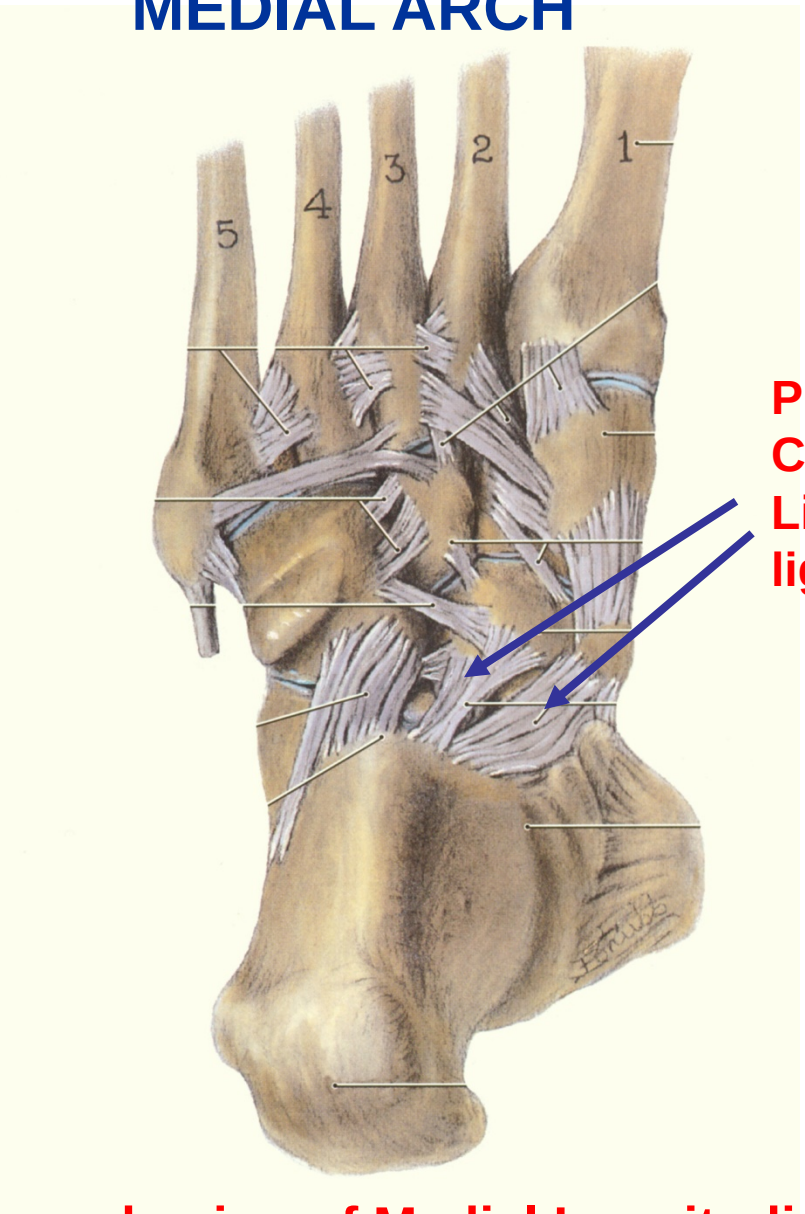

Plantar Calcaneonavicular Ligament - 'Spring' ligament,

Note: **'Flat' Feet - weakening of Medial Longitudinal arch** - associated with **stretching of <u>Plantar Calcaneonavicular ligament</u>**.

GOOD LUCK!

LATERAL ARCH

2. **Lateral Longitudinal arch** - smaller
a. formed by - **calcaneus, cuboid and lateral two metatarsals**
b. supported by
i. Long Plantar Ligament and Plantar Aponeurosis
ii. Peroneal tendons

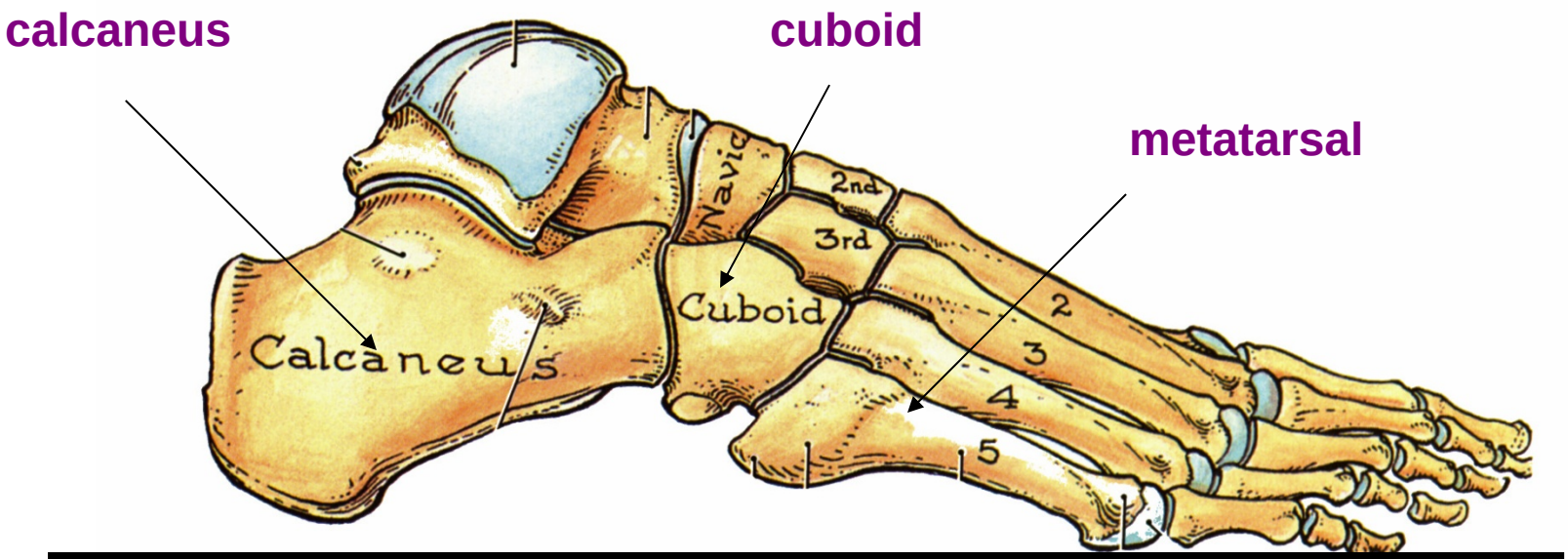

LATERAL ARCH

b. supported by
i. **Long Plantar Ligament** and Plantar Aponeurosis
ii. **Peroneal tendons**

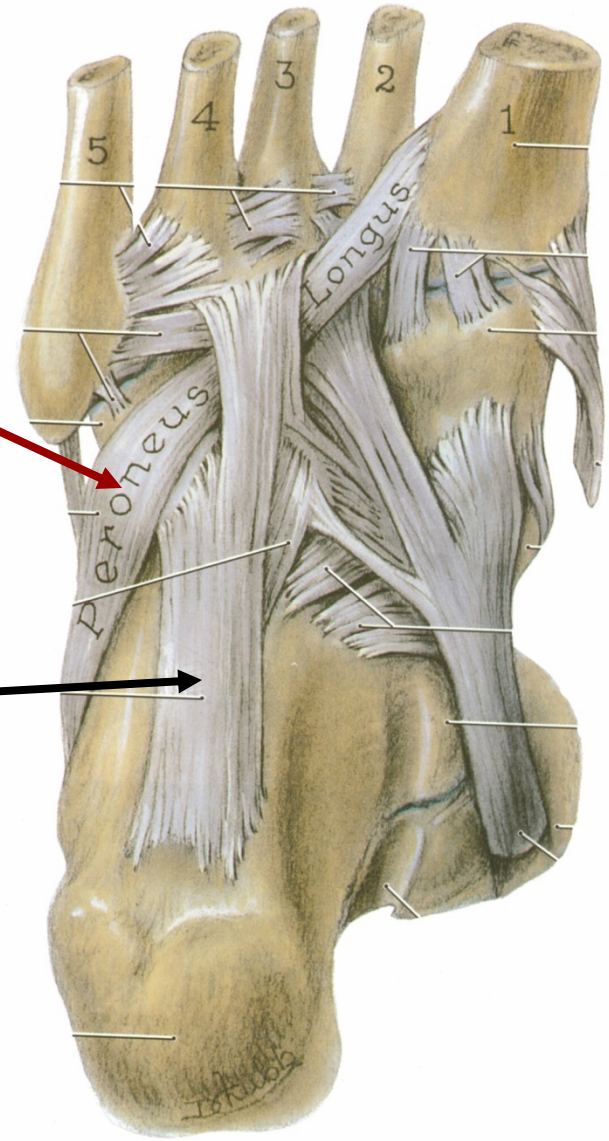

TRANSVERSE ARCH

3. **Transverse arch**
a. formed by **cuneiform** and **cuboid bones** and **metatarsals**

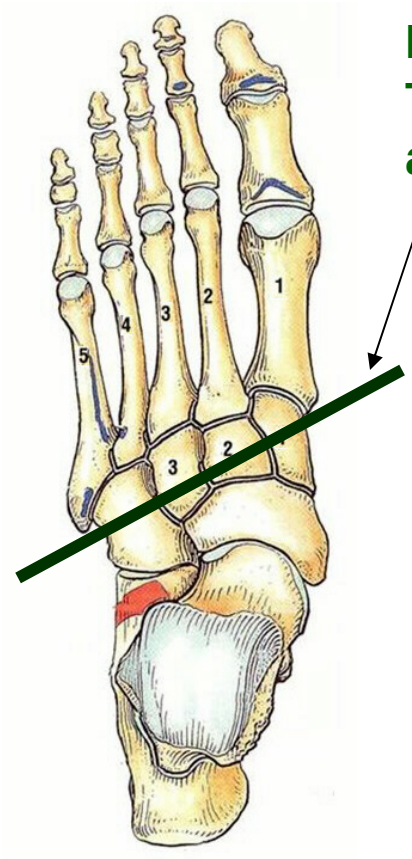

Plane of Transverse arch

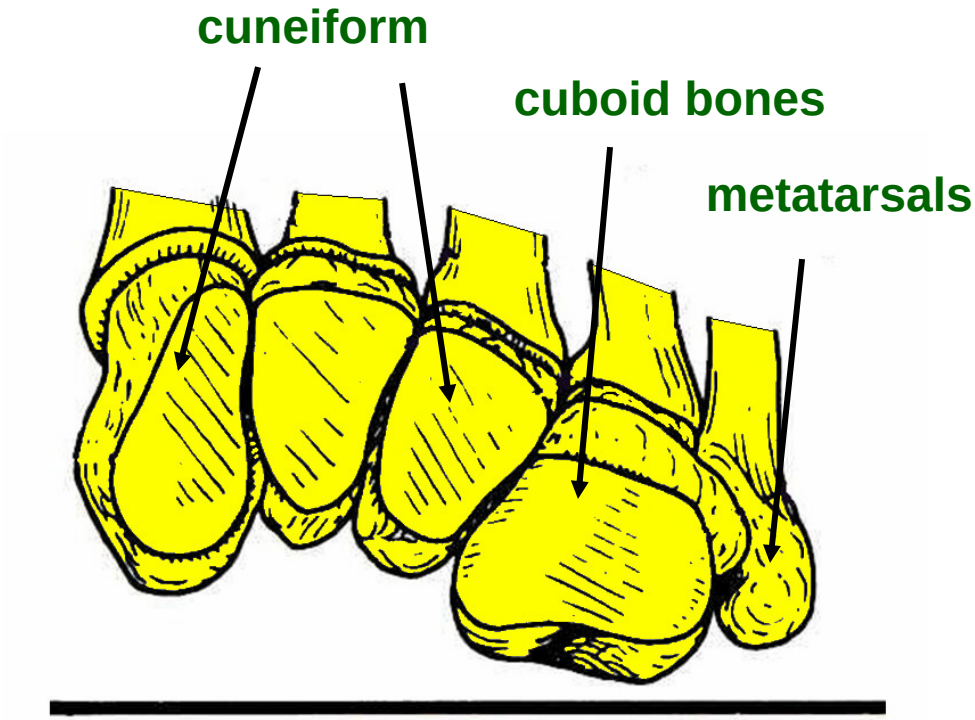

supported by Interosseus muscles and Peroneus longus tendon

GENICULAR ANASTOMOSIS

1. **Superior Medial Genicular artery** - anastomoses with Descending Genicular artery (from Femoral Artery)
2. **Superior Lateral Genicular artery** - anastomoses with Descending branch of Lateral femoral circumflex artery
3. **Inferior Medial Genicular artery** - anastomoses with Recurrent branch of Anterior Tibial artery
4. **Inferior Lateral Genicular artery** - anastomoses with Recurrent branch of Anterior Tibial artery

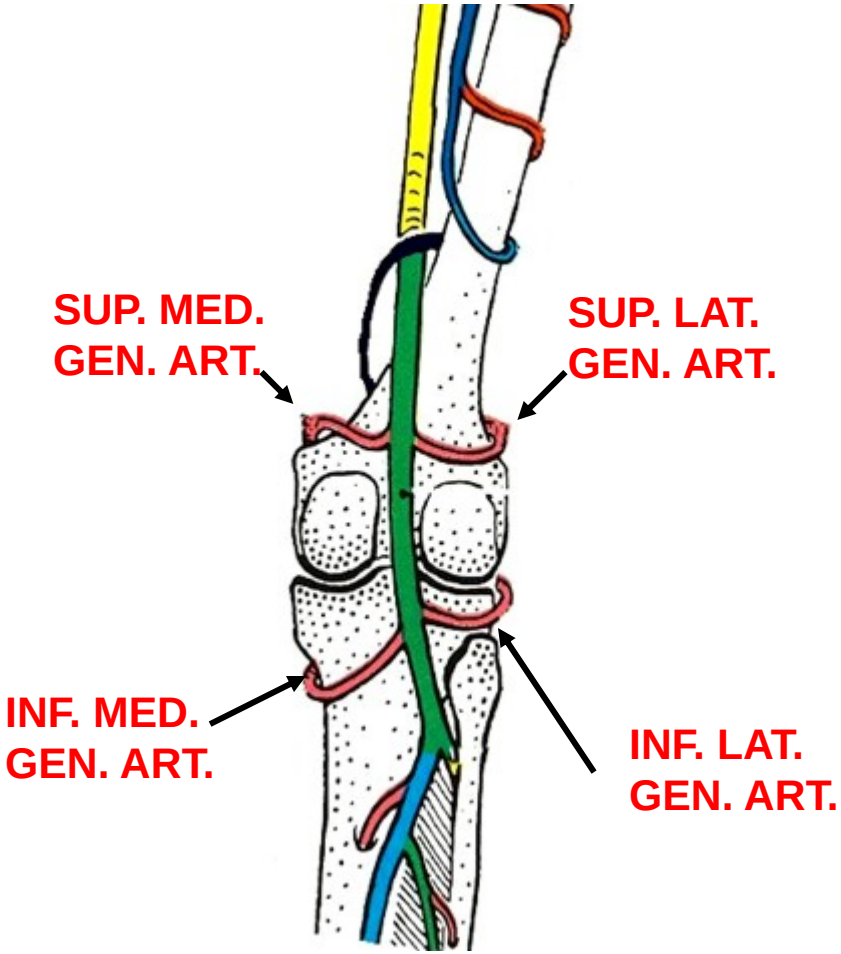

posterior view

GENICULAR ANASTOMOSIS

1. Superior Medial Genicular artery - anastomoses with Descending Genicular artery (from Femoral Artery)
2. Superior Lateral Genicular artery - anastomoses with Descending branch of Lateral femoral circumflex artery
3. Inferior Medial Genicular artery AND
4. Inferior Lateral Genicular artery - BOTH anastomose with Recurrent branch of Anterior Tibial artery

DESC. GEN. FROM FEMORAL → SUP. MED. GEN. ART.

DESC. BR. LAT. FEM. CIRC. → SUP. LAT. GEN. ART.

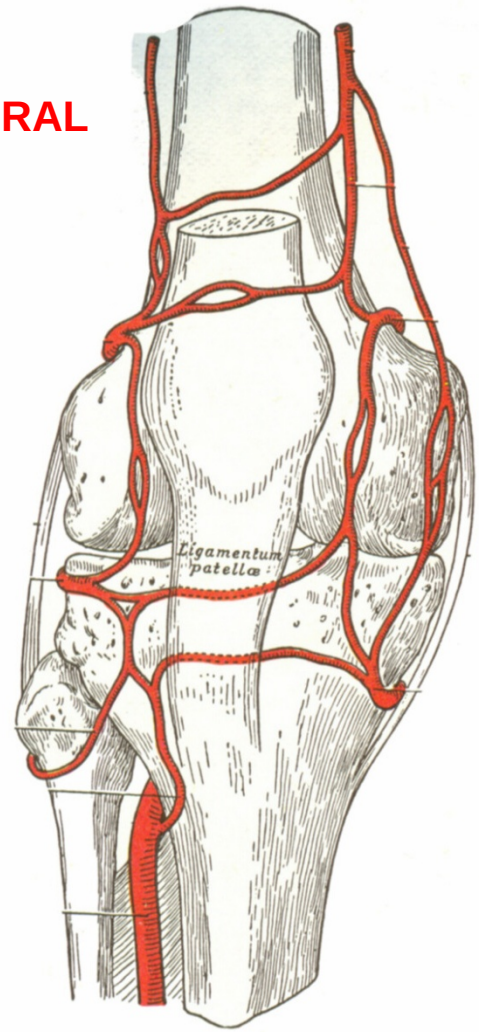

INF. LAT. GEN. ART. ← RECURR. BR. ANT. TIB. A.

INF. MED. GEN. ART. ← RECURR. BR. ANT. TIB. A.

anterior view

LOCKING AND UNLOCKING KNEE JOINT

- When moving to full extension of knee joint, femur rotates medially during last 30 degrees of movement.
- this pulls all major ligaments of the knee joint taut, 'locking' the knee and making it very stable;
- to flex knee from full extension, joint must first be unlocked by contracting the **popliteus muscle** which rotates the femur laterally (foot is firmly on ground)

Femur rotates medially during last 30 degrees of extension, due to shape of condyles

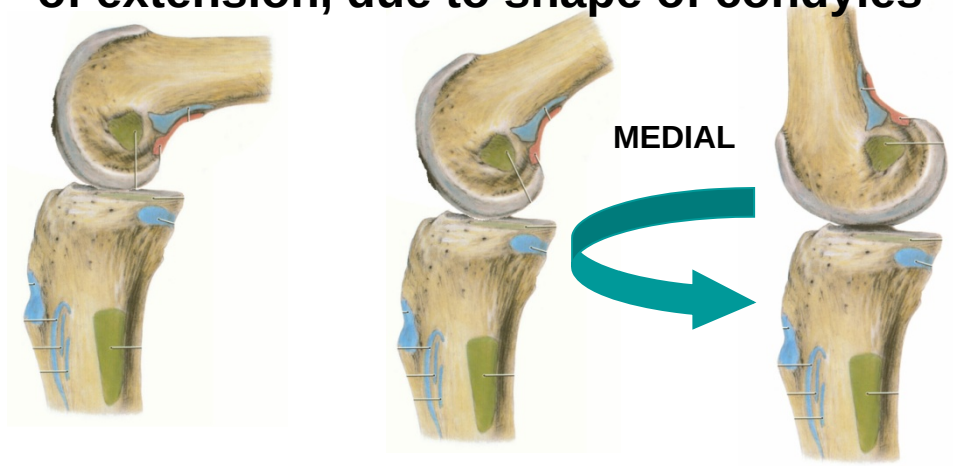

FLEXED

EXTENDED



POPLITEUS UNLOCKS KNEE WHEN FLEX KNEE BY ROTATING FEMUR LATERALLY (FOOT ON GROUND)