REVIEW VERTEBRAE, SPINAL NERVES, REFLEXES

1) VERTEBRAE - NORMAL SPINAL CURVATURES: Primary = Concave Anterior - (fetal curvature); preserved in adult Thorax, Sacrum
Secondary = Concave Posterior (develop in childhood) - Cervical (support head), Lumbar (support body)

ABNORMAL CURVATURES - all can cause pain from compression of spinal nerves

	Curvature	Location (Most common)	Cause
Kyphosis	Exaggerated Concave **Anterior**	Often in **Thoracic Region (Hump back)**	**Osteoporosis**, etc. - loss of bone in bodies of vertebrae
Scoliosis	Exaggerated **Lateral**	**Thoracic, Lumbar** most common	**Hemivertebra** (half of vertebral body does not form in development), etc.
Lordosis	Exaggerate Concave **Posterior**	**Lumbar** (normal in pregnancy)	**Obesity, etc**.

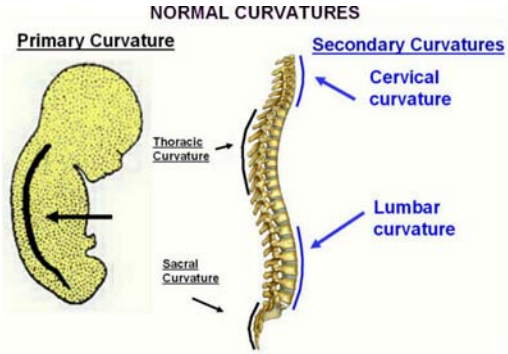

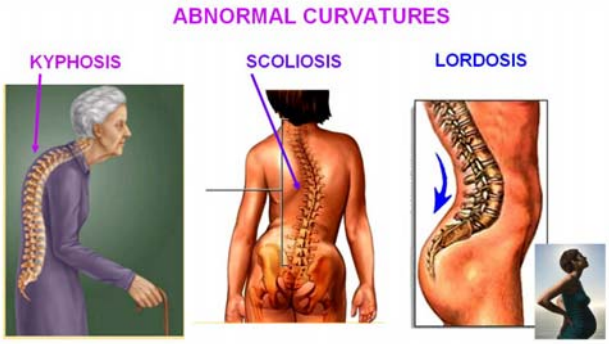

SUMMARY OF LIGAMENTS OF VERTEBRAE AND DISC HERNIATION

Ligament	Connects	Clinical
Anterior Longitudinal Ligament	Anterior side of bodies of vertebrae	Broad band; **Prevents disc herniation anteriorly**
Posterior Longitudinal Ligament	Posterior side of bodies of vertebrae (inside canal)	Narrow band; (**intervertebral discs herniate in postero-lateral direction, lateral to ligament**)
Ligamenta Flava	Elastic layer connecting Laminae of vertebrae	Last layer penetrated by needle in **Epidural anesthesia**; (Note: **Dura is last** in **Lumbar Puncture** spinal tap)
Interspinous and Supraspinous ligaments	Spines of vertebrae	Thickened in neck to form **Ligamentum nuchae** (extends from Ext. Occipital Protuberance to C7)

Note: **Herniation of Nucleus pulposus = 'Slipped Disc'** - Nucleus pulposus bulges out through Annulus fibrosus; usually in\a **Posterolateral direction** (lateral to the Posterior Longitudinal Ligament); **Most common at levels L4-L5 or L5-S1**.
Note: **Cervical Intervertebral Disc Herniation** - Second most common region for disc herniation; **Lower cervical disc hernation** - **Symptoms in Upper Extremity, if below C4 (Brachial Plexus C5-C8, T1)**

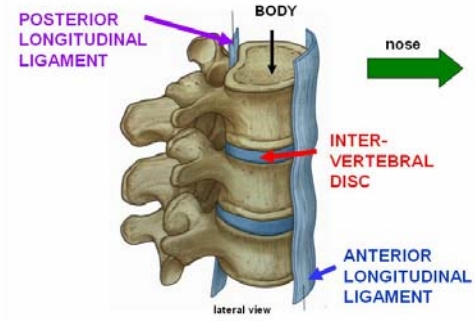

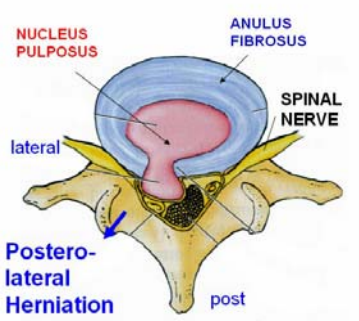

SUMMARY OF SOME FEATURES OF VERTEBRAE ON CT, LANDMARKS AND SOME CLINICAL SIGNS

Vertebra	ID Features on CT	Clinical, Associated Structures on CT
Cervical (7)	**Foramina Tranversaria transmit Vertebral Artery** (C1-C6) **C1** = Atlas - **no body** **C2** = Axis - **dens** C7 = Vertebra prominens (long palpable spine)	1) **Damage to vertebral artery** - brainstem symptoms **2) Upper cervical fracture** (C1 or dens of C2) - **Quadriplegia**; **3) Disc Herniation in Lower Cervical Vertebrae** - symptoms in upper extremity (Brachial plexus)
Thoracic (12)	**Ribs abut bodies** (head of rib), **transverse processes** (tubercle of rib);	**Landmark: Thoracic aorta** anterolateral to bodies
Lumbar (5)	**Large bodies; No surrounding bones**	**Landmarks: Erector spinae** posterior; **Psoas major** lateral; **IVC** and **Abdominal aorta** anterior to bodies

2) GROSS ANATOMY OF SPINAL CORD AND SPINAL NERVES

Syndrome/ Procedure	Anatomy	Structures	Clinical, ID Features on CT
Spinal Nerve Compres-sion	**Convention**: Cervical spinal nerves **C1-C7 exit Above** corresponding vertebrae; **C8 and All other spinal nerves exit Below** vertebrae	**Dermatomes** - area of distribution of single nerve root to skin; **[V1 - Face (above eyes *)** **V2 - Face (below eyes*)** **V3- Face (below mouth)*]** **C5 - Shoulder** **C6 - Thumb** **C8 - Little finger** **T1 - Armpit** **T4 - Nipple** **T7 - Xiphoid** **T10 - Umbilicus** **L1 - Inguinal lig.** **L4 - Big toe** **S1 - Little toe** **[* Note: V - also Oral, Nasal Cav., Cranial Dura Mater - headache]**	**Symptoms of compression of nerve root - Paresthesia, pain, sensory loss, hyporeflexia, muscle weakness** 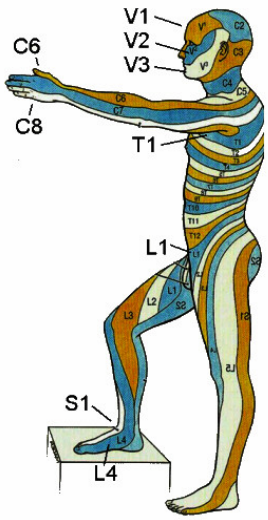 **Note:** overlap of dermatomes in region of trunk: sensory loss in trunk only with Two Thoracic spinal roots
Lumbar Puncture	Inferior end of Spinal Cord = **Conus medullaris**	Conus medullaris at 1. In **Newborn**, vertebral level **L3** 2. In **Adult**, conus at vertebral level **L1**	**Lumbar Puncture** done below Conus Medullaris (region of Cauda Equina); Level: **1. Children** - **L4-L5** **2. Adult** - **L3-L4 or L4-L5**
Metastasis to Vertebral Column	**Epidural Space** (outside Dura) Dura is separated from inner side of vertebral canal; Note: in Skull, there is no epidural space	**Internal Vertebral Venous plexus** - inside vertebral canal in Epidural Space; drains to **External Venous plexus** (outside vertebrae) by Radicular and Intervertebral veins	**Disease processes (ex. cancer) can spread to vertebrae** and spinal cord v**ia anastomoses of Vertebral venous plexus and intervertebral veins** with **Lumbar veins** (ex. carcinoma of prostate can metastasize to vertebral column) .

LAYERS PENETRATED IN EPIDURAL ANESTHESIA/LUMBAR PUNCTURE (superficial to deep)

1. Skin, 2. Superficial Fascia, (3. Supraspinous ligament, 4. Interspinous ligament)
5. Ligamentum Flavum (sudden yield, first 'pop') - now inside vertebral canal in Epidural space
6. Epidural Space - **STOP HERE FOR EPIDURAL ANESTHESIA**
7. Dura Mater (sudden yield, second 'pop')
(8. Arachnoid - adherent to inner side of dura mater)
9. **Subarachnoid Space (Lumbar Cistern)** - **STOP HERE FOR LUMBAR PUNCTURE/SAMPLE CSF**

3) SPINAL REFLEXES AND DIAGNOSIS OF UPPER AND LOWER MOTOR NEURON LESIONS

REFLEX	STIMULUS/SENSE ORGAN(S) EXCITED	RESPONSE	CLINICAL/ABNORMAL RESPONSES
Stretch (Myotatic, Deep Tendon) Reflex	Rapid Stretch of muscle (test: tap on muscle tendon) Excites Muscle Spindle Primary (Ia) and Secondary (II) sensory neurons (NOT Golgi Tendon Organ)	Stretched muscle contracts rapidly (monosynaptic connection); also excite synergist and Inhibit antagonist Note: Gamma motor neurons can enhance stretch reflexes (Gamma dynamic motor neurons specifically enhance Ia sensitivity; tell patient to relax before test)	Hyporeflexia - decrease in stretch reflexes occurs in Lower Motoneuron Diseases, Muscle atrophy etc. Hyperreflexia - (increase) - characteristic of Upper Motor Neuron lesions (ex. spinal cord injury, damage Corticospinal tract); note: Clonus = hyperreflexia with repetitive contractions to single stimulus
Autogenic Inhibition (Inverse Myotatic Reflex)	Large force on tendon excites Golgi Tendon Organ Ib (test: pull on muscle when resisted)	Muscle tension decreases; Also inhibit synergist muscles; excite antagonist muscles	Clasped Knife Reflex - occurs in Upper Motor Neuron lesions - forceful stretch of muscle is first resisted then collapses
Flexor Reflex	Sharp, painful stimulus, as in stepping on nail; Excites - Cutaneous and pain receptors	Limb is rapidly withdrawn from stimulus; protective reflex; also inhibit extensors of same limb and excite extensors of opposite limb (Crossed Extensor Reflex)	Babinski sign- toes extend (dorsiflex) to cutaneous stimulus of sole of foot (normally plantar flex); characteristic of Upper Motor Neuron lesion

LOWER AND UPPER MOTOR NEURON LESIONS

Lesion	Structure Affected	Symptoms	Examples
Lower Motor Neuron Lesion (Flaccid Paralysis)	Lower Motor Neurons = Alpha Motor neurons with axons that innervate skeletal muscles	Muscle is effectively denervated: 1) Decrease Stretch (Deep Tendon) Reflexes 2) Decreased Muscle Tone 3) Muscle atrophy; Fasciculations (twitches) precede atrophy 4) No Babinski sign	1) Compression of spinal nerve 2) Poliomyelitis - viral infections affecting motor neurons
Upper Motor Neuron Lesion (Spastic Paralysis)	Upper Motor Neurons = All descending neurons that affect Lower Motor Neurons (ex. Corticospinal, Reticulospinal neurons)	Disrupt voluntary control and regulation of reflexes (remove inhibition): 1) Increase Stretch (Deep Tendon) Reflexes 2) Increased Muscle Tone 3) No Fasciculations 4) Babinski sign 5) Clasped Knife Reflex	1) Damage to Corticospinal (corticobulbar) tracts - can occur at all levels from cortex to spinal cord (including brainstem)

Note: Some diseases produce both Upper and Lower Motor Neuron Symptoms - (ex. ALS Amyotrophic Lateral Sclerosis)

REVIEW QUESTIONS ON VERTEBRAE, SPINAL CORD, SPINAL NERVES

1- ____ A 28-year-old-women presented to the hospital emergency room with intense lower back spasms in the context of coughing during an upper respiratory infection. Review of her medical records showed that she had experienced progressive lower back problems for the preceding 6 years. She had gained 15 pounds during that period but was not morbidly obese. MRI scan of the vertebral column (image above) showed an exaggerated anterior-posterior curvature. Based upon this image, the radiologist would diagnose this as which of the following conditions?

A. Scoliosis in vertebrae L3-S1
B. Kyphosis in vertebrae T12-L3
C. Increased lordosis in vertebrae L3-S1
D. Increased lordosis in vertebrae T12-L1
E. Scoliosis in vertebrae T12-L3

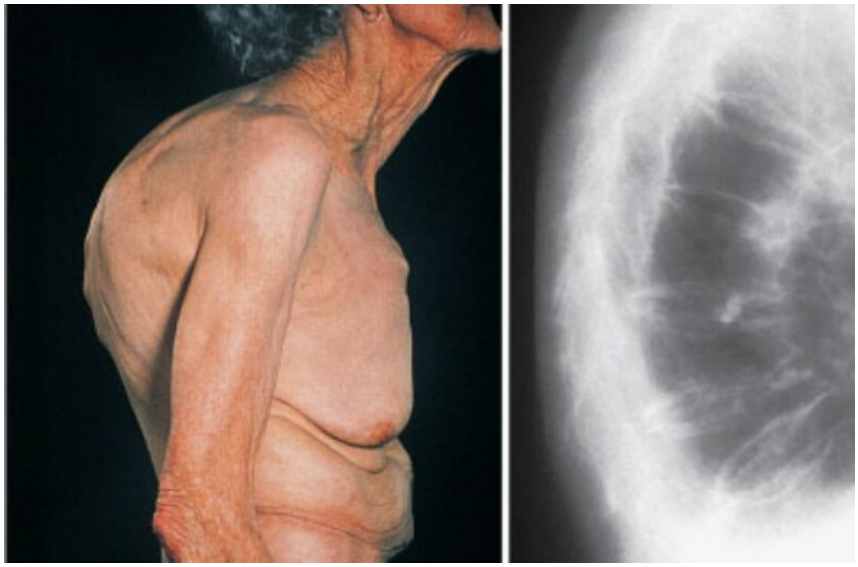

2.___ A 70 year old female with no health insurance was seen at a community based clinic. She complained of stooping of her posture (photo left above). She stated that the condition had been developing over a number of years. However, the deformity had increased to the point that she had difficulty holding her neck upright. She had also begun experiencing chronic back pain. The image (above right) is a lateral view xray of the thoracic spine. Which of the following would be a diagnosis of this condition?

A. Congenital scoliosis
B. Degenerative kyphosis associated with osteoporosis
C. Post-traumatic fracture of bodies of thoracic vertebrae
D. Scoliosis due to the presence of a hemivertebra
E. Degenerative lordosis of thoracic vertebrae

3. ____ A 45 year old man was helping a friend move a piano when he experienced sudden lower back pain. Physical examination showed weakness in dorsiflexion of the foot. The MRI image of the lumbosacral spine (above) shows a structure pressing against the cauda equina. The herniated structure would be immediately adjacent to which of the following spinal ligaments?

A. Anterior longitudinal ligament
B. Ligamenta flava
C. Interspinous ligament
D. Posterior longitudinal ligament
E. Supraspinous ligament

4.___ A 2.2 kg girl was born at 34 weeks and showed severe respiratory distress. The neonate had a malformed thorax that limited normal respiration. The skeleton was imaged by CT and showed multiple abnormalities. 3D reconstruction (shown above) of the spine showed a distinct discontinuity in the vertebrae (arrow). Which of the following describes this discontinuity?

A. Lordosis due to the presence of a 'hemivertebra'
B. Scoliosis due to the presence of a 'hemivertebra'
C. Congenital Kyphosis
D. Exaggerated primary curvature
E. Exaggerated secondary curvature in the lumbar region

5.____A 25-year-old rugby player injured his neck while tackling another player. He felt numbness over the region of the thumb on the palmar surface that persisted for several days.. Physical examination by his physician showed weakness in the biceps muscle. These symptoms could result a sign of herniation of an intervertebral disc located between vertebrae at which of the following levels?

A. C3-C4
B. C4-C5
C. C5-C6
D. C6-C7
E. C7-T1

6.____ A newborn baby born at 37 weeks is noted to be unwell, feeding poorly and is jittery, with a temperature of 38°C. A clinical diagnosis of early sepsis is made and a lumbar puncture to sample cerebrospinal fluid (CSF) is suggested on the ward round as a part of sepsis evaluation. To perform the procedure of lumbar puncture (spinal tap) safely in a newborn, the needle must be inserted between which of the following vertebrae?

A. T12-L1
B. L1-L2
C. L2-L3
D. L3-L4
E. L4-L5

7. ____ A 24-year-old-patient is seen for a routine neurological exam. The patient is a medical student who has been studying intensely for Step 1 board (or Final) examinations. Testing of patellar tendon reflexes (deep tendon reflex) shows bilateral, mild hyperreflexia (scored 3). The physician suspects that this is not pathological but due to increased activation of Gamma motor neurons associated with nervousness and anxiety. Which of the following is an action of Gamma motor neurons that could produce the mild hyperreflexia?

A. Increase sensitivity of Golgi tendon organs
B. Increase sensitivity of Ia fibers in muscle spindles
C. Directly produce contraction of all muscle cells
D. Increase sensitivity of free nerve endings in muscles
E. Produce relaxation of muscle cells in muscle spindles

8. ___ Both Lower motor neuron and Upper motor neuron lesions can cause muscle paralysis. Differential diagnosis is often complex and based upon a number of tests. Which of the following is a characteristic of Lower motor neuron lesions which does not occur in Upper motor neuron lesions?

A. Hyperreflexia
B. Fasciculations
C. Increased muscle tonus
D. Clasped knife reflexes
E. Babinski sign

9. ____ A patient who was treated for advanced carcinoma of the prostate begins to experience back pain. An MRI image of a lateral view of the vertebral column is shown above. Which of the following could serve as an anatomical pathway by which metastasis could have spread to the structures indicated by the arrow?

A. External Iliac vein
B. Renal vein
C. Testicular vein
D. Lumbar veins
E. Deep Femoral vein

10. ____ A first year resident in OBGYN, who has been on call for 18 hours, is asked to administer an epidural anesthetic to a patient prior to delivery. As the needle is being inserted, the resident struggles to remember the anatomy of the vertebral column to know when to stop and administer the anesthetic. Which of the following is the last structure the needle should pass through in administering an epidural anesthetic?

A. Anterior Longitudinal Ligament
B. Posterior Longitudinal Ligament
C. Supraspinous Ligament
D. Ligamentum flavum
E. Nuchal Ligament

11. ____ A patient experiences intermittent numbness of the big toe. The physician suspects that the cause may be due to osteophyte formation at an intervertebral foramen. At which of the following levels would foraminal encroachment by osteophyte formation produce numbness of the big toe?

A. Intervertebral foramen at L1-L2
B. Intervertebral foramen at L2-L3
C. Intervertebral foramen at L3-L4
D. Intervertebral foramen at L4-L5
E. Intervertebral foramen at T12-L1

Key to Questions on Vertebrae, Spinal Cord, Spinal Nerves

1. C
2. B
3. D
4. B
5. C
6. E
7. B
8. B
9. D
10. D
11. D

REVIEW GROSS ANATOMY OF VERTEBRAE, SPINAL CORD AND SPINAL REFLEXES

1) Vertebrae

- Spinal Curvatures - normal and abnormal
- Vertebral Ligaments Herniation of Intervertebral Discs
- Regional Specializations/Landmarks of Vertebrae on CT

2) Spinal nerves

- Nerve Compression and Dermatome map
- Epidural Anesthesia and Lumbar Puncture (CSF)
- Spread of Disease to Vertebrae via Venous System

3) Spinal reflexes

- diagnosis of Upper and Lower Motor Neuron lesions

1) VERTEBRAE - NORMAL PRIMARY SPINAL CURVATURE

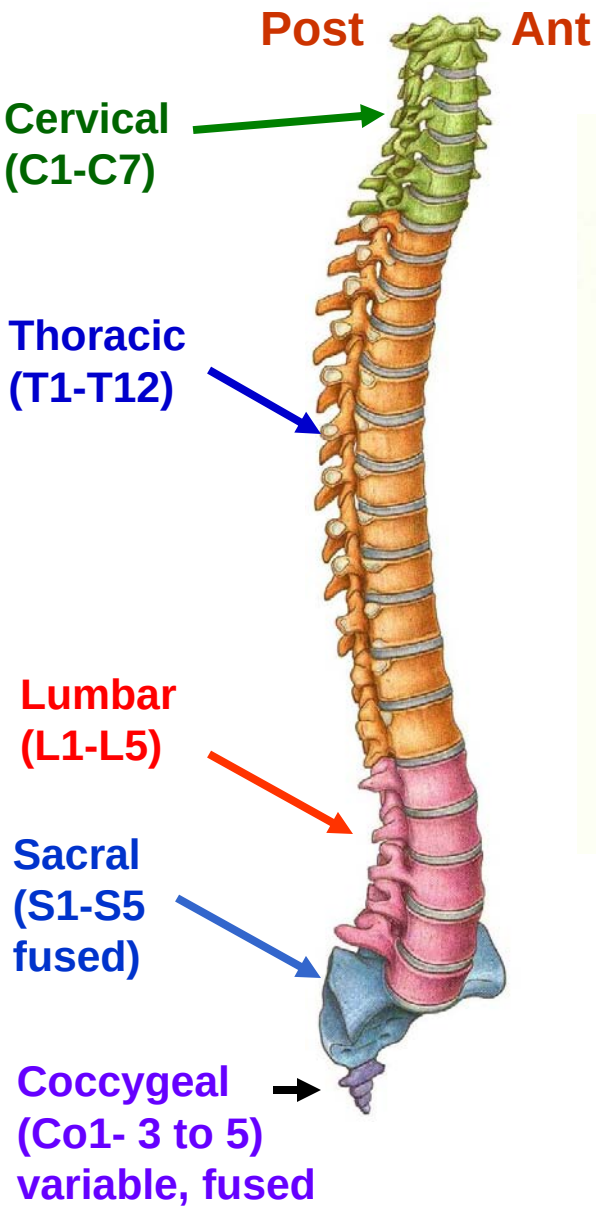

Midterm

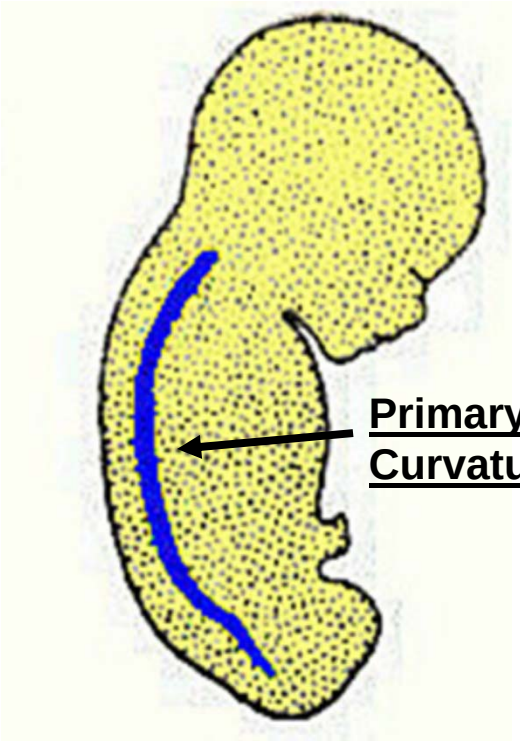

Primary Curvature = Concave Anterior - fetal curvature

Adult

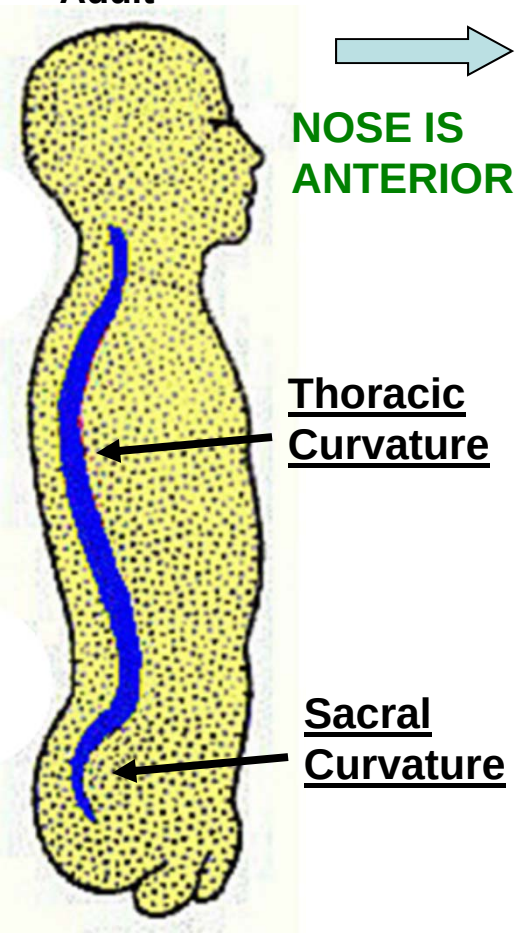

Primary Curvature retained in Adult Thorax, Sacrum

NORMAL SECONDARY CURVATURES - Develop in early childhood

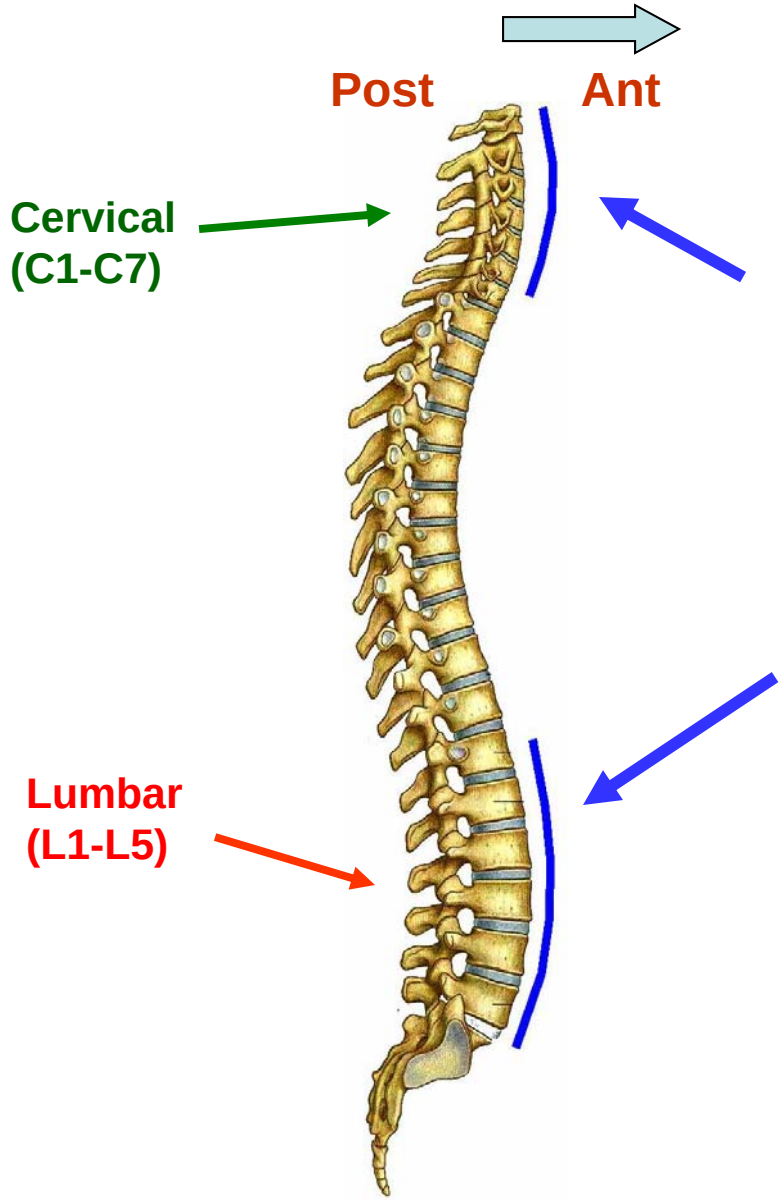

Cervical curvature - concave posteriorly - helps support head

Lumbar curvature
- **concave posteriorly**
- **develops with walking**
- **helps support trunk, upper body**

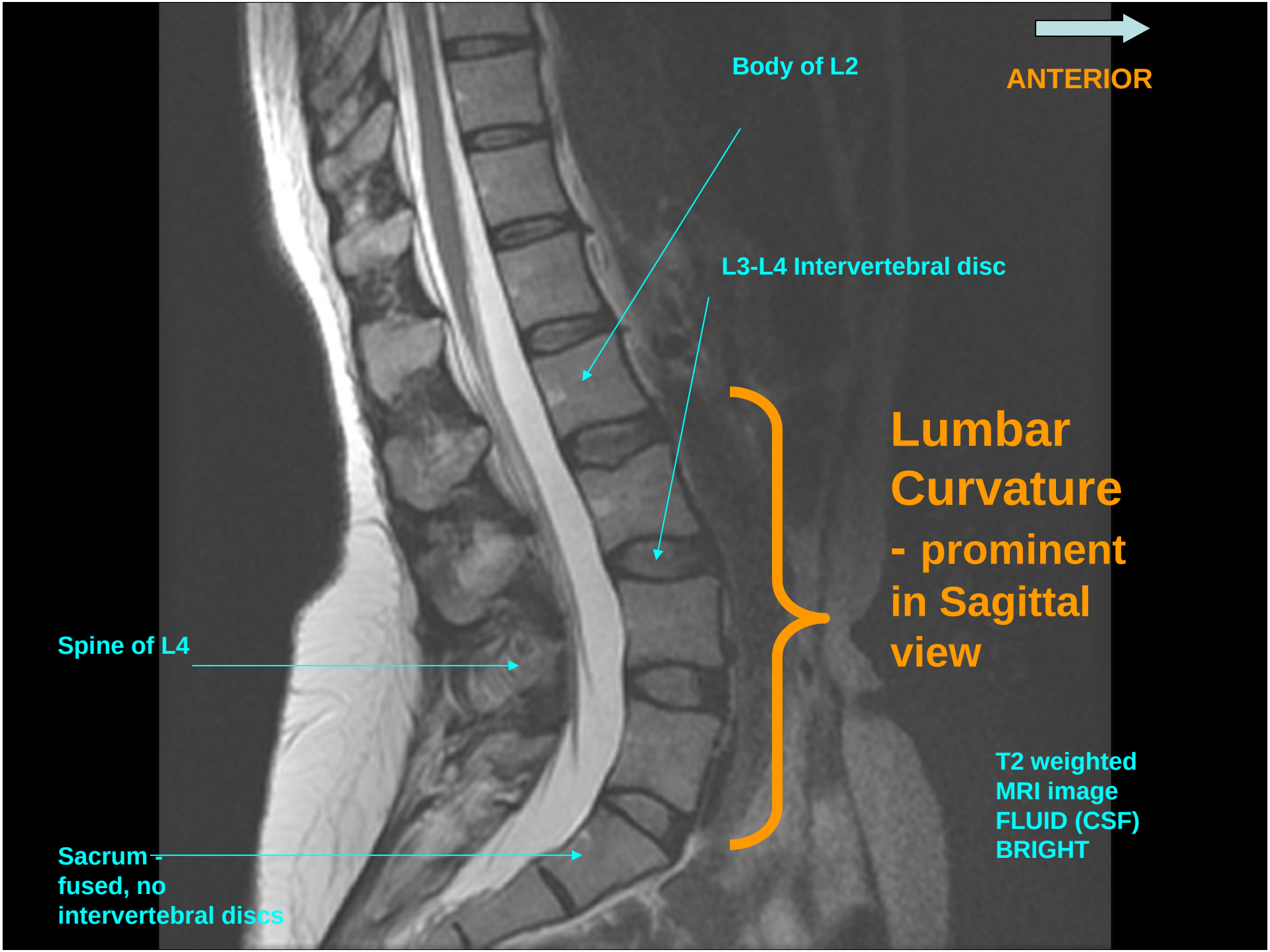
ANTERIOR
Body of L2
L3-L4 Intervertebral disc
Lumbar Curvature
- prominent in Sagittal view
Spine of L4
Sacrum - fused, no intervertebral discs
T2 weighted MRI image FLUID (CSF) BRIGHT

ABNORMAL CURVATURES

KYPHOSIS

SCOLIOSIS

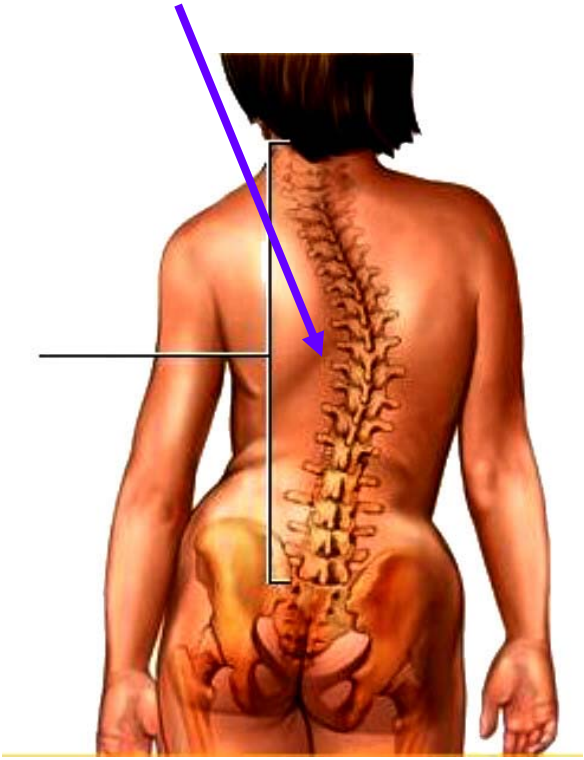

LORDOSIS

KYPHOSIS - ‘hump’ back - EXAGGERATED curvature CONCAVE ANTERIORLY IN THORAX in elderly - cause Osteoporosis, etc.

SCOLIOSIS- LATERAL CURVATURE - can be due to 'presence of hemivertebra' - one half of a vertebra fails to develop

LORDOSIS - EXAGGERATED POSTERIOR CURVATURE - LUMBAR - cause obesity, etc.; (normal in pregnancy)

LIGAMENTS OF VERTEBRAE

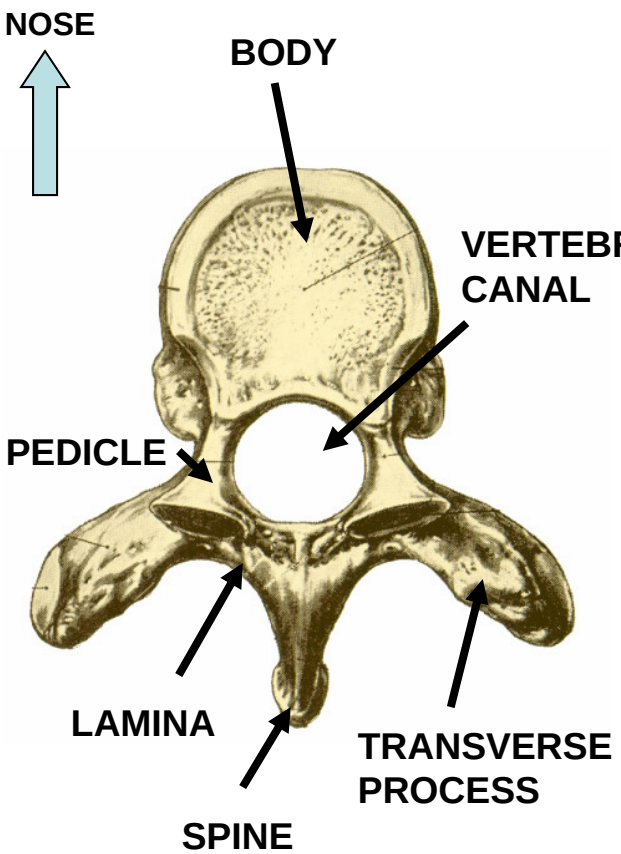

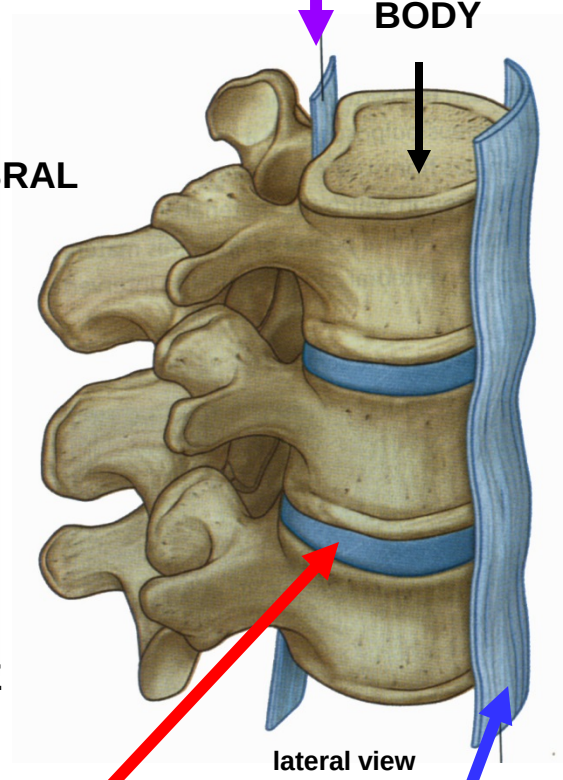

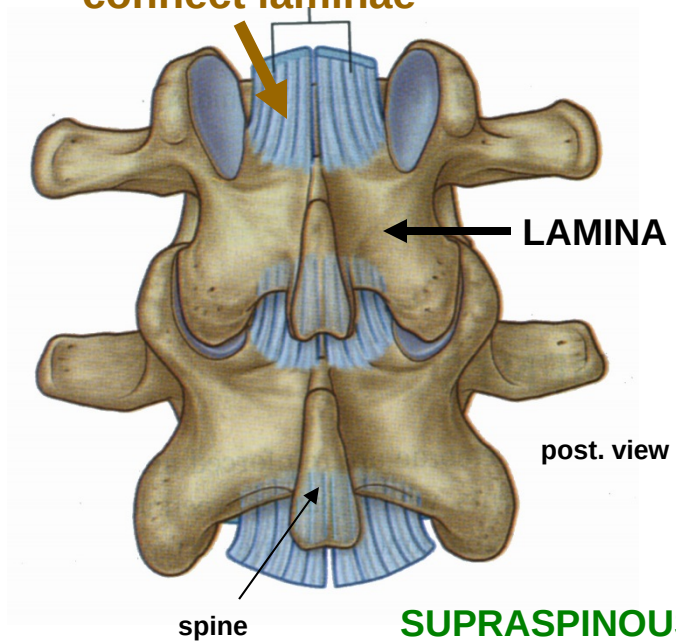

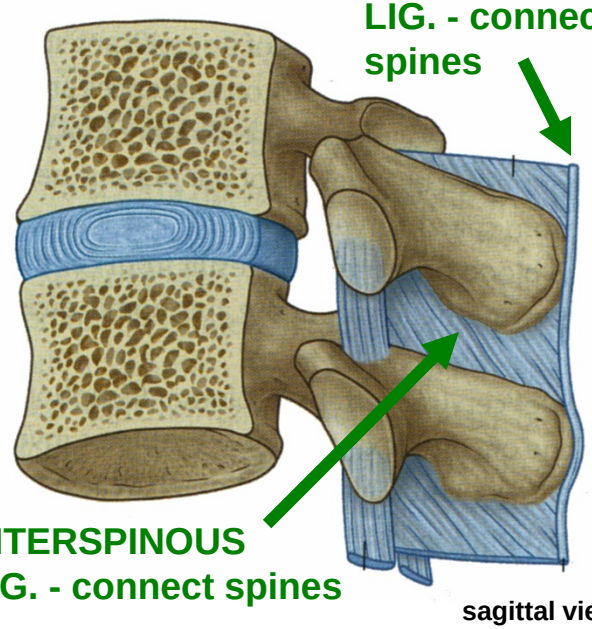

ANATOMY OF HERNIATION OF NUCLEUS PULPOSUS OF INTERVERTEBRAL DISCS

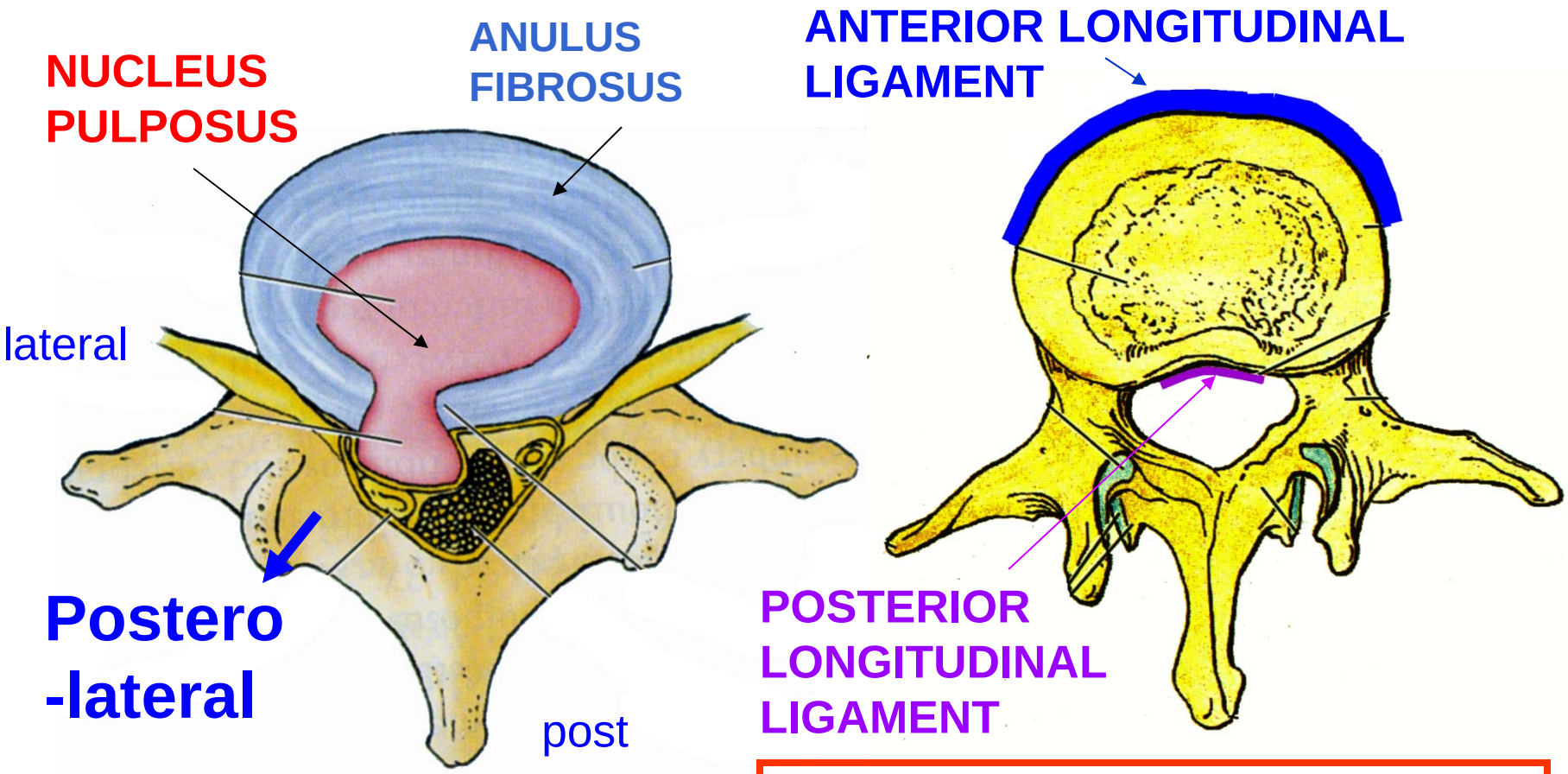

Herniation typically occurs in a Postero-Lateral Direction: Post. Longitudinal Ligament is narrow, Ant. Longitudinal Ligament is broad; can produce nerve compression at intervertebral foramen

FEATURES OF CERVICAL VERTEBRA ON CT

Body is small, Vertebral canal is large

FORAMEN TRANSVERSARIUM TRANSMITS VERTEBRAL ARTERY

Foramen Transversarium

Body

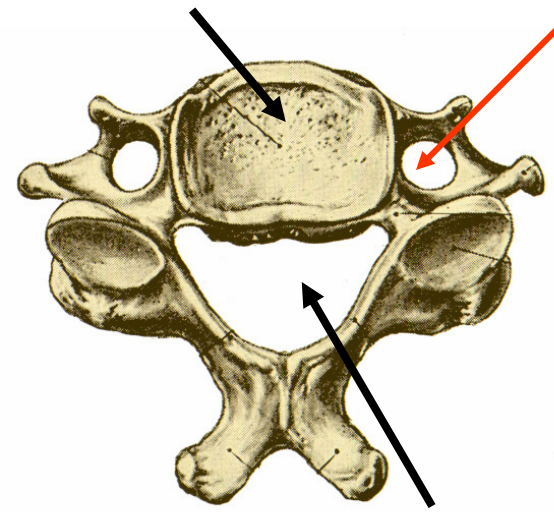

Vertebral Canal

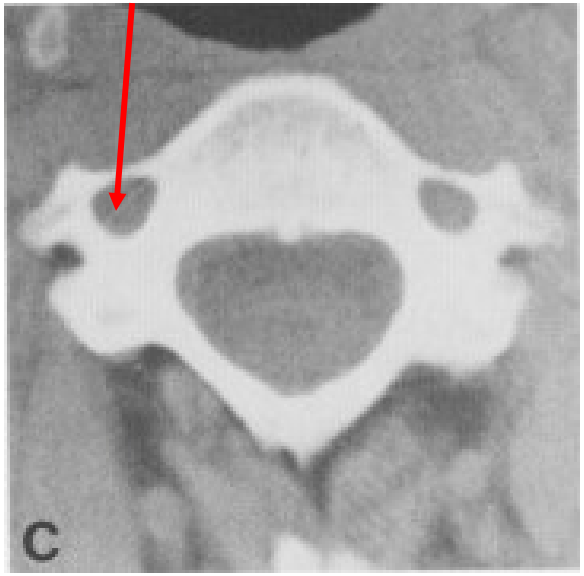

Vertebral A.

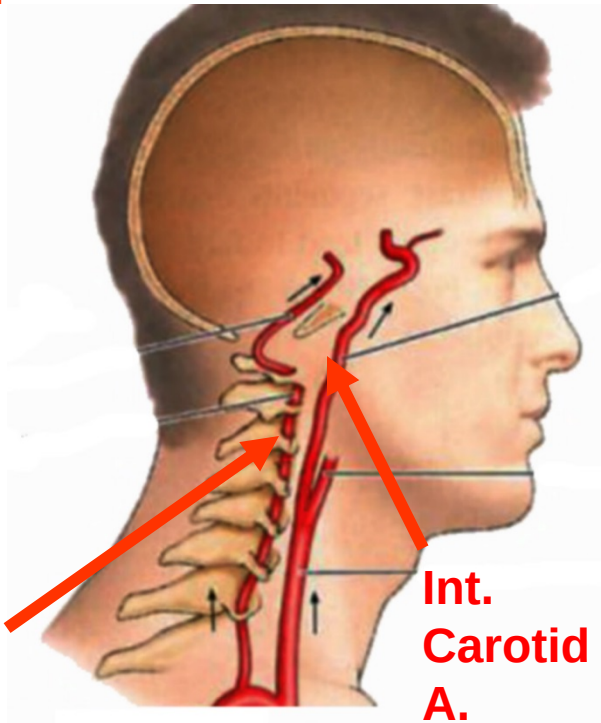

Int. Carotid A.

Damage to Cervical Vertebrae (ex. car accident) can <u>damage Vertebral artery</u> - neurological symptoms of brainstem lesion

FEATURES OF CERVICAL VERTEBRA ON CT

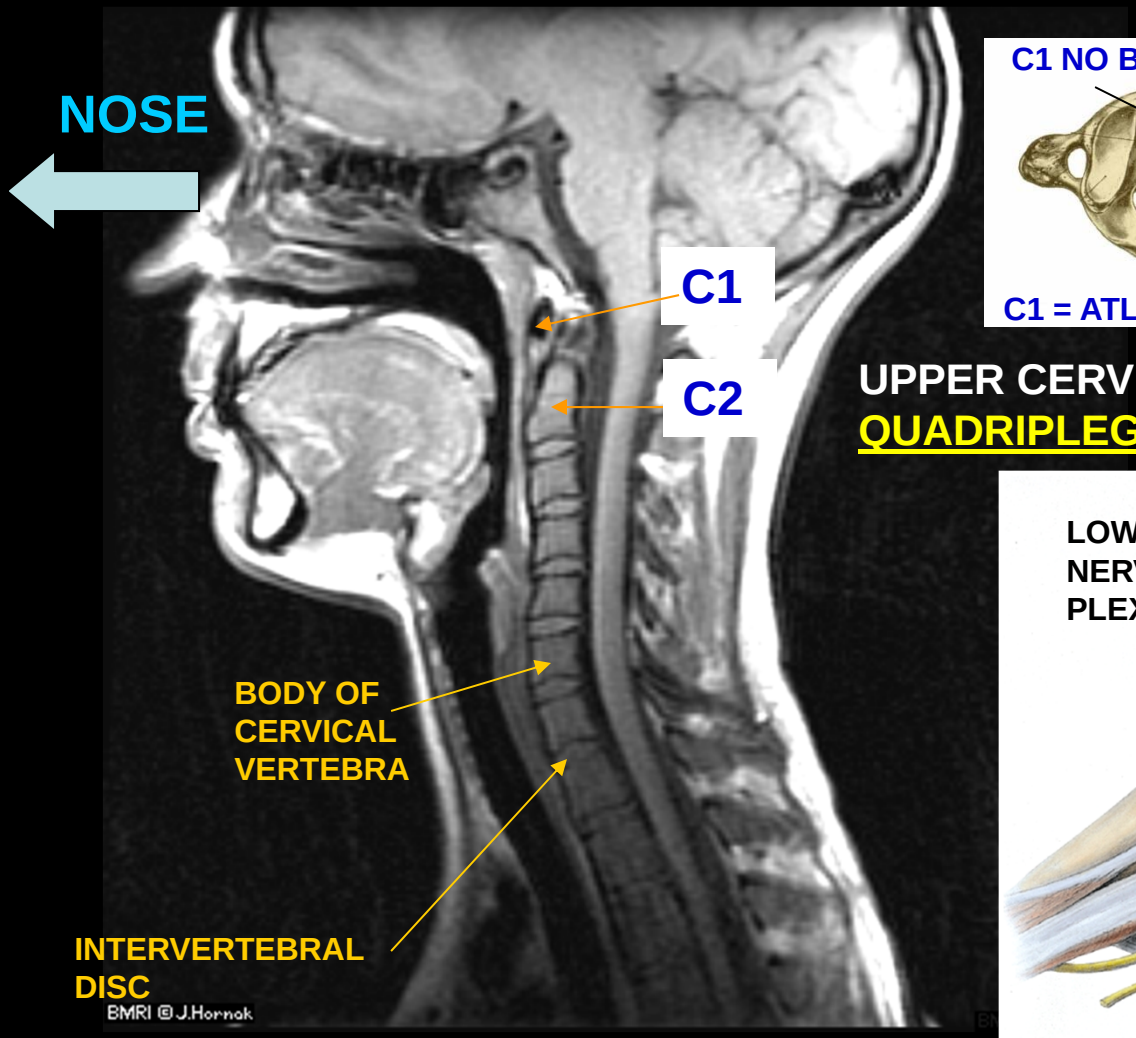

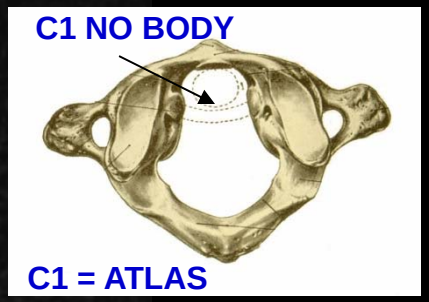

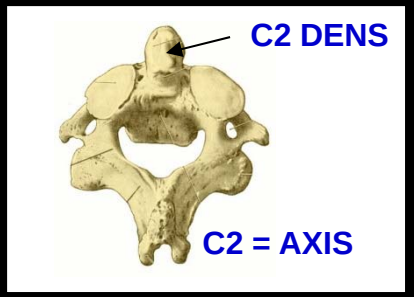

UPPER CERVICAL FRACTURE (C1 or C2) - **QUADRIPLEGIA**; bilateral sensory loss in extremities

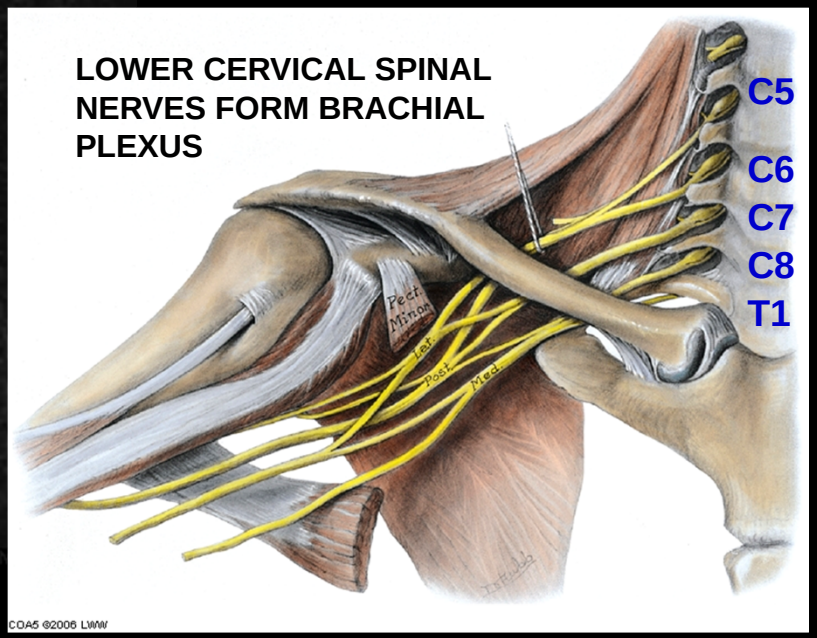

HERNIATION OF LOWER CERVICAL DISCS CAN PRODUCE SYMPTOMS IN UPPER EXTREMITY

LANDMARKS, FEATURES OF THORACIC VERTEBRA ON CT

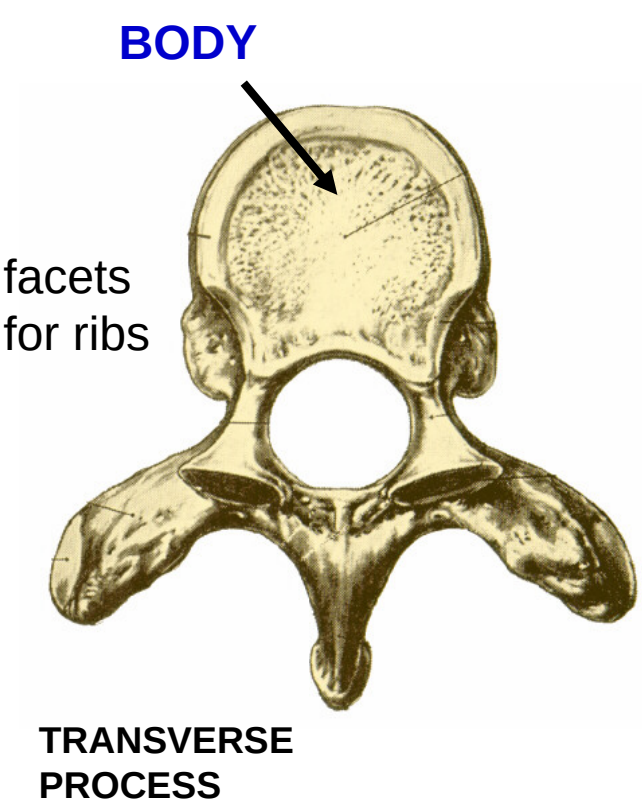

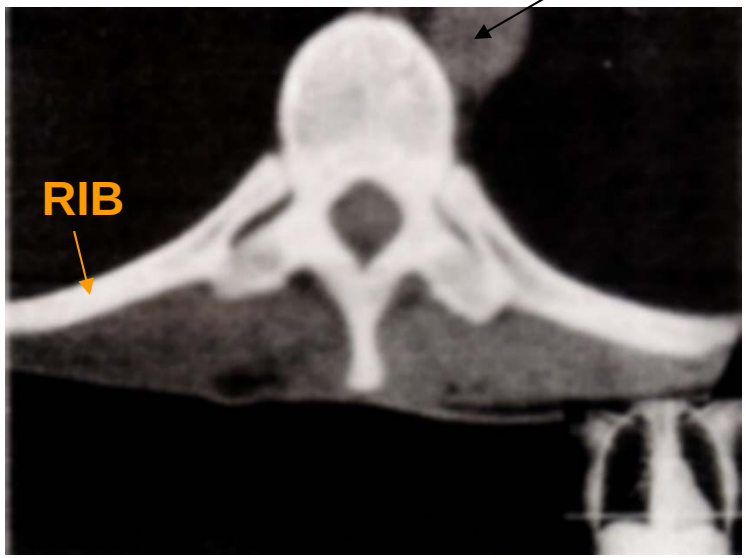

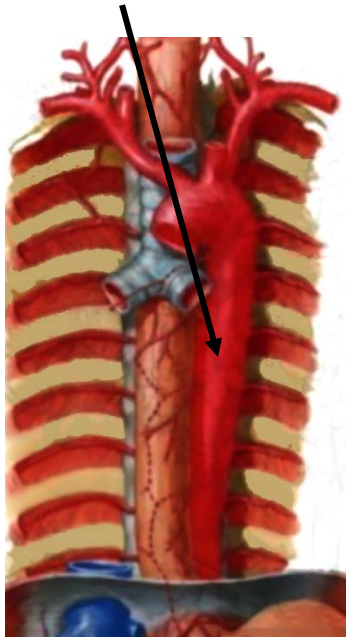

ID: Ribs abut bodies (head of rib), **transverse processes** (tubercle of rib);

Landmark: Thoracic aorta anterolateral to bodies - extends down from arch of Aorta (located at Sternal Angle - T45 intervertebral disc)

FEATURES OF LUMBAR VERTEBRA ON CT

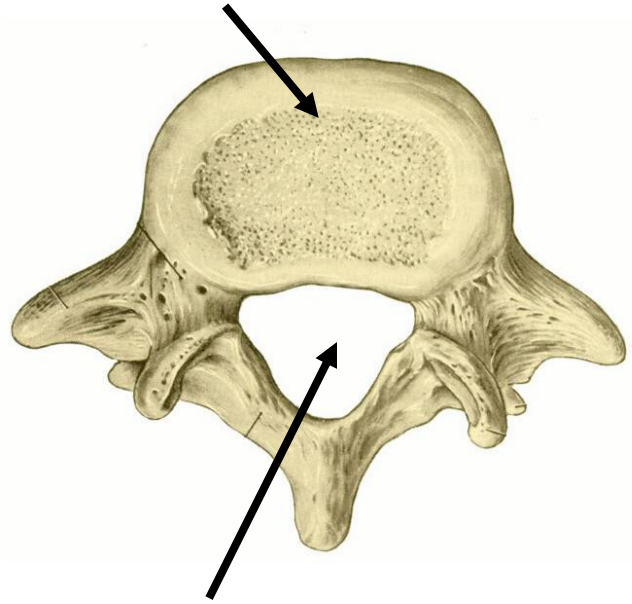

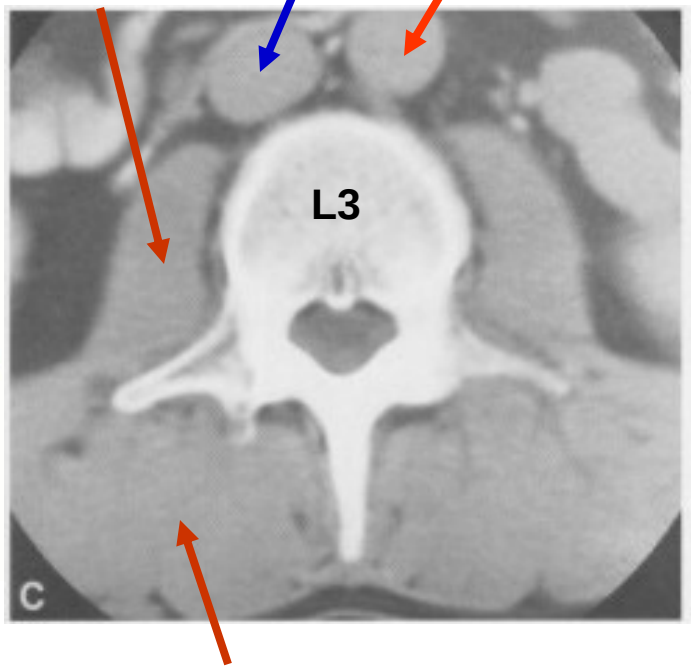

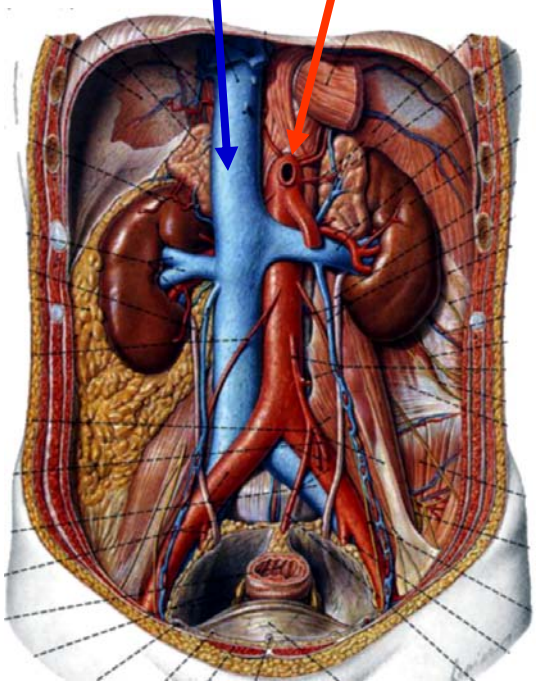

ID: Large bodies; No surrounding bones

Landmarks:
Erector spinae posterior;
Psoas major anterior
IVC and Abdominal Aorta anterior to body

2) GROSS ANATOMY OF SPINAL CORD AND SPINAL NERVES

VERTEBRAE

Cervical (C1-C7)

Thoracic (T1-T12)

Lumbar (L1-L5)

Sacral (S1-S5 fused)

Coccygeal (Co1- 3(5)) fused

SPINAL NERVES

Cervical (C1-C8)

Thoracic (T1-T12)

Lumbar (L1-L5)

Sacral (S1-S5)

Coccygeal (Co1)

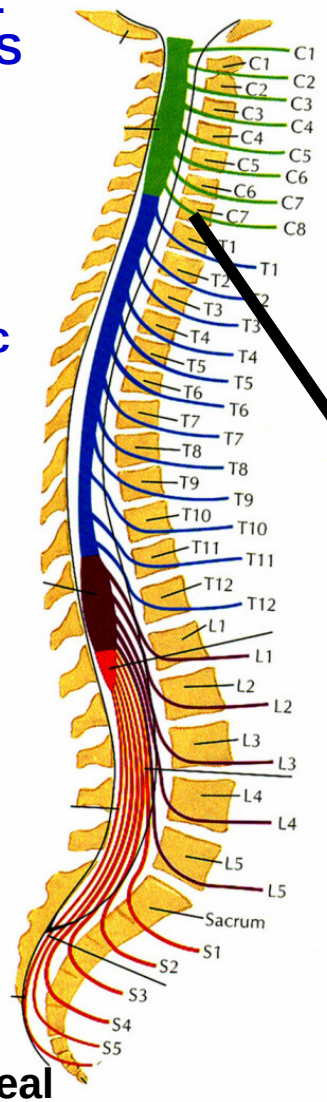

CONVENTION FOR NAMING LEVELS:

C1 - C7: above vertebra
C8 - all others: below vertebra

Spinal nerves C1-C7 above vertebra

C8 and all others below vertebra

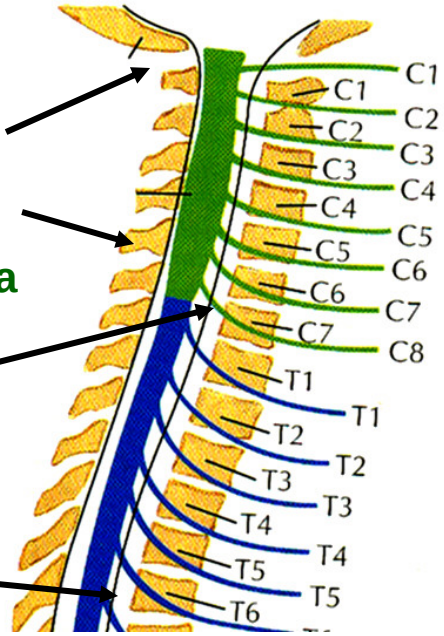

SPINAL NERVE COMPRESSION - SENSORY LOSS - DERMATOME MAP

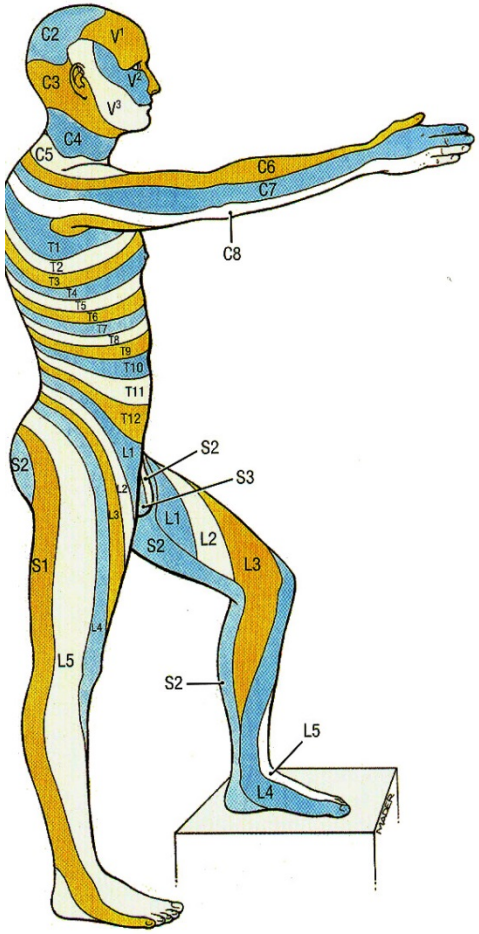

THUMB = C6

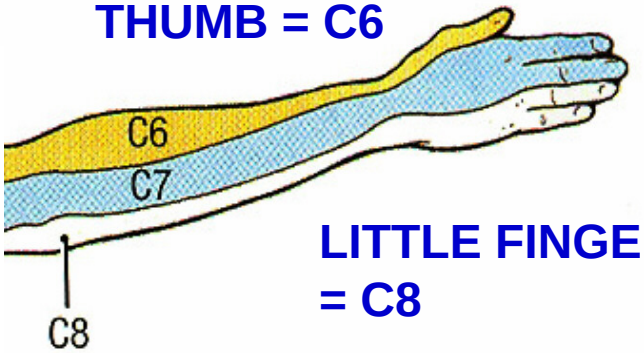

LITTLE FINGER = C8

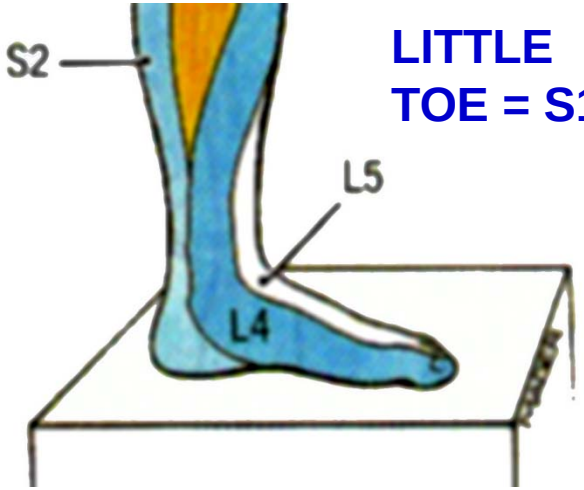

LITTLE TOE = S1

BIG TOE = L4

V1 - Face (above eyes)
V2 - Face (below eyes)
V3- Face (below mouth)
C5 - Shoulder
<u>C6 - Thumb</u>
<u>C8 - Little finger</u>
T1 - Armpit
T4 - Nipple
T7 - Xiphoid
T10 - Umbilicus
L1 - Inguinal lig.
<u>L4 - Big toe</u>
<u>S1 - Little toe</u>

Note: V - also Nasal, Oral cavities, Cranial dura mater

Clinical: Symptoms of compression of spinal root - Paresthesia (ex. tingling), pain, sensory loss, hyporeflexia, muscle weakness

Note: Overlap of dermatomes in region of trunk: sensory loss in trunk only with compression of two Thoracic spinal roots.

REVIEW QUESTIONS SPINAL NERVE COMPRESSION

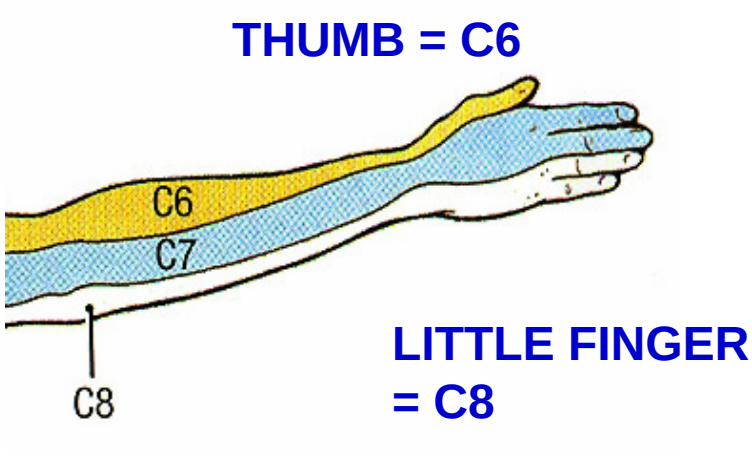

Questions: What is the level of a herniated disc that would produce numbness of Thumb? Little finger? Big Toe?

Answers: **Thumb, Disc C5-C6 above vertebra C6;**
Little Finger, Disc C7-T1 below vertebra C7;
Big Toe, Disc L4-L5 below vertebra L4

Recall: C1 - C7: above vertebra; C8 - all others: below vertebra

CONUS MEDULLARIS

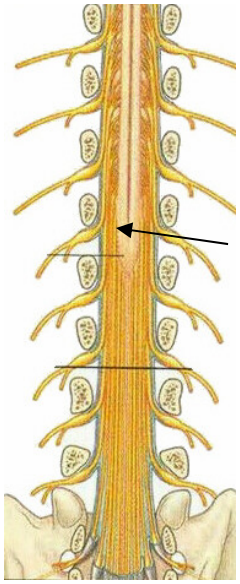

CONUS MEDULLARIS = INFERIOR END OF SPINAL CORD

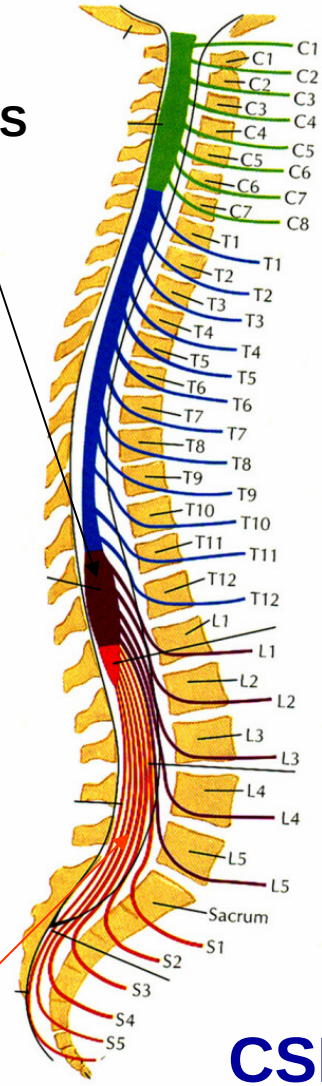

Conus medullaris -

1. Newborn, Conus medullaris is located at vertebral level L3
2. Adult, Conus Medullaris is located at vertebral level L1

ROOTS OF CAUDA EQUINA

LUMBAR PUNCTURE - BELOW LEVEL OF CONUS MEDULLARIS

SUPERIOR TO CONUS MEDULLARIS

CSF

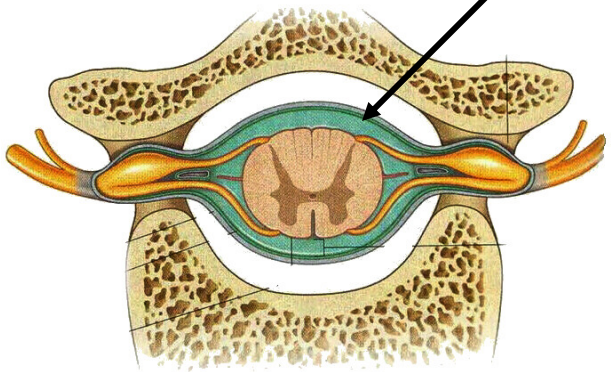

Level of Lumbar Puncture

Adult - between L3-L4 or L4-L5

INFERIOR TO CONUS MEDULLARIS

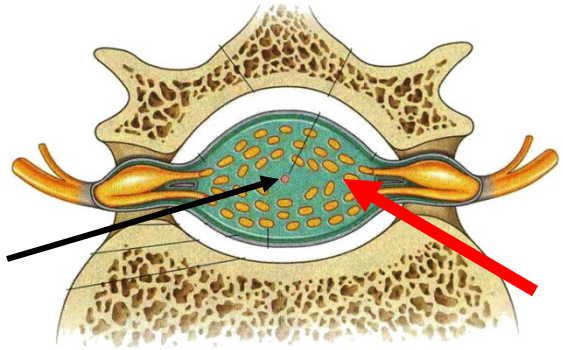

CSF

Children - MUST be done at L4-L5

ROOTS OF CAUDA EQUINA

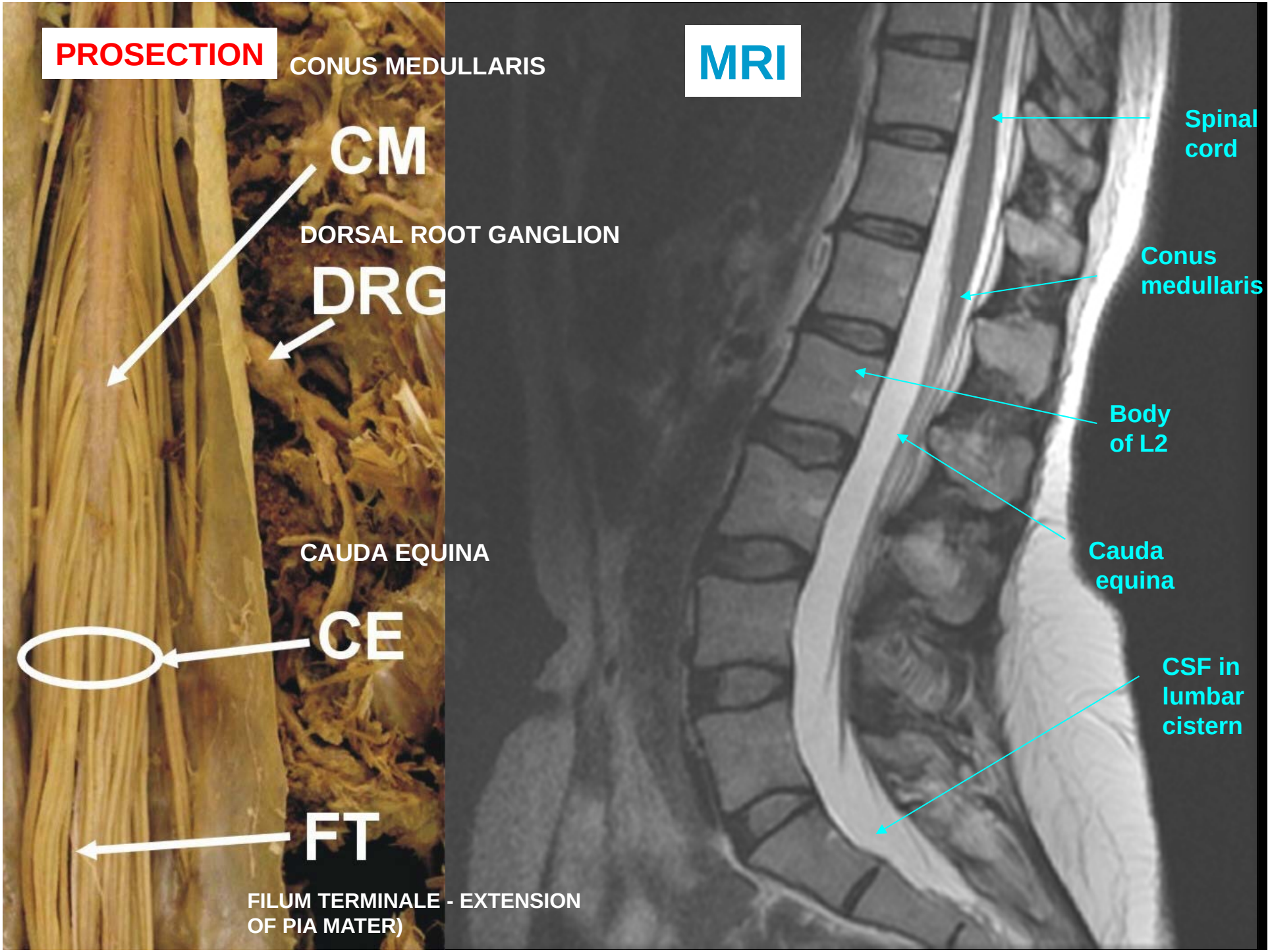
PROSECTION
CONUS MEDULLARIS
CM
DORSAL ROOT GANGLION
DRG
CAUDA EQUINA
CE
FT
FILUM TERMINALE - EXTENSION
OF PIA MATER)
MRI
Spinal
cord
Conus
medullaris
Body
of L2
Cauda
equina
CSF in
lumbar
cistern

SEQUENCE OF STRUCTURES PENETRATED IN EPIDURAL ANESTHESIA, LUMBAR PUNCTURE

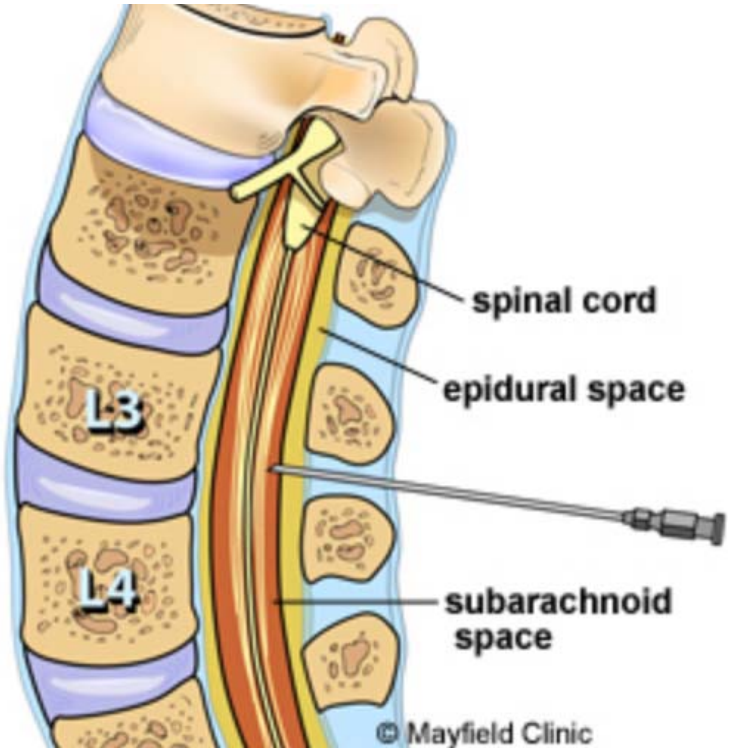

1. Skin, 2. Superficial Fascia, (3. Supraspinous ligament, 4. Interspinous ligament)
5. Ligamentum Flavum (sudden yield, first 'pop') - now inside vertebral canal
6. Epidural space - STOP HERE FOR EPIDURAL ANESTHESIA
7. Dura mater (sudden yield, second 'pop')
8. Arachnoid - adherent to inner side of dura mater
9. Subarachnoid space (Lumbar cistern)- STOP HERE FOR LUMBAR PUNCTURE/SAMPLE CSF

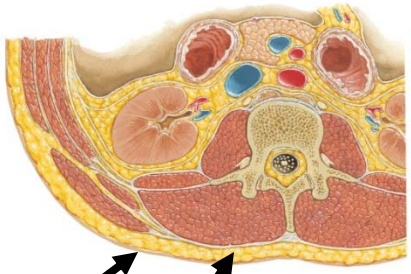

1. Skin
2. Superficial Fascia

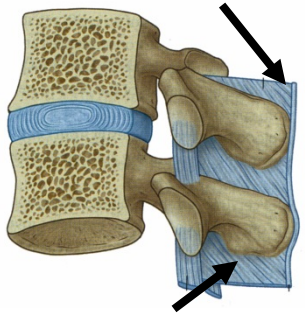

3. Supraspinous ligament
4. Interspinous ligament

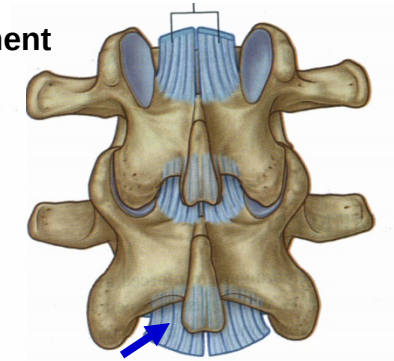

5. Ligamentum Flavum (sudden yield, first 'pop')

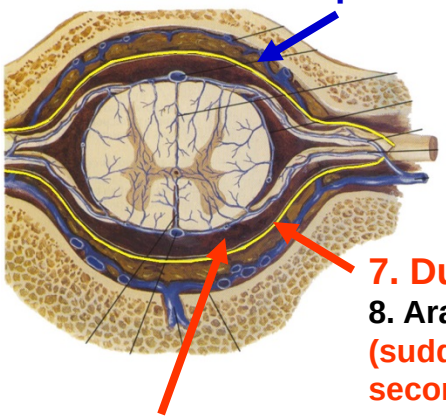

6. Epidural space
7. Dura and
8. Arachnoid (sudden yield, second pop)
9. Subarachnoid space

ARTERIES AND VEINS OF SPINAL CORD

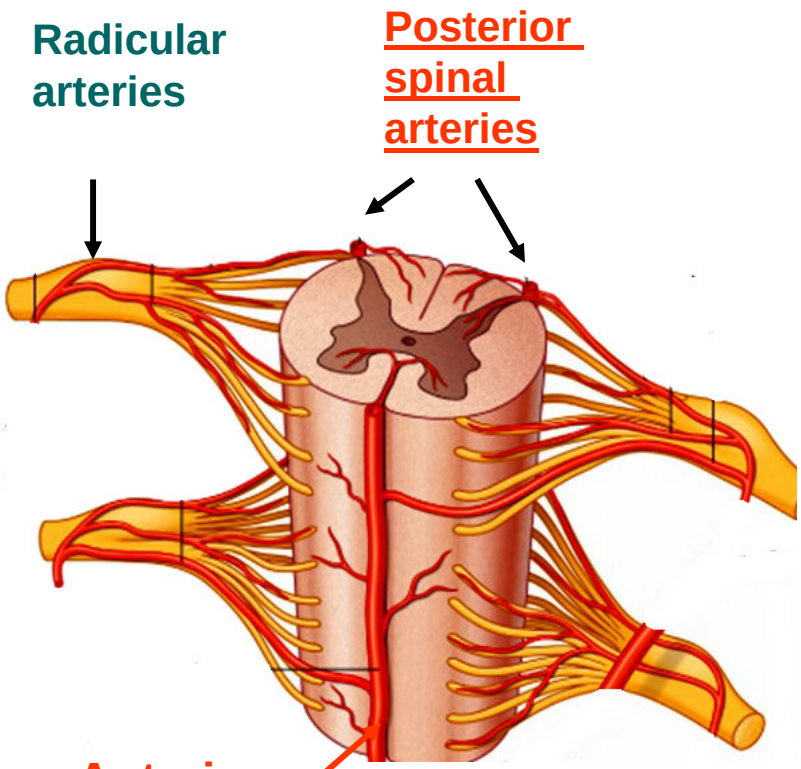

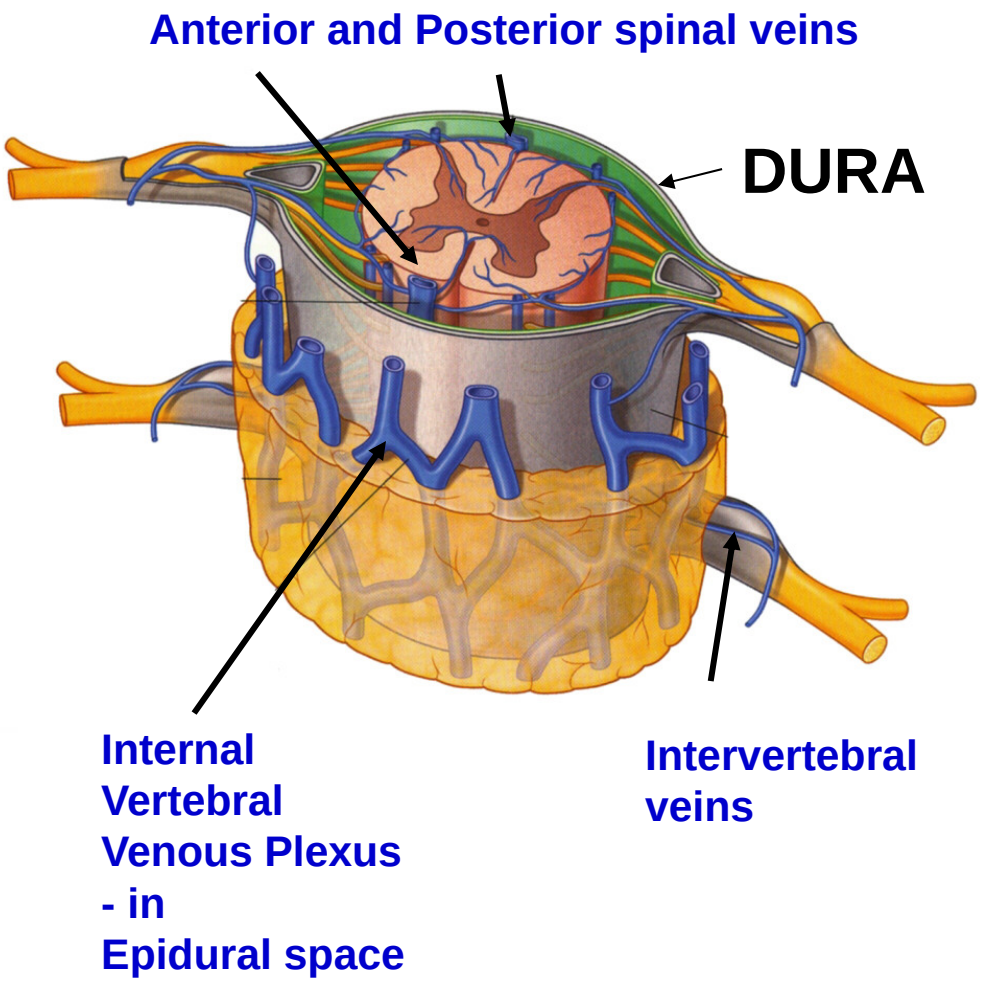

SPREAD OF DISEASE (CANCER) TO VERTEBRAE

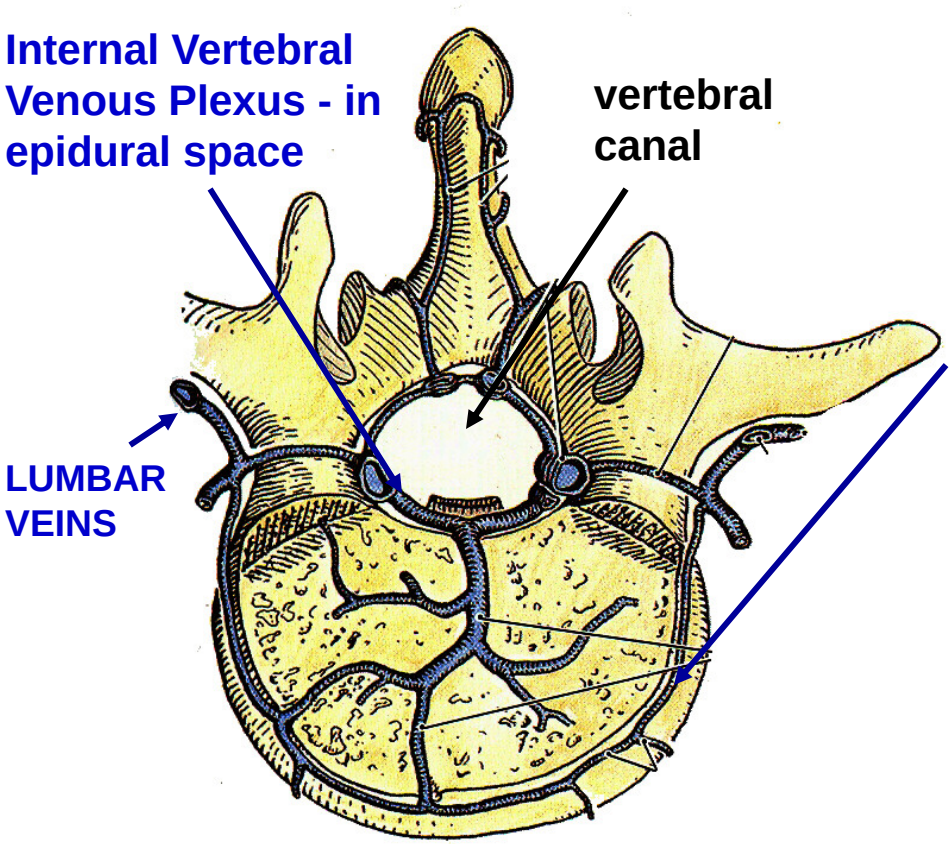

External Vertebral Venous Plexus - outside of vertebrae; connects to other veins of body.

SPREAD OF CANCER

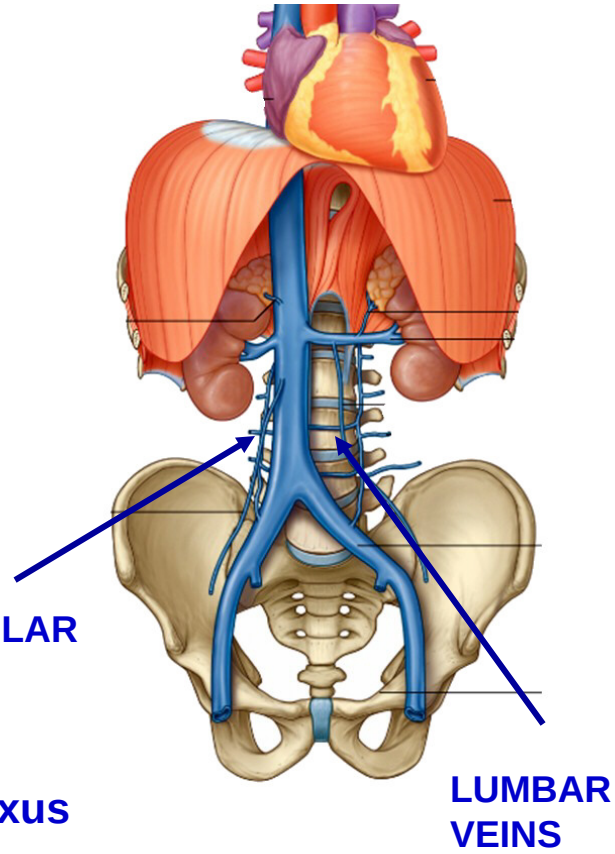

External Vertebral Venous Plexus

Note: Disease processes can spread to spinal cord and vertebra from other regions of body by Vertebral venous plexus and intervertebral veins (ex. carcinoma of prostate (in pelvis) can metastasize to vertebral column).

3) SPINAL REFLEXES AND DIAGNOSIS OF UPPER AND LOWER MOTOR NEURON LESIONS

DEFINITION OF A REFLEX - SENSORY STIMULUS PRODUCES STEREOTYPED MOTOR RESPONSE

SENSORY STIMULUS → **MOTOR RESPONSE**

FOR REFLEX TO OCCUR ALL ELEMENTS MUST BE FUNCTIONAL; PATHWAYS MUST BE INTACT

STRETCH (DEEP TENDON) REFLEX : MONOSYNAPTIC CONNECTION

SENSORY STIMULUS

Two methods:
1) Rapidly Stretch muscle (change muscle length)

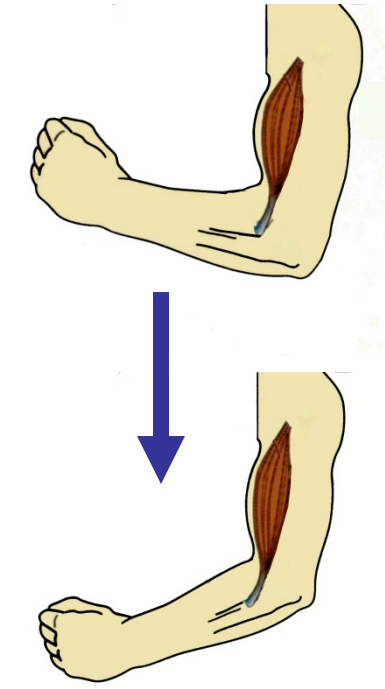

2) TAP ON MUSCLE TENDON

Activate- Muscle spindle (Group Ia and II); monosynaptically excite Alpha (Lower) motor neuron to same muscle.

Muscle spindle - Sensory neurons (Ia, II) SIGNAL MUSCLE LENGTH

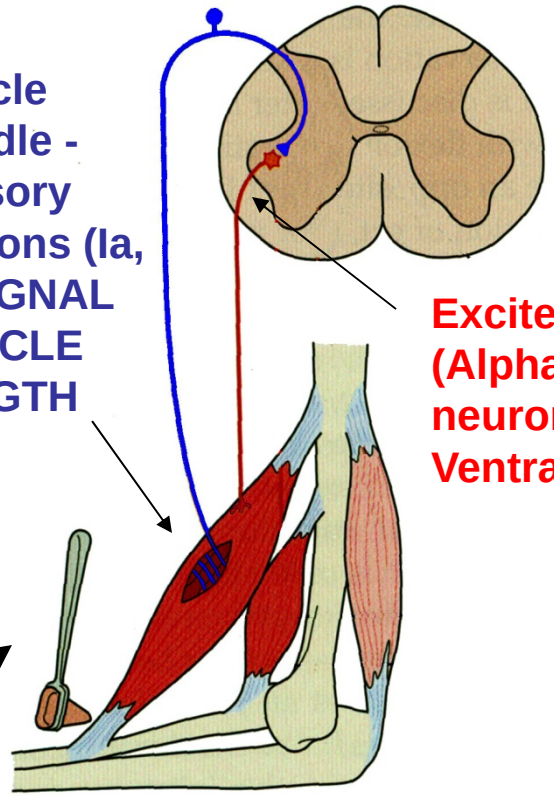

Excites Lower (Alpha) motor neuron in Ventral Horn

MOTOR RESPONSE

Stretched muscle contracts rapidly

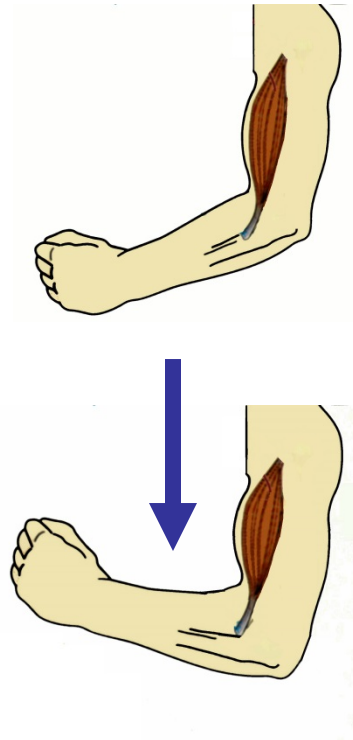

Note: Response large because also excite motor neurons to muscles with similar action and inhibit muscles with opposite action

MUSCLE TONUS =
resting tension in muscle

Tonus reflects firing of alpha motor neurons at rest

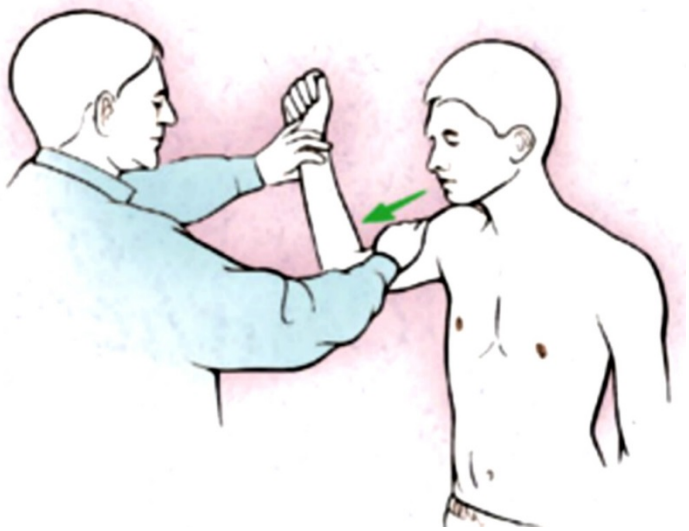

TONUS - Tested by physician slowly extending or flexing joints (stretching patient's muscle)

Activity in muscle spindles at rest is important in determining Tonus because connection is monosynaptic

REFLEXES CHANGED BY GAMMA MOTOR NEURONS - GET PATIENT TO RELAX BEFORE TESTING TONUS OR STRETCH REFLEX

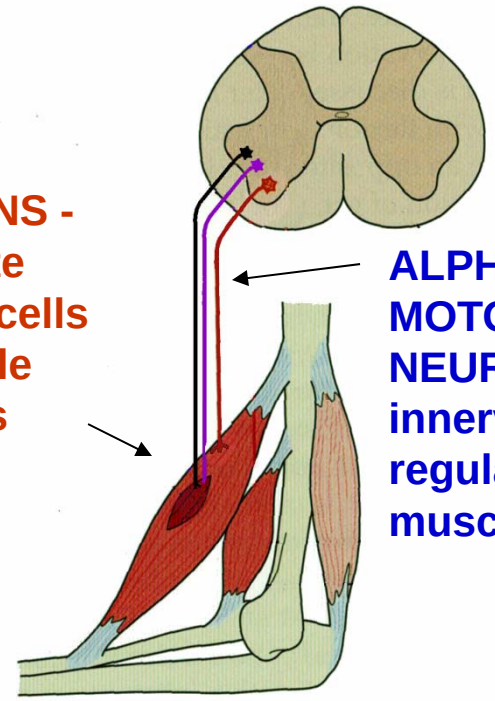

Gamma motor neurons innervate muscle cells in muscle spindles; Gamma motor neurons can heighten stretch reflexes (Gamma dynamic motor neurons specifically effect Ia sensory neurons)

REFLEXES CAN ALSO BE CHANGED BY ACTIVITY IN UPPER MOTOR NEURONS

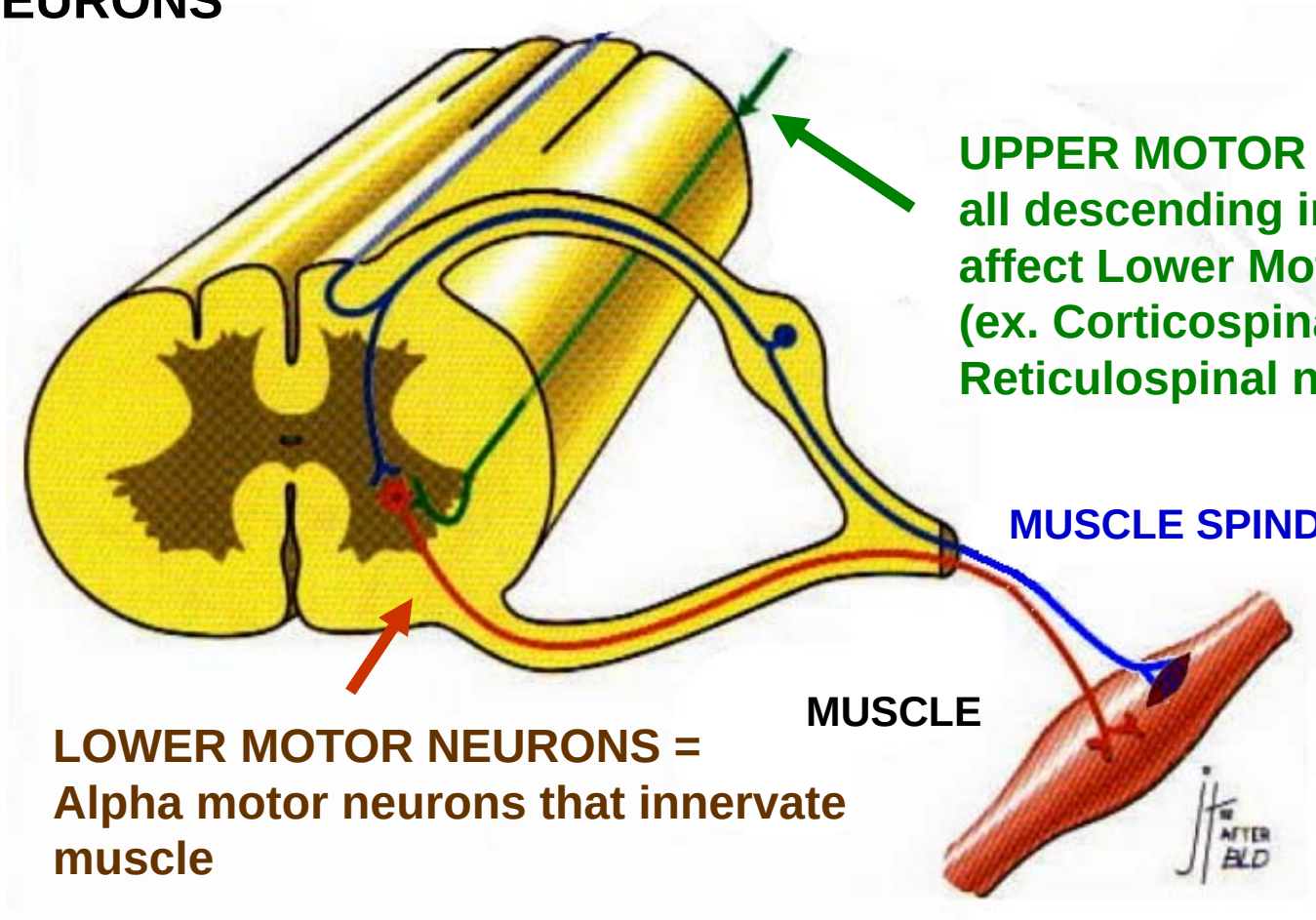

Upper motor neurons can modulate (change) reflexes by:
1) Changing excitability of alpha motor neurons
2) Pre-synaptic Inhibition of Ia terminals; reduces the amount of transmitter release at the synapse upon motor neuron

LOWER MOTOR NEURON DISORDERS

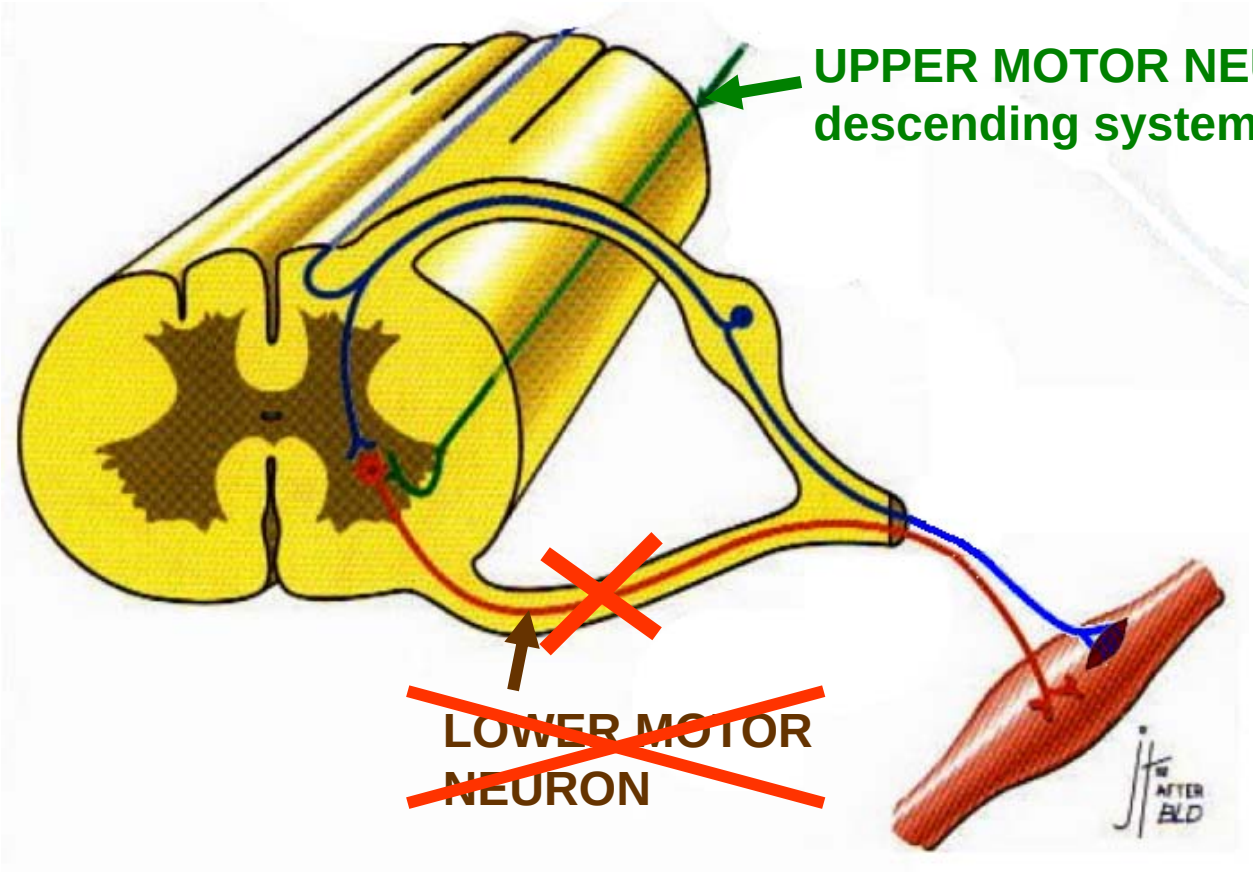

Examples:
1) Compression of spinal nerve
2) Poliomyelitis - viral infections affecting motor neurons

Flaccid Paralysis - muscle is effectively denervated (can affect single muscles)

1) **Decreased stretch (tendon) reflexes - no activation of muscle**
2) **Decreased tonus - no tonic alpha motor neuron activity**
3) **Muscle atrophy - Fasciculations (twitches) precede atrophy - Alpha motor neurons fire spontaneously**
4) **No Babinski sign - no effect descending control**

UPPER MOTOR NEURON DISORDERS

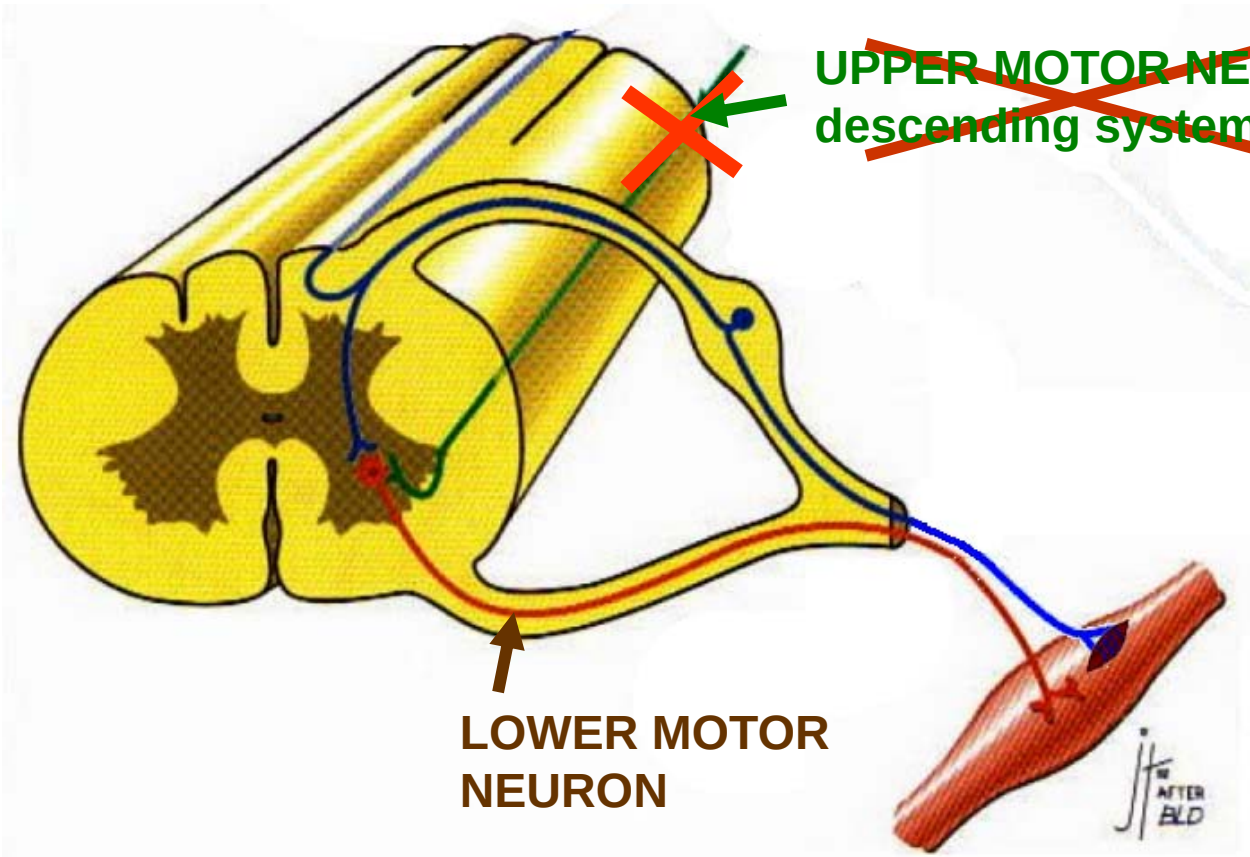

Example: Damage to Corticospinal (Corticobulbar) tracts - can occur at all levels from cortex to spinal cord (brainstem)

Spastic Paralysis - affect groups of muscles

1) Increased stretch (tendon) reflexes - No modulation, remove inhibition of reflex pathways
2) Increased tone - Remove inhibition of reflex pathways
3) No Fasciculations
4) Babinski sign - effect descending control of Flexor reflex
5) Clasped Knife Reflex - high forces activate Golgi tendon organs

HYPERREFLEXIA: INCREASED STRETCH REFLEX ON ONE SIDE [used by permission of Paul D. Larsen, M.D., University of Nebraska Medical Center; http://library.med.utah.edu/neurologicexam]

CLASP-KNIFE PHENOMENON: FORCE ACTIVATES GOLGI TENDON ORGAN

GOLGI TENDON ORGANS SIGNAL MUSCLE FORCE - when force is high, activate Golgi Tendon Organ reflexes (Autogenic inhibition); inhibits alpha motor neurons, DECREASE FORCE

AUTOGENIC INHIBITION

GOLGI TENDON ORGAN (GTO)

GTO (Ib)

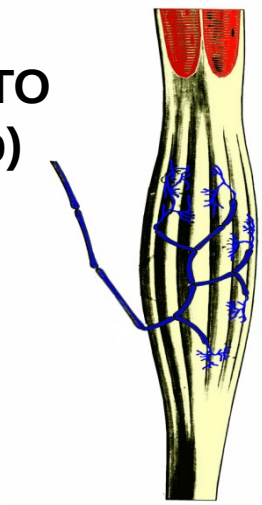

GTO (Ib)

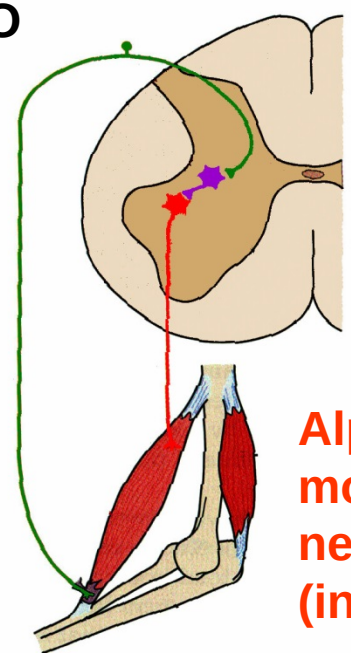

muscle tendon

Alpha motor neuron (inhibited)

SENSORY STIMULUS: FORCE ON MUSCLE TENDON → **MOTOR RESPONSE: FORCE DECREASES**

CLASP-KNIFE PHENOMENON

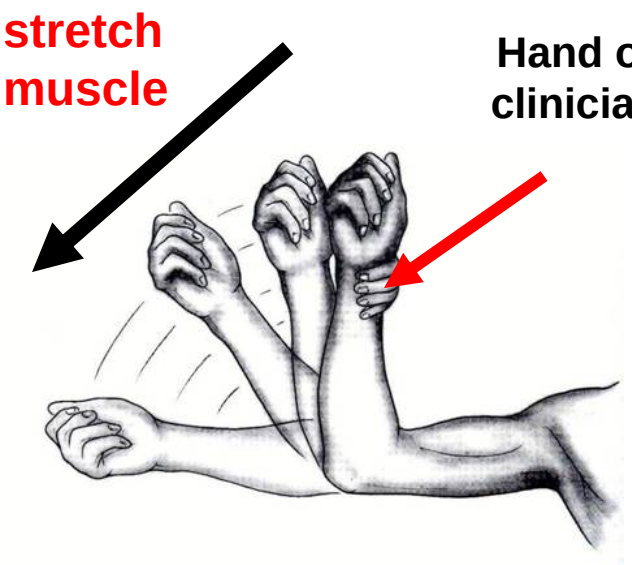

Physician applies, gradual forceful stretch of muscle: resistance to stretch builds until it suddenly gives way.

FLEXOR REFLEX

SENSORY STIMULUS - painful, irritating stimulus to skin → **MOTOR RESPONSE**

- Cutaneous afferent synapse onto Interneurons

- Interneurons make excitatory synapse onto Flexor motor neurons

- Note: Also excite extensor motor neurons in opposite leg (not fall down)

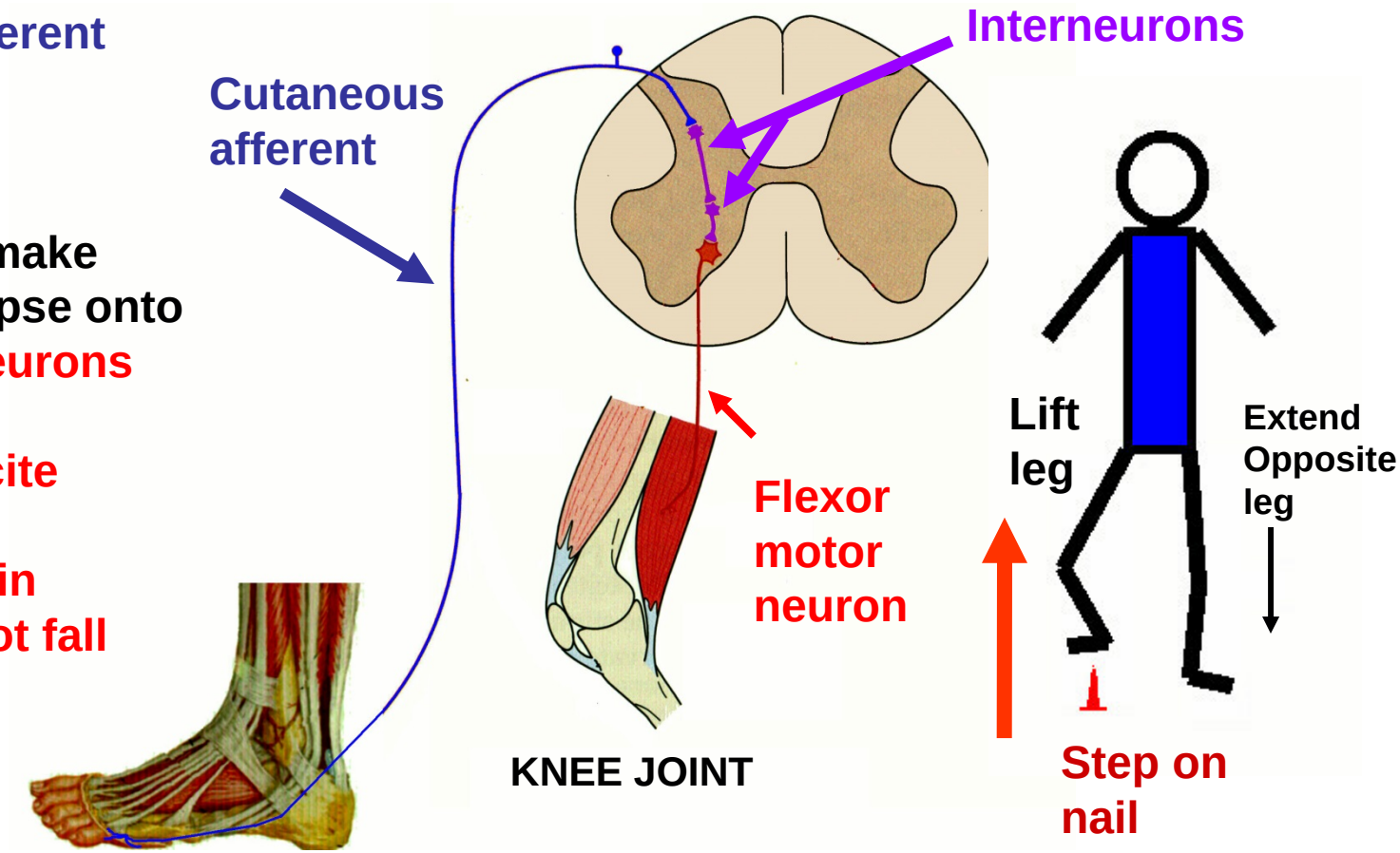

BABINSKI SIGN

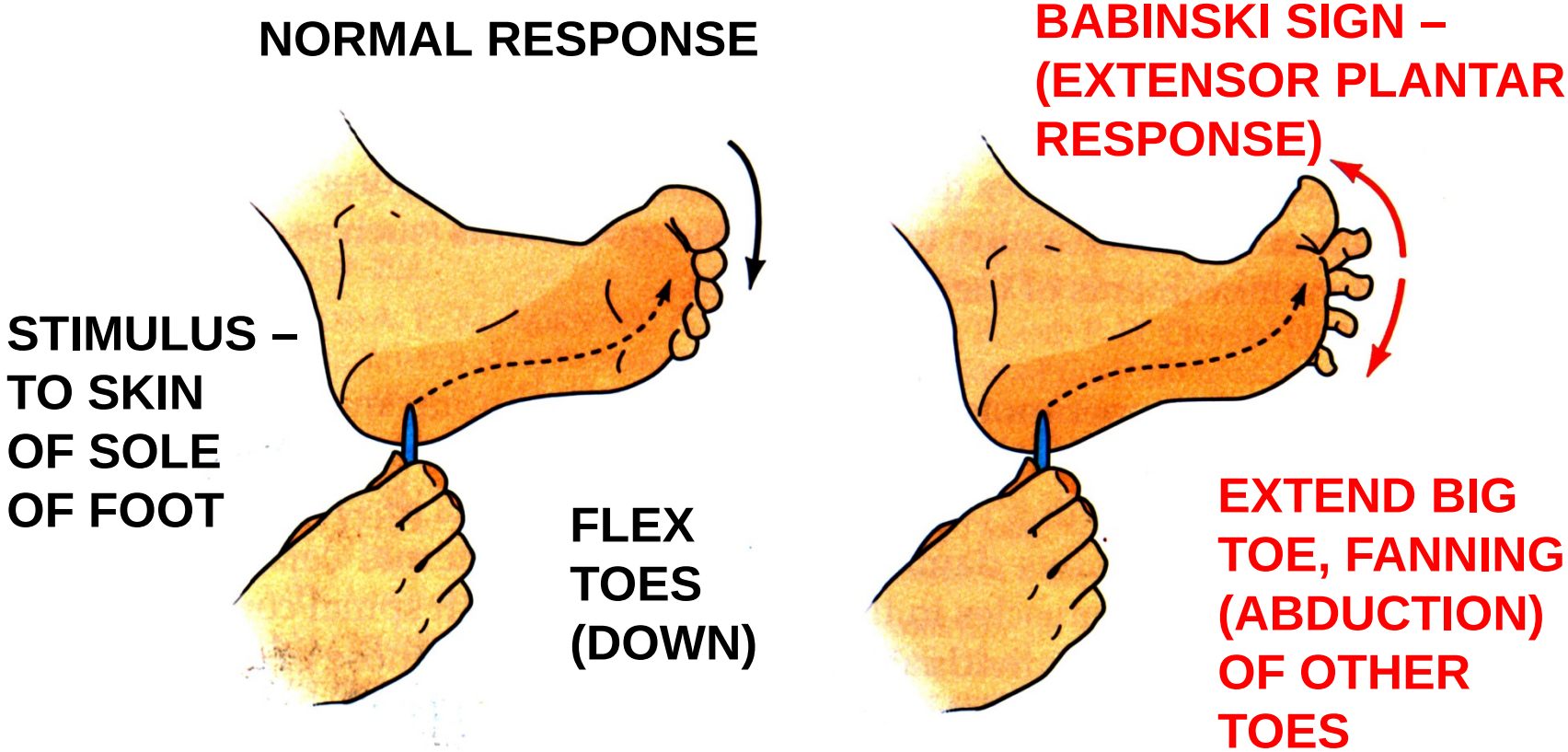

Babinski sign - seen after **Upper Motor neuron lesion**
-direction of movement **changes from flexing toes to extending and fanning (abducting) toes**

REFLEXES IN NEONATES: INFANT STEPPING PRODUCED BY PATTERN GENERATORS IN SPINAL CORD

REFLEXES IN NEONATES

PALMAR GRASP

MORO REFLEX - arm extend

STEPPING 'REFLEX' - actually eliciting a motor pattern

Infant Stepping - 'reflexes' are used to check motor function in neonates; holding infant with weight supported can elicit 'stepping' movements in legs

PATTERN GENERATOR - group of interneurons in CNS that are interconnected; produce activities in motor neurons and can generate rhythmic behaviors.

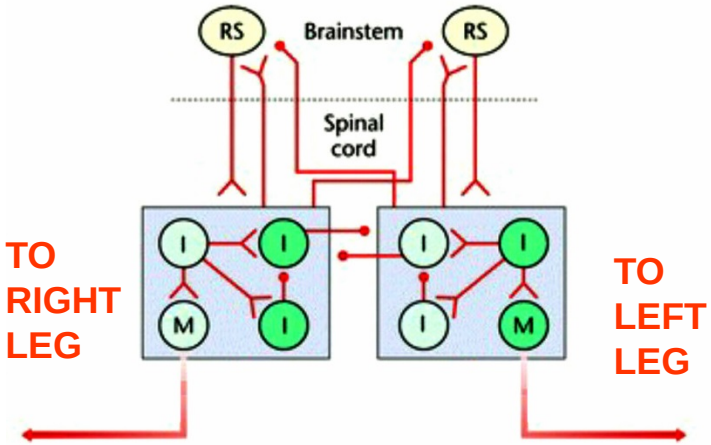

Stepping reflexes probably represents activation of Central Pattern Generator that produces walking movements

GOOD LUCK!