

# FACE

© 2022zillmusom

**I. OVERVIEW: FACE IS UNIQUE** - Skin on face is thin and moveable; Facial muscles take origin from underlying bones (mostly) and insert onto skin.

A. **Facial transplant** - In severe damage to face, facial transplants are required because muscles of facial expression insert onto skin rather than tendons (therefore, cannot use grafts of other body muscles); transplants contain muscles and skin.

B. Neural control of Facial muscles - Facial muscles are under both voluntary and involuntary (emotional) control.

C. Detecting action of Facial muscles - Muscles of face have no (or very few) muscle spindles; muscle contractions are thought to be detected by stretching of skin.

D. Facial paralysis - is a defining symptom in Bell's Palsy

**Bell's palsy - paralysis of facial muscles; lower motor neuron syndrome of facial nerve (CN VII);** thought to be associated with **viral infection** (herpes simplex); **Symptoms unilateral:** sudden onset **paralysis or paresis of all facial muscles on one side;** drooling; inability to close eye; also hyperacusis (sounds seem too loud), loss of taste to anterior tongue; pain in or behind ear.

Note: **Upper motor neuron lesions affecting facial nerve** (ex. **cortical stroke** = vascular insufficiency) - '**Sparing**' of upper face - Often **only muscle of lower face are paralyzed on one side, muscles of upper face not affected** (ex. brow, orbicularis oculi); cortical projections bilateral to upper face; unilateral (contralateral) to lower face.

## II. ARTERIAL SUPPLY

A. Overview of Arterial supply to Head (see Diagrams of Arterial Supply attached); Common Carotid arteries ascend in neck and divided into External and Internal Carotid Arteries (at upper border of thyroid cartilage); Arterial supply to Face derived from branches of - extensive; vessels have many anastomoses.

1. branches to face of External Carotid artery (major blood supply to head).

a. Facial artery - course: extremely winding and tortuous; artery arises from anterior side of External Carotid, first courses medial to mandible, then appears on face anterior to the mandible (site of pulse of Facial artery); artery ascends lateral to lips and ends medial and inferior to orbit. Branches on face:

i) Superior and Inferior Labial arteries - upper and lower lips.  
ii) Angular artery = main part of facial artery adjacent to nose and to angle (corner) of eye.

b. Superficial Temporal artery - one of two terminal branches of External Carotid; course - arises anterior to external auditory meatus (opening to ear), deep to parotid salivary gland; has many branches to scalp; named small branch on face Transverse Facial artery.

2. branches to face of Internal Carotid artery (major blood supply to brain, orbit)

a. Ophthalmic artery - many branches to orbit but also has a number of named branches to face, forehead and nose:

i) Supraorbital artery (above orbit)

ii) Supratrochlear artery (on medial and superior side of orbit)

Note: Orbit (= eye socket) contains the eye and muscles that move the eye; orbit is also a **major route for nerves/blood vessels to get to other places**, (ex. to face, nasal cavity).

**III. VENOUS DRAINAGE OF FACE** - veins of face generally follow arteries; **have no valves**; veins drain both into the skull and down face to the neck; have **extensive anastomoses**.

**Clinical Note: Prolonged infections on face** (pimples or acne) are dangerous because veins of face anastomose, have no valves and drain both to the brain and down to the neck; **infections can spread via anastomoses from face into venous sinuses inside of skull** (ex. through orbit) and involve cranial nerves to muscles of eye (**clinical sign is 'blurred vision' = diplopia**); infections on face lateral to nose are particularly dangerous.

**IV. SENSORY INNERVATION OF FACE** - Sensory supply - via branches of Trigeminal nerve (cranial nerve V); Trigeminal nerve has three divisions: Ophthalmic division (V1), Maxillary division (V2) and Mandibular division (V3).

1. branches of Ophthalmic division - to skin above orbit; Supraorbital, Supratrochlear, Infratrochlear, Lacrimal and External Nasal nerves.

2. branches of Maxillary division - to skin of cheek below orbit; Infraorbital, Zygomaticofacial and Zygomaticotemporal nerves.

3. branches of Mandibular division - to skin of jaw and face below angle of mouth; Mental nerve, Auriculotemporal nerve and Buccal branch of Trigeminal nerve.

**V. MUSCLES OF FACIAL EXPRESSION** - move skin of face, close eyes and close and open mouth; allow you to convey emotions by facial gestures (ex. sneering and contempt); most are attached to bones and insert upon skin; many named for their actions or Latin or Greek words; movements elicited in test for Facial Nerve function

1. Orbicularis oculi - has palpebral (eyelid) and orbital part (edge of orbit); action - close eyelids (note: orbital part 'buries' eyelids, as closing eyes in a sandstorm).
2. Orbicularis oris - surrounds and closes mouth.
3. Muscles of nose - a. Compressor naris - acts to compress nasal cartilages; b. Dilator naris - dilates nostrils; c. Procerus - wrinkles skin of nose.
4. Muscles of upper lip - a. Levator labii superioris - lifts upper lip; b. Zygomaticus major and minor - raise and pull upper lip laterally.
5. Muscles at angle of mouth - a. Levator anguli oris - raises corner of mouth; b. Risorius - smiling muscle; b. Depressor anguli oris - tragedy muscle.
6. Muscle of lower lip and chin - a. Depressor labii inferioris - depresses lower lip; b. Mentalis - wrinkles skin of chin.
7. Buccinator - muscle in cheek; compresses mouth and keeps food between teeth when chewing; buccinator is latin for trumpeter.

Clinical: **Facial nerve damage – can produce difficulty eating** (chewing) because food not kept between teeth after **paralyze Buccinator** (this was board question)

8. Frontalis and Occipitalis – muscles in scalp attached to Epicranial Aponeurosis, skin; Frontalis raises eyebrows.

Clinical: **Test Facial nerve - raise eyebrows with Frontalis.**

9. Platysma - extends in neck from mandible to fascia over Pectoralis Major muscle; moves skin of neck.

**VI. MOTOR INNERVATION TO MUSCLES OF FACIAL EXPRESSION** - via Facial nerve (cranial nerve VII); nerve leaves skull via stylomastoid foramen; enters parotid gland; divides into 5 terminal branches: superior to inferior

1. Temporal
2. Zygomatic
3. Buccal - (not to be confused with Buccal branch of V)
4. Mandibular
5. Cervical

## **VII. DEVELOPMENT OF FACE**

A. Five facial primordia - form in fourth week in development and surround developing stomodeum (= primitive mouth) (Note: the term process is the same thing as prominence)

1. Frontonasal process - formed by mesenchyme below brain; unpaired
2. Maxillary processes - from first branchial arch; paired.
3. Mandibular processes - from first branchial arch, inferior to maxillary processes.

## B. Sequence of Development

1. Thickenings (Nasal placodes) form on each side of Frontonasal process.
2. Medial and Lateral Nasal processes form at margins of Nasal placodes.
3. Upper parts of Medial and Lateral Nasal processes fuse to form upper part of nostril.
4. Inferior part of Medial Nasal processes fuse with Maxillary process on each side to form upper lip.

Note: **Cleft Lip (Cheiloschisis (Gk. Cheilos, lip))** - results from **failure of fusion of Medial Nasal processes with Maxillary process** on that side; can be unilateral or bilateral; occurs in 1 in 1000 births.

5. Nasolacrimal duct - connects anterior eye to nasal cavity; drains tears; forms in development as a solid epithelial cord that extends from medial angle of eye to nasal cavity; cord becomes canalized to form duct.

Note: **Obstructed Nasolacrimal duct** - results from failure of duct to canalize; must be opened for tears to drain to nasal cavity.

## TABLE OF MUSCLES OF FACIAL EXPRESSION

Muscle	Action	Clinical Note
<b>Eye</b>		
<b>Orbicularis oculi</b>	Orbital part (surrounds eyelids) – 'buries' eyelids (as in sandstorm) Palpebral part (within eyelids) – closes eyelid	<b>Closing eyelid is essential to prevent damage to cornea</b> - cover, sew eyelids shut (neonates) in Facial paralysis
<b>Nose</b>		
Compressor naris	compress nasal cartilages	
Dilator naris	dilates nostrils	
Procerus	wrinkles skin of nose.	
<b>Mouth</b>		
Orbicularis Oris	closes mouth (surrounds lips)	
Levator labii superioris	lifts upper lip	Loss of nasolabial (skin) fold - in Bell's palsy
Zygomaticus major and minor -	raise and pull upper lip laterally	
Levator anguli oris -	raises corner of mouth	Drooping of corner of mouth in Bell's palsy
Risorius (Latin for smiling)	smiling muscle	
Depressor anguli oris	tragedy muscle	
Depressor labii inferioris	depresses lower lip	
<b>Other</b>		
Mentalis	wrinkles skin of chin	
<b>Buccinator</b> (latin for trumpeter)	compresses mouth and keeps food between teeth when chewing	<b>patients with Bell's palsy have difficulty 'eating food', drooling</b>
<b>Frontalis and Occipitalis</b>	move scalp (attach to Epicranial Aponeurosis); frontalis raises eyebrows	drooping of eye brow in Bell's palsy (Clinical test - raise eyebrows)
Platysma	stretches skin of neck	

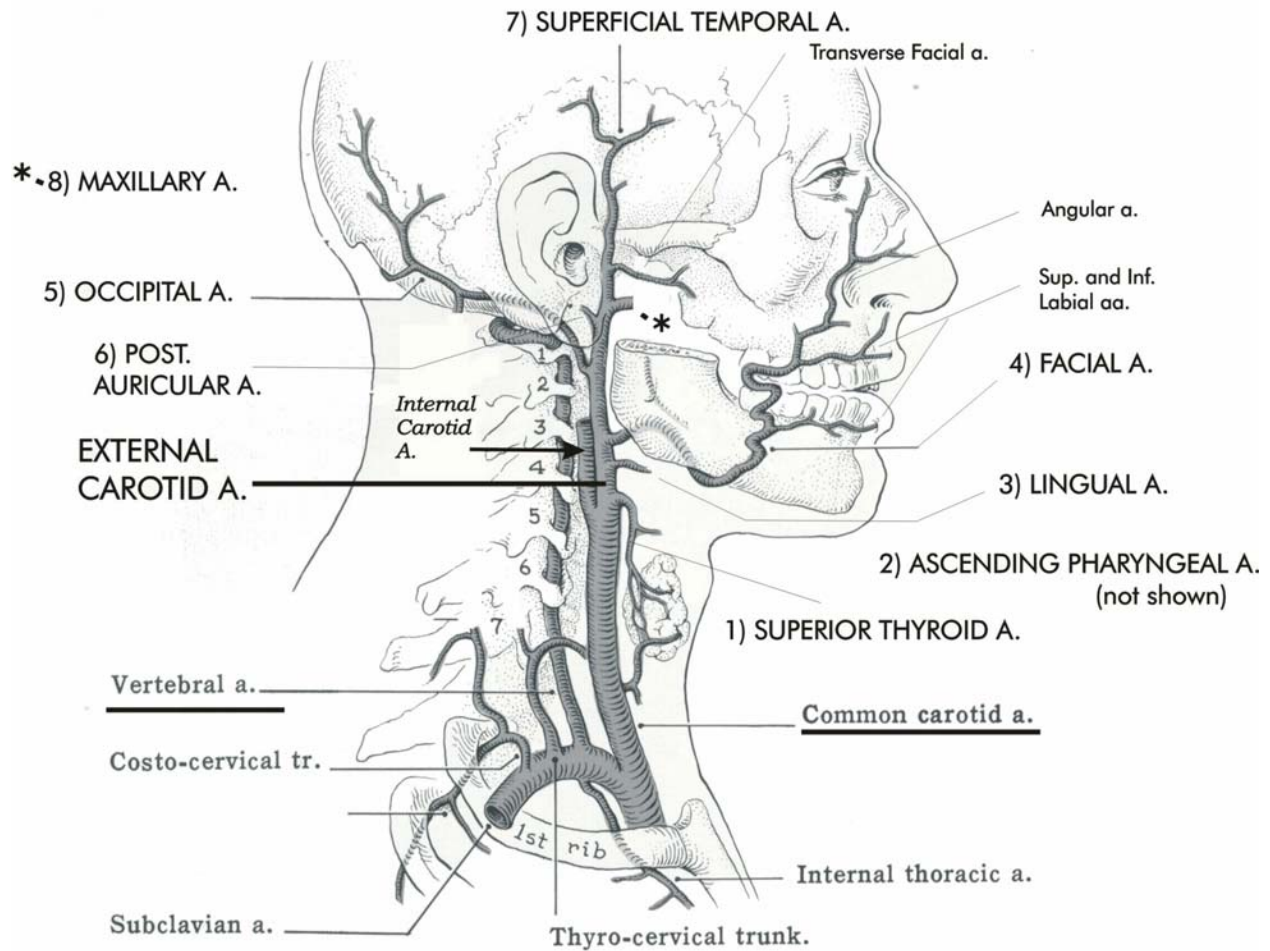
SEE ZILLANATOMY.COM VIDEO: FACIAL MUSCLES FOR ILLUSTRATION OF LOCATION



REFERENCE DIAGRAM

# OVERVIEW OF BLOOD SUPPLY TO HEAD

(EXCLUDING BRANCHES OF INTERNAL CAROTID A.)



**EXTERNAL CAROTID ARTERY**

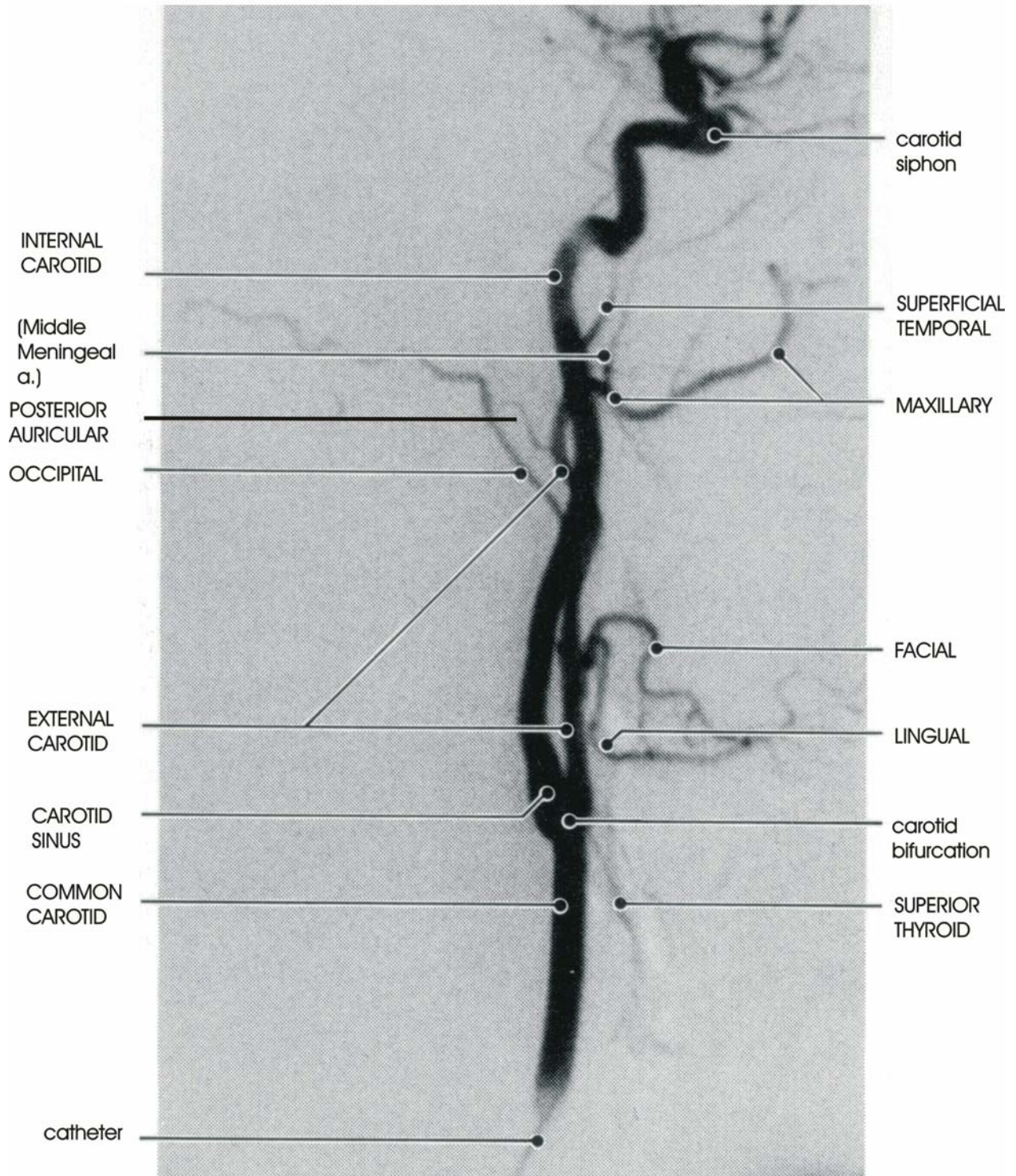
- 1) Superior Thyroid a.
- 2) Ascending Pharyngeal a.
- 3) Lingual a.
- 4) Facial a.
- 5) Occipital a.
- 6) Post. Auricular a.
- 7) Superficial Temporal a.
- 8) Maxillary a.

**SUBCLAVIAN ARTERY**

- Vertebral a.
- Internal Thoracic a.
- Thyrocervical trunk
- Costocervical trunk

**ORIENTATION: NOSE---->**

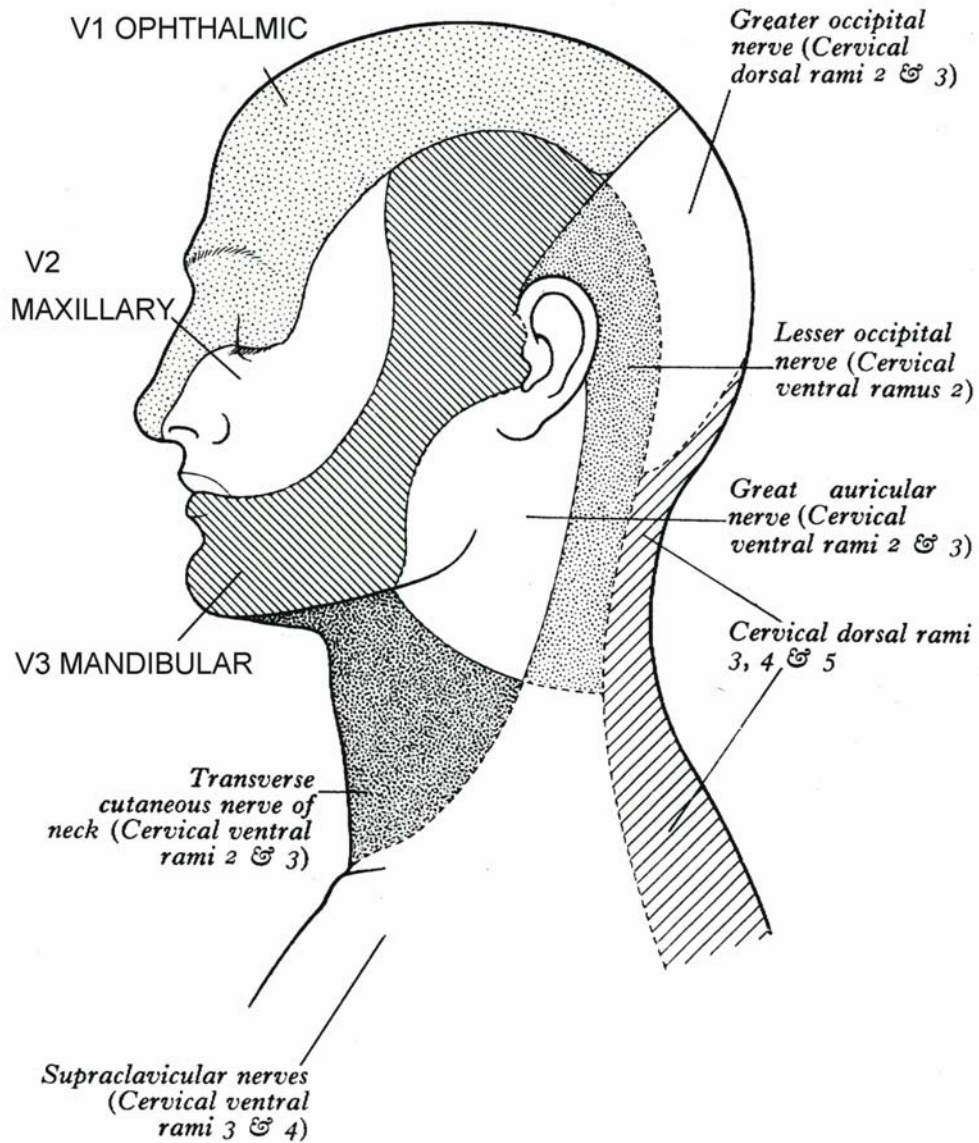
# CAROTID ARTERIOGRAM



## REFERENCE DIAGRAM

# CUTANEOUS INNERVATION OF HEAD AND NECK

TRIGEMINAL NERVE (V) - three divisions - V1 Ophthalmic,  
V2 Maxillary, V3 Mandibular





**REFERENCE HANDOUT (DO NOT MEMORIZE): TRIGEMINAL NERVE BRANCHES**

zill@musom.2022

**V1 Ophthalmic - Somatic Sensory only (GSA) - through Superior Orbital Fissure to Orbit**

<b>Nerve</b>	<b>Branches</b>	<b>Innervates</b>
1. Frontal Nerve	a. Supraorbital Nerve	Scalp forehead, upper eyelid
	b. Supratrochlear Nerve	Scalp forehead, upper eyelid
2. Lacrimal Nerve		Upper eyelid
3. Nasociliary Nerve	a. Long Ciliary Nerve	Cornea of eye
	b. Ant. and Post. Ethmoidal Nerves	Nasal cavity, ethmoid sinus, tip of nose
	c. Infratrochlear Nerve	Upper eyelid, nose

**V2 Maxillary - Somatic Sensory (GSA) only - through Foramen Rotundum to Pterygopalatine Fossa**

<b>Nerve</b>	<b>Branches</b>	<b>Innervates</b>
1. Meningeal branches		Dura of mid. Cranial fossa
2. Ganglionic branches	a. Greater Palatine Nerve	Hard Palate
	b. Lesser Palatine Nerve	Soft Palate
	c. Nasopalatine Nerve	Nasal Cavity, Hard Palate
	d. Nasal branches	Nasal Cavity
3. Post. Sup. Alveolar Nerve		Maxillary teeth
4. Infraorbital nerve		Lower eyelid, nose, upper lip
	a. Ant. Sup. Alveolar Nerve	Maxillary teeth
	b. Mid. Sup. Alveolar Nerve	Maxillary teeth
5. Zygomatic nerve	a. Zygomaticofacial Nerve	Skin of cheek
	b. Zygomaticotemporal Nerve	Skin of temporal region

**V3 Mandibular - Somatic Sensory (GSA) and Branchiomotor (SVE) - Foramen Ovale to Infratemporal Fossa**

<b>Nerve</b>	<b>Branches</b>	<b>Innervates</b>
1. Nervous spinosus		Sensory to Dura of mid Cranial fossa
2. Motor branches		Motor to Med. Pterygoid, Tens. Tympani, Tensor Palati
3. Anterior division	a. Nerve to Lateral Pterygoid	Motor to Lateral Pterygoid
	b. Masseteric Nerve	Motor to Masseter
	c. Deep Temporal Nerve	Motor to Temporalis
	d. Buccal Nerve	Sensory to Cheek
4. Posterior Division	a. Auriculotemporal Nerve	Sensory to external auditory meatus, tympanic membrane, TMJ, lateral scalp
	b. Lingual Nerve	Sensory (touch) ant. 2/3 tongue
	c. Inferior Alveolar Nerve i. Nerve to Mylohyoid ii. Mental Nerve	Sensory to Mandibular teeth Motor to Mylohyoid, ant. Digastric Sensory to Chin, Lower lip