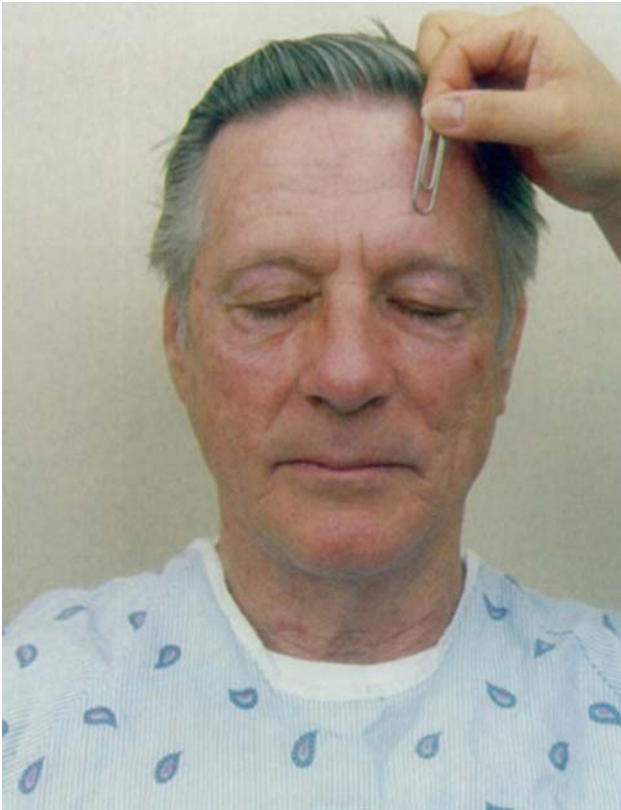
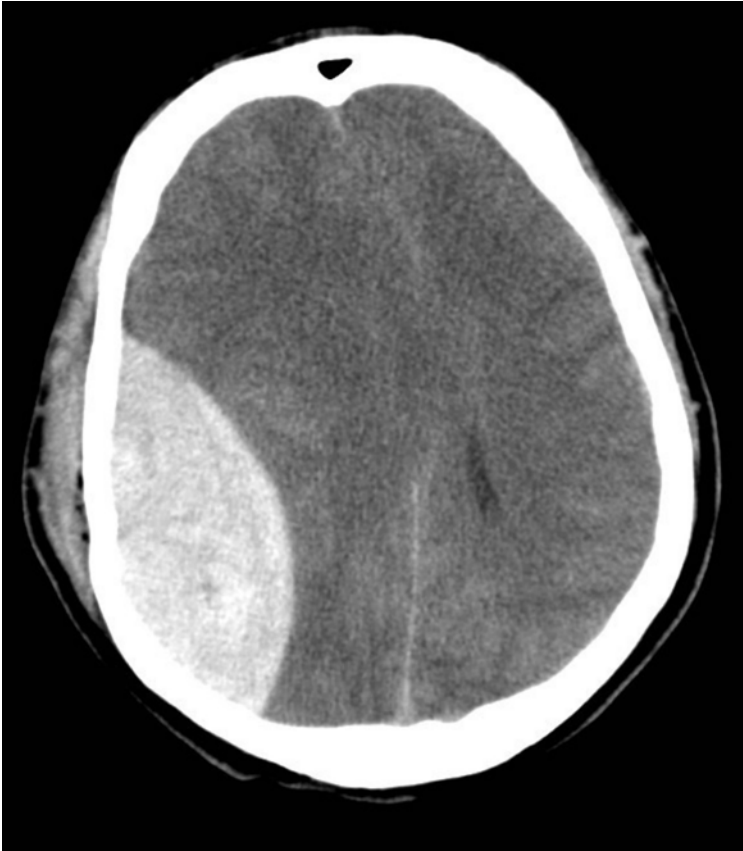


**HEAD AND NECK ANATOMY PRACTICE QUESTIONS – STEP 1 FORMAT 2021
(ANSWER KEY AT END)**



1. _____ A patient complains that he has lost sensation on his face and that the skin of his face feels numb. The physician tests tactile acuity by touching the forehead (see photo above) and finds severe loss of sensation. Which of the following is the location of the sensory neuron cell bodies that innervate this area?

- A. Mesencephalic nucleus of V
- B. Semilunar (Trigeminal) ganglion
- C. Geniculate ganglion
- D. Ciliary ganglion
- E. Pterygopalatine ganglion



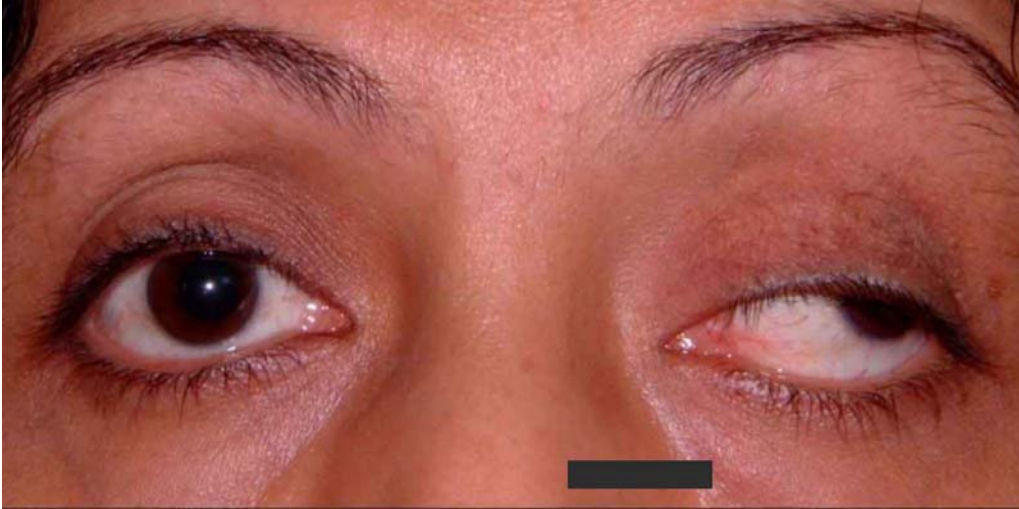A person is in an automobile accident and gets struck on the side of the head. The patient refuses to be taken to the hospital and instead demands to simply go home and lie down for a while. Within hours, the person is rushed to the hospital after losing consciousness. The image above is a CT scan section at the level of the cranial cavity.

2. _____ The physician suspects that this is a hematoma that has resulted from tear of a vascular structure. Which of the following describes the type of hematoma and the vascular structure that was damaged?

- A. Subdural hematoma, Ophthalmic artery
- B. Subdural hematoma, Middle Meningeal artery
- C. Epidural hematoma, Ophthalmic artery
- D. Epidural hematoma, Middle Meningeal artery
- E. Epidural hematoma, Deep Temporal artery

3. _____ This artery is a branch of the

- A. Internal Carotid Artery
- B. Superficial Temporal Artery
- C. Occipital Artery
- D. Maxillary Artery
- E. Facial Artery



A patient sees a physician because the eyelid of her left eye is drooping and she is having double vision. Examination of the patient (photo above) shows ptosis of the left eyelid and deviation of the left eye when the patient is told to look straight ahead. Further examination demonstrates that pupil is dilated in the left eye.

4. _____ Which of the following nerves is likely to have been damaged?
- A. Trochlear
 - B. Abducens
 - C. Oculomotor
 - D. Facial
 - E. Ophthalmic division of the Trigeminal (V1).
5. _____ The ptosis is likely to be due to partial paralysis of which of the following muscles?
- A. Superior oblique
 - B. Levator Palpebrae Superioris
 - C. Frontalis
 - D. Superior Rectus
 - E. Orbicularis Oculi
6. _____ The pupil is dilated because the action of the dilator pupillae muscle is unopposed. Which of the following is the innervation of the dilator pupillae muscle?
- A. Sympathetic fibers
 - B. Facial nerve
 - C. Infraorbital nerve (V2)
 - D. Trochlear nerve
 - E. Optic nerve

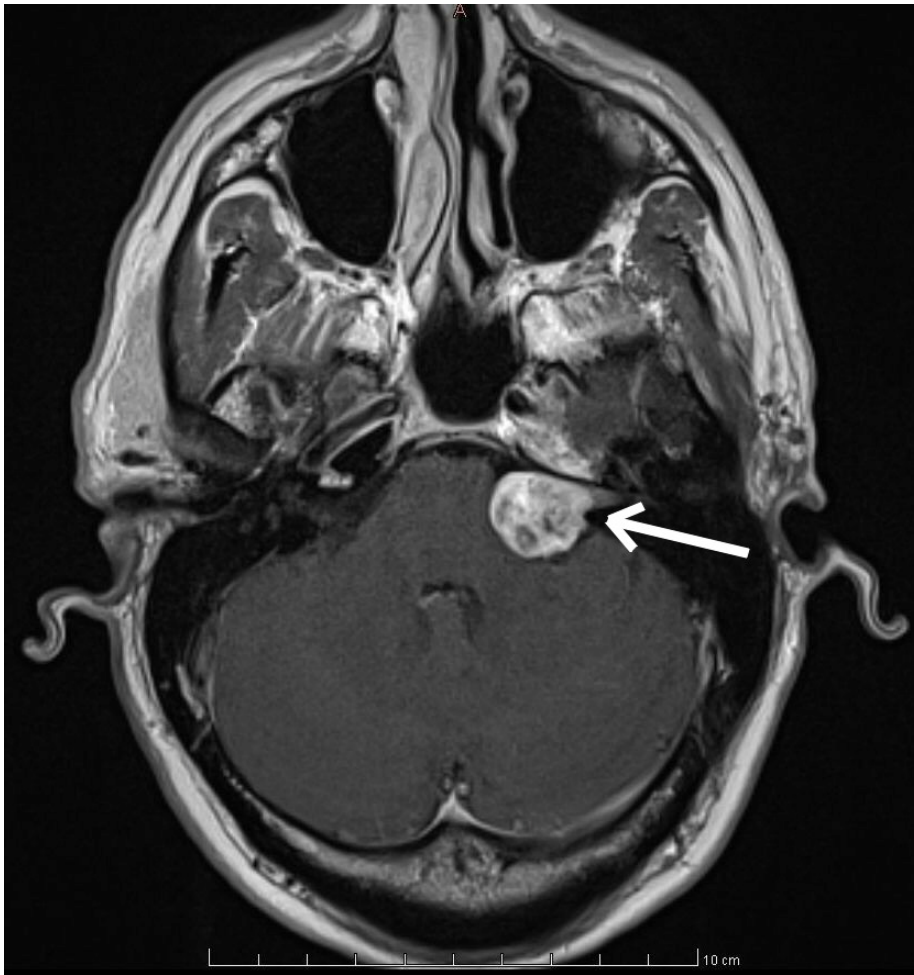
A teenager patient develops a pimple on the face lateral to the nose and scratches the sore. In time, the sore becomes infected but remains untreated. The patient then develops neurological symptoms and has the major complaint of 'blurred vision' which is diagnosed as Diplopia.

7. _____ The physician suspects that the infection has spread to a structure inside the cranial cavity. Which of the following is likely to be the structure and the route by which the infection has spread?

- A. Superior Sagittal sinus, 'bridging' veins
- B. Inferior Petrosal sinus, middle meningeal vein
- C. Cavernous sinus, ophthalmic veins
- D. Transverse sinus, mastoid veins
- E. Cavernous sinus, retromandibular veins

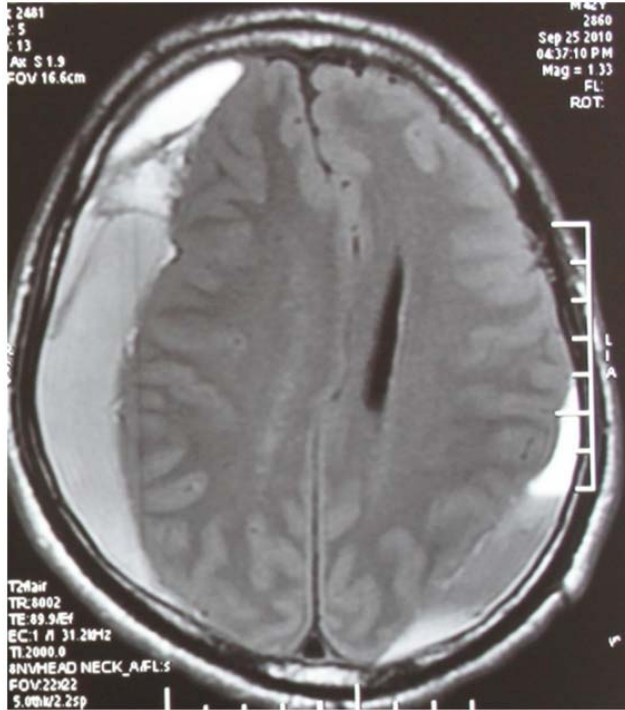8. _____ The blurred vision is likely result from compromised function of which of the following?

- A. optic nerve (II)
- B. optic chiasm
- C. long ciliary nerves
- D. short ciliary nerves
- E. nerves to eye muscles (III, IV, VI)



9. _____ A 35-year-old male is referred to a neurologist because of hearing loss. The patient also states that he has begun experiencing episodes of facial weakness and drooping at the corner of the mouth. An MRI (imaged above) shows a mass in the posterior cranial fossa at the cerebellopontine angle. Further testing demonstrated that the patient had a number of other neurological and physical deficits. Which of the following would NOT be likely to be shown by this patient?

- A. decreased salivation
- B. facial paralysis
- C. loss of taste to the anterior 2/3 of the tongue
- D. decreased secretion of the lacrimal gland
- E. dilated pupil of the eye



10. ____ A 63-year-old aging rock musician fell off the stage during a concert tour and his head struck a large speaker in front of the stage. While he felt fine but bruised on the day of the fall, within the next week he developed a bad headache and was more verbally incoherent than usual. X rays taken at the hospital showed no fractures of the skull but there was evidence of papilledema. The image above is an MRI image from a series that was subsequently ordered. Damage to which of the following vessels is most likely to account for the symptoms?

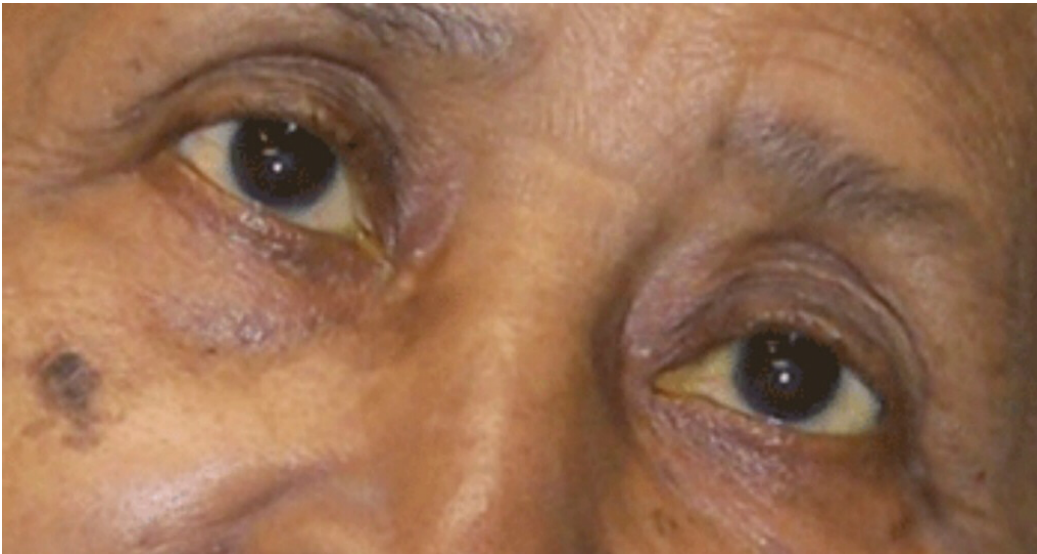- A. Internal Carotid Artery
- B. Internal Jugular Vein
- C. Vertebral Artery
- D. Superficial Temporal Artery
- E. 'Bridging' Vein or Venous Sinus

11. ____ A patient chronically suffers from excess production of mucous in the nasal cavity. He also complains that he often has tears in his eye. These symptoms could result from damage to the parasympathetic innervation of the mucous glands of the nose and the lacrimal gland. Damage to which of the following cranial nerves and associated ganglion could produce these symptoms?

- A. CN VII, Pterygopalatine ganglion
- B. CN IX, Otic ganglion
- C. CN III, Ciliary ganglion
- D. CN V, Semilunar ganglion
- E. CN VII, Submandibular ganglion

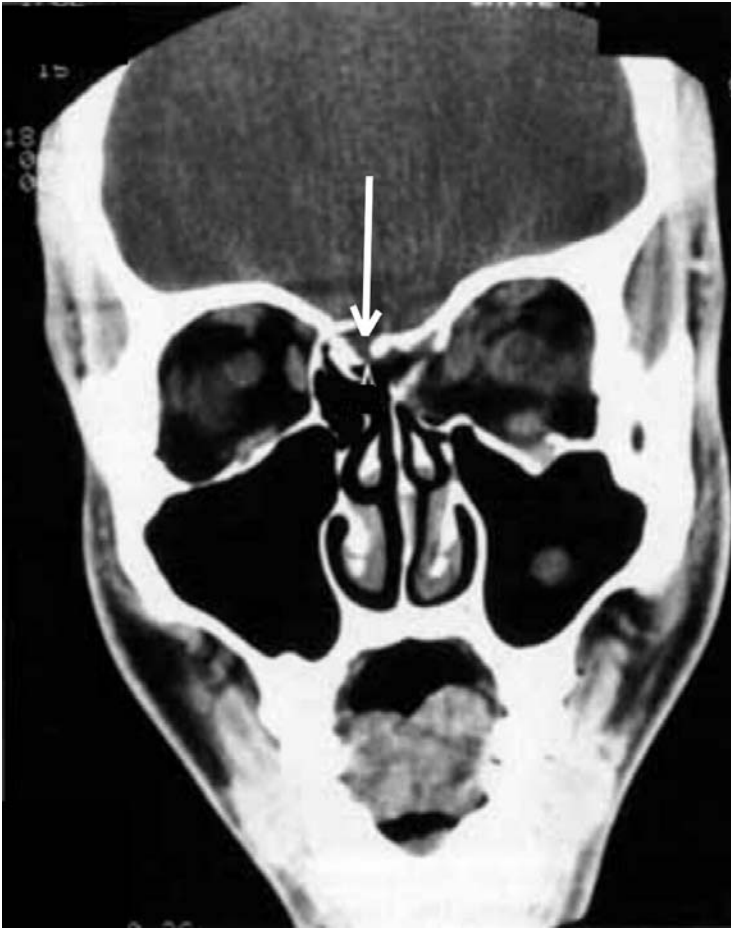12. ____ Access to the circulatory system may be obtained in neonates by a needle placed into the skull at the Anterior fontanelle. Which of the following is the vascular structure that would be accessed in this procedure?

- A. Superior Sagittal sinus
- B. Inferior Sagittal sinus
- C. Sigmoid sinus
- D. Middle Meningeal vein.
- E. Cavernous sinus



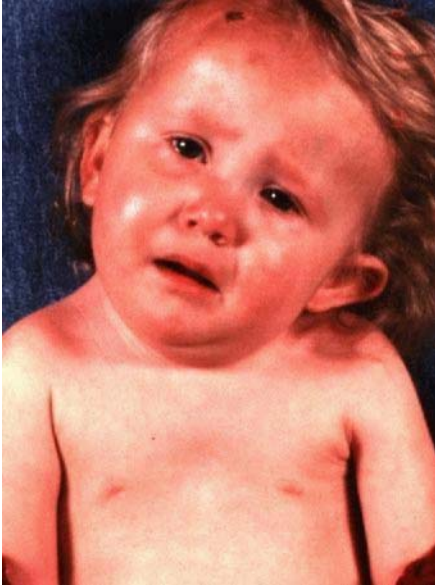13. ____ A 64 year-old female is in the back seat of car that suddenly decelerates in an accident. She shows no acute injury but in the following days she begins having double vision. Examination of the patient shows that she is holding her head tilted (see photo above). Cranial nerve examination finds that she has difficulty moving her right eye downward, particularly from an adducted position. A head MRI is ordered to specifically image which the following cranial nerves?

- A. right cranial nerve III
- B. left cranial nerve IV
- C. right cranial nerve IV
- D. left cranial nerve III
- E. right cranial nerve VI



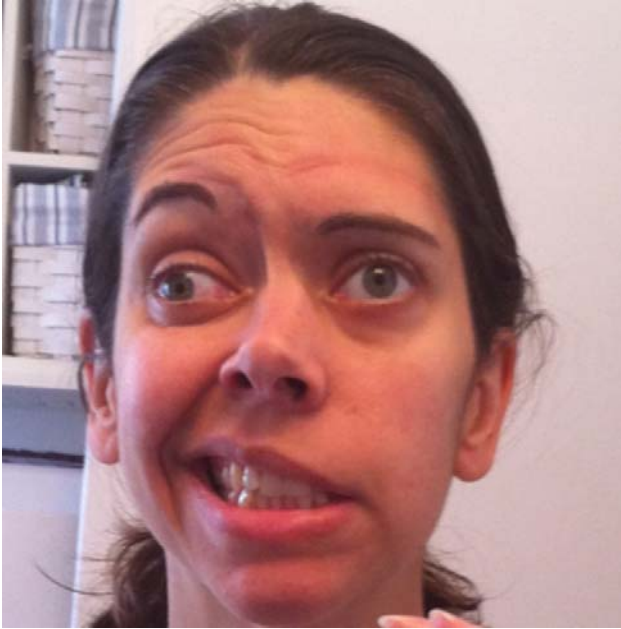14. ____ A 19 year old suffers a violent blow to the nose during a fist fight. Over the following week, the person notices that a clear fluid persists in dripping from the nose and goes to the local hospital emergency room. The physician orders a CT scan (image above) and finds a defect (arrow) in the floor of anterior cranial fossa. This defect is likely a fracture of which of the following bones?

- A. Maxillary bone
- B. Vomer
- C. Horizontal process of the frontal bone
- D. Greater wing of the sphenoid bone
- E. Cribriform plate of the ethmoid bone



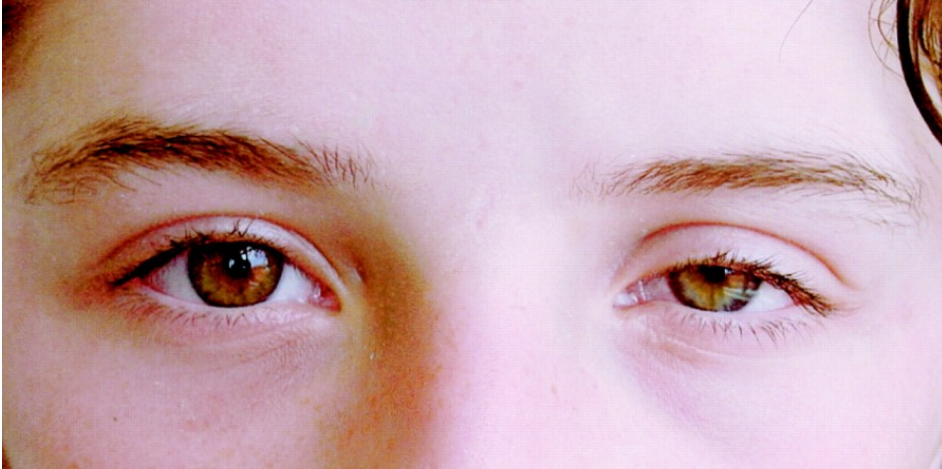15. _____ The parents of a small child notice that she appears to have a 'twisted' neck. When the child is brought to the pediatrician's office, the head is held so that the face is directed partially toward one shoulder (see photo above). The physician suspects that the child has a torticollis resulting from the contracture of a neck muscle. Contracture of which of the following muscles could cause this condition?

- A. Left Sternocleidomastoid muscle
- B. Right Sternocleidomastoid muscle
- C. Left Omohyoid muscle
- D. Left Sternothyroid muscle
- E. Left Digastric muscle



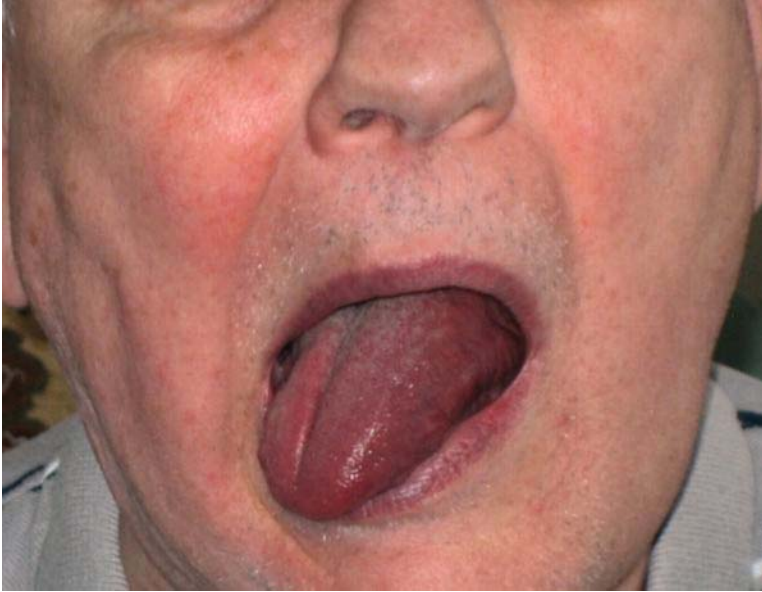16. ____ This is a photo a patient attempting to smile and raise their eyebrows. Which of the following would be an additional symptom shown by this patient?

- A. Pain (ear ache) in right ear
- B. Sounds seem too loud in left ear
- C. Decreased taste sensation on right side
- D. Pupillary constriction in left eye
- E. Loss of sensation to skin of forehead on left side



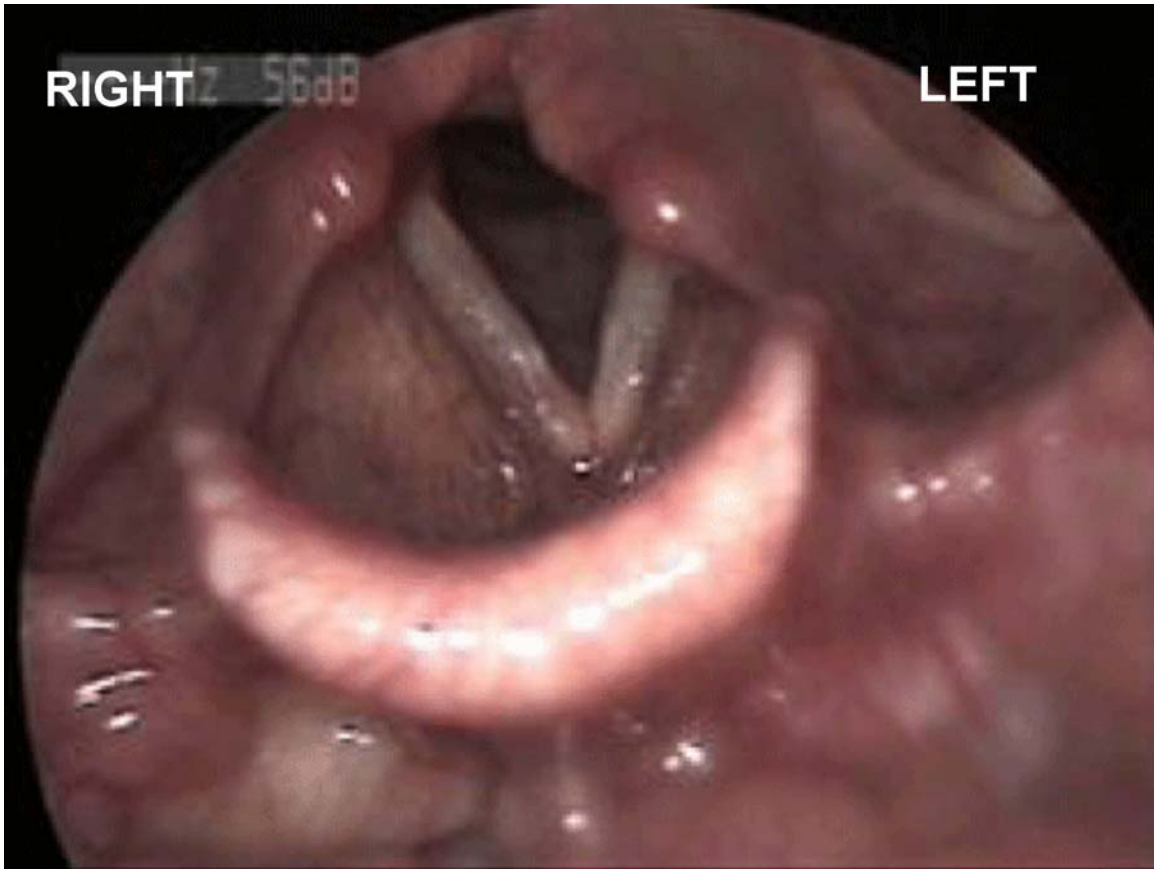
17. ____ An 18-year-old female sees a physician because one of her eyes 'won't stay open' (photo above). Tests show that the patient's visual acuity and eye movements are normal. However, further tests show that pupil of the left eye is constricted (relative to right eye). These symptoms could be caused by a tumor at which of the following locations?

- A. at the Superior Orbital Fissure compressing the Oculomotor nerve.
- B. at the Internal Auditory meatus compressing the Facial nerve
- C. in the neck compressing the Sympathetic chain.
- D. at the Supraorbital foramen compressing the Supraorbital nerve.
- E. at the Inferior Orbital fissure compressing Infraorbital nerve.



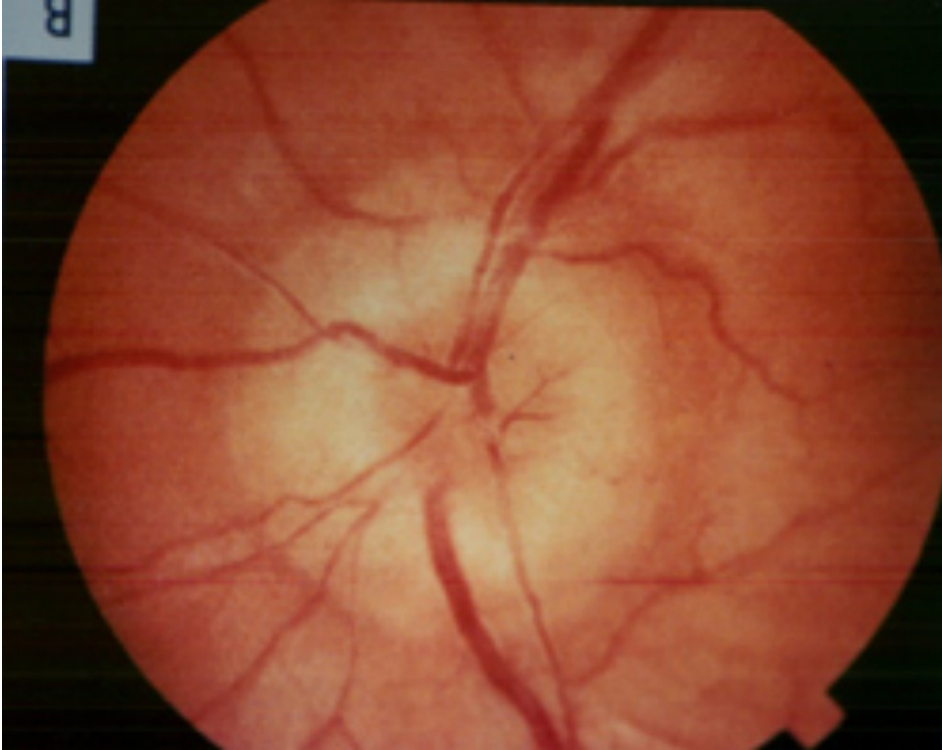18. ____ A patient complains that he is having difficulty speaking and that he is biting his tongue when chewing his food. The physician asks the patient to protrude his tongue (photo above). Other tests show that there is no loss of taste or touch sensation in the tongue. Damage to which of the following nerves could produce these symptoms?

- A. Right Lingual nerve
- B. Right Hypoglossal nerve
- C. Left Lingual nerve
- D. Left Hypoglossal nerve
- E. Left Glossopharyngeal nerve



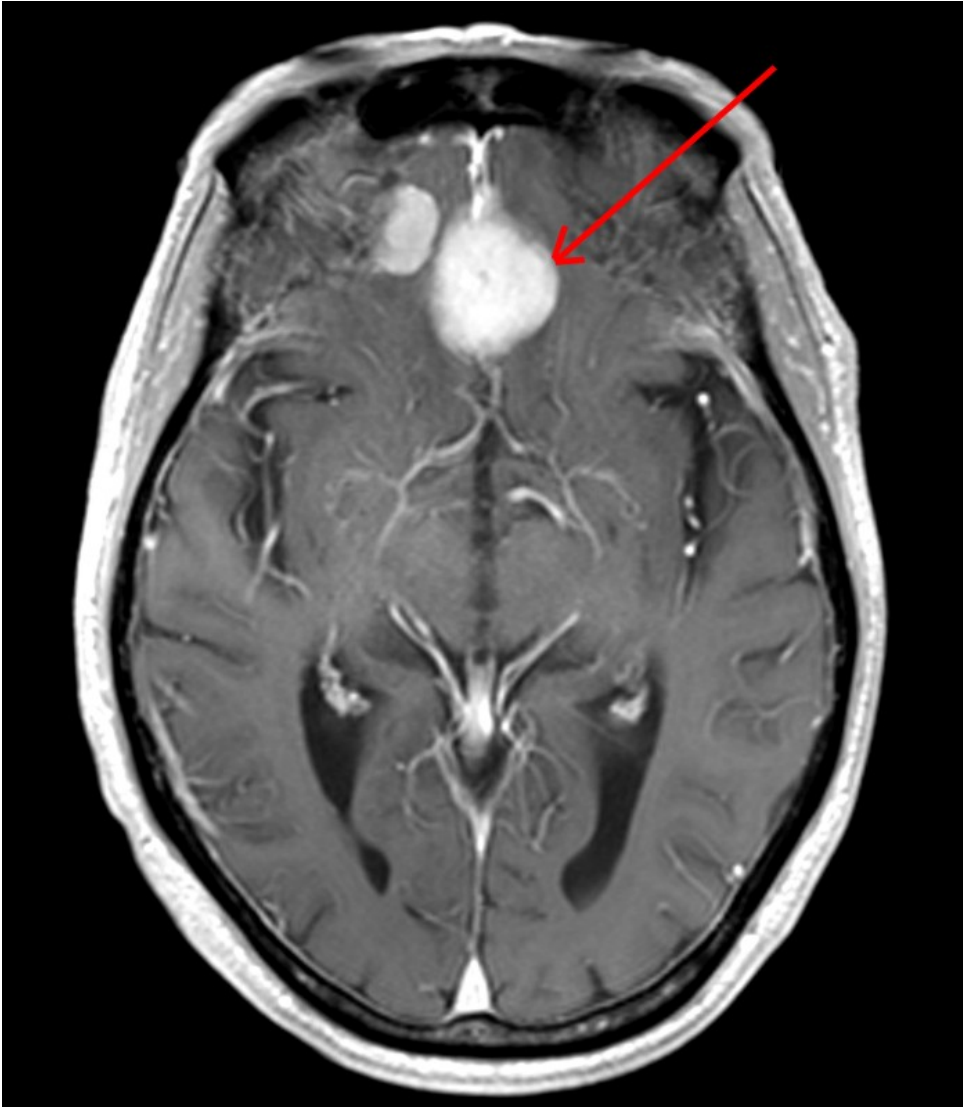
19. ____ A patient undergoes surgery for removal of thyroid nodules. The nodules are found to be noncancerous but post-operatively the patient has a 'hoarse' voice. Laryngoscopic examination (photo above) shows asymmetry in position of the vocal folds when the patient is told to breathe deeply. The physician suspects that this is due to damage of which of the following structures?

- A. Right Superior Laryngeal nerve
- B. Right Recurrent Laryngeal nerve
- C. Left Superior Laryngeal nerve
- D. Left Recurrent Laryngeal nerve
- E. Right Sympathetic chain



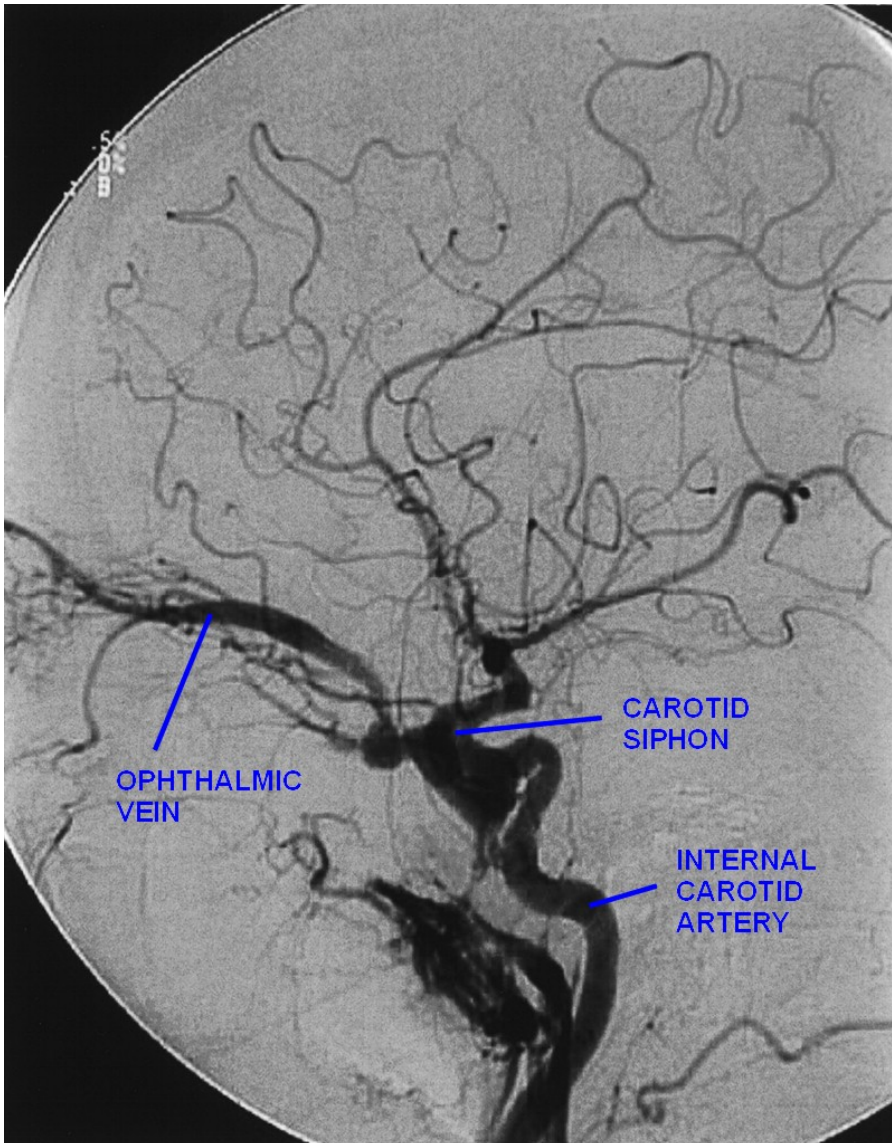
20. ____ An 85 year old woman complains of persistent headaches. Examination of the optic nerve with an ophthalmoscope (image above) shows bulging consistent with the occurrence of papilledema. The appearance is similar in both eyes. The physician suspects that this may be caused by increased intracranial pressure. Calcification of which of the following structures could cause this condition?

- A. choroid plexus
- B. pterygoid venous plexus
- C. denticulate ligaments
- D. emissary veins
- E. arachnoid villi



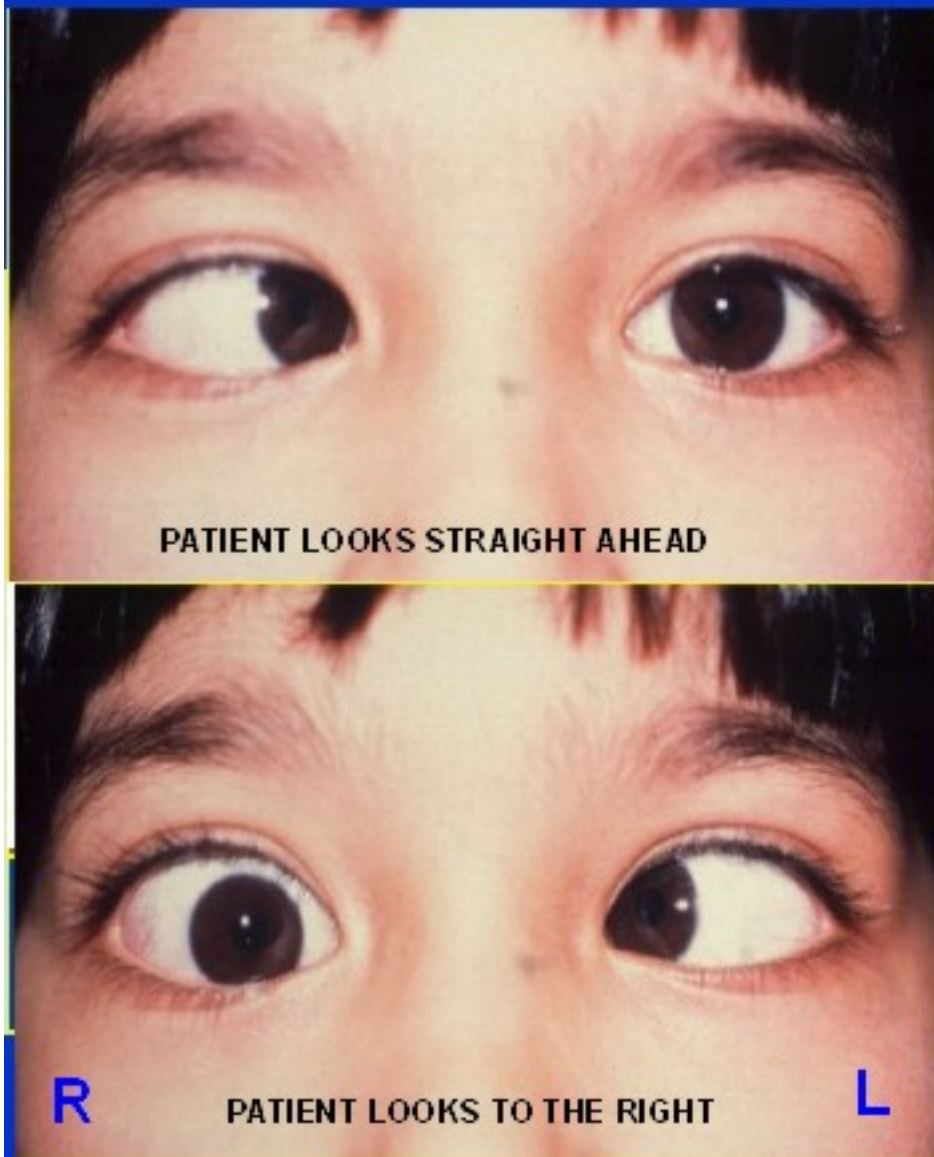
21. ____ A 23-year old soldier states that he has developed recurring headaches over the past 6 months. Treatment with non-steroidal anti-inflammatory drugs (acetaminophen, ibuprofen) provided only partial relief. Neurological testing showed only mild anosmia. An MRI scan (attached) revealed a mass at the base of the anterior cranial fossa that was diagnosed as a meningioma. Which of the following nerves innervates the dura mater in this region and could produce the patient's symptom of headache?

- A. Olfactory nerve (CN I)
- B. Trigeminal nerve (CN V)
- C. C1 spinal nerve
- D. Vagus nerve (CN X)
- E. Facial nerve (CN VII)



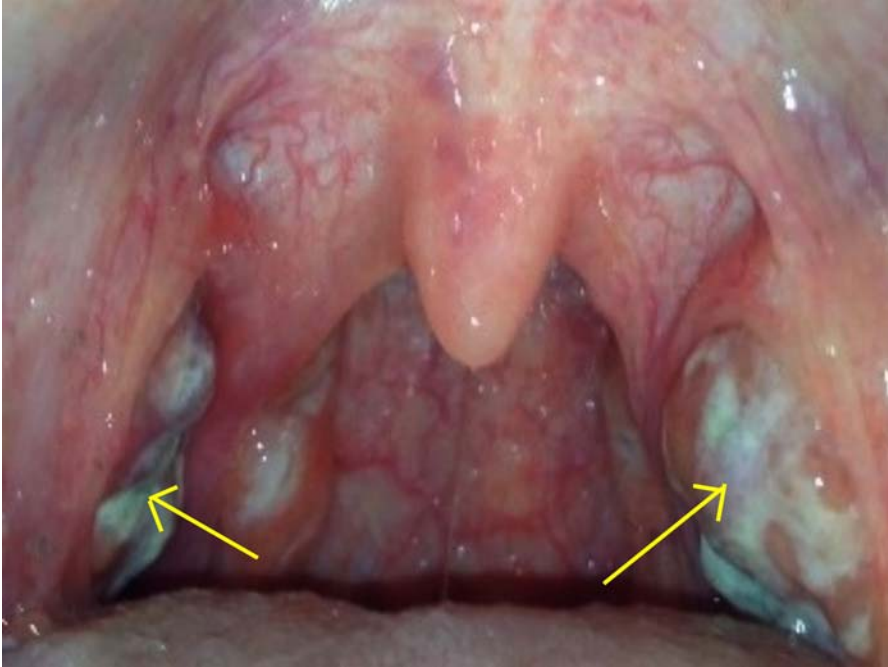
22. ____ A 71-year-old woman was in an automobile accident and her sternum forcibly struck the steering wheel. There was no external trauma to the face or neck. However, she developed progressive visual loss and pulsatile proptosis (bulging of the eye due to dilatation of the veins draining the eye). An angiogram of her Internal Carotid artery (image above) showed bleeding and communication of the artery with the Inferior Ophthalmic vein. She was diagnosed as having an arteriovenous fistula. This fistula is present in which the following structures?

- A. Superior Sagittal sinus
- B. Inferior Sagittal sinus
- C. Cavernous sinus
- D. Superior Petrosal sinus
- E. Inferior Petrosal sinus



23. ____ A 7 year old child states that she is seeing everything 'twice' (double vision). Examination (photo above) shows marked deviation of the right eye when the child tries to look straight ahead. On attempting to look to the right, the left eye moves normally but the right eye shows minimal movement. Which of the following is the most likely cause of these symptoms?

- A. Right Oculomotor nerve palsy
- B. Left Abducens nerve palsy
- C. Right Trochlear nerve palsy
- D. Right Abducens nerve palsy
- E. Left Trochlear nerve palsy



24. ____ A patient is seen because of a very 'sore throat' Inspection of the soft palate (image above) shows enlarged masses in the lateral wall of the oropharynx. The masses are surgically removed and the patient returns home. However, that evening, there is extensive arterial hemorrhage in the oropharynx. This is most likely due to injury to a branch of which of the following arteries?

- A. Superior Thyroid artery
- B. Lingual artery
- C. Facial artery
- D. Posterior Auricular artery
- E. Ophthalmic artery

25. ____ In the case above, the artery was repaired but, in the succeeding weeks, the patient noticed that food tasted strange in the 'back of her mouth'. Tests showed a persistent lack of sensation in the posterior one third of the tongue and loss of a gag reflex. This was most probably due to damage of a branch of which of the following nerves during the initial surgery?

- A. Glossopharyngeal nerve (CN IX)
- B. Vagus nerve (CN X)
- C. Facial nerve (CN VII)
- D. Trigeminal nerve (CN V)
- E. Transverse cervical nerve

26. ____ A 20-year old is in an amateur boxing match and suffers a powerful blow to his cheek. He wins the fight but, in succeeding weeks, he finds that he is unable to keep food between his teeth when he chews on that side. Neurological examination by shows normal function in the Trigeminal and Facial nerves. The physician suspects that the symptoms are due to direct damage to a muscle. Which of the following muscles is mostly likely responsible for the patient's condition.

- A. Temporalis
- B. Depressor anguli oris
- C. Buccinator
- D. Platysma
- E. Mentalis

27. ____ A 6-year old child is seen at a rural clinic for a persistent ear infection on the left side. The parents indicate that the child has had recurrent ear infections for several years that have been resistant to antibiotic treatment. The infection is diagnosed as chronic otitis media and a tympanostomy tube is inserted through the tympanic membrane. The tube is removed after 6 months and successful resolution of the infection. However, the pediatrician carefully tests for potential complications and finds that there is loss of taste to the anterior tongue on the left side. This could indicate damage to which of the following nerves?

- A. Tympanic nerve (CN IX)
- B. Chorda tympani (CN VII)
- C. Auriculotemporal nerve (CN V)
- D. nerve to Stapedius (CN VII)
- E. Buccal nerve (CN V)

HEAD AND NECK QUESTIONS KEY

1. B
2. D
3. D
4. C
5. B
6. A
7. C
8. E
9. E
10. E
11. A
12. A
13. C
14. E
15. A
16. B
17. C
18. B
19. B
20. E
21. B
22. C
23. D
24. C
25. A
26. C
27. B