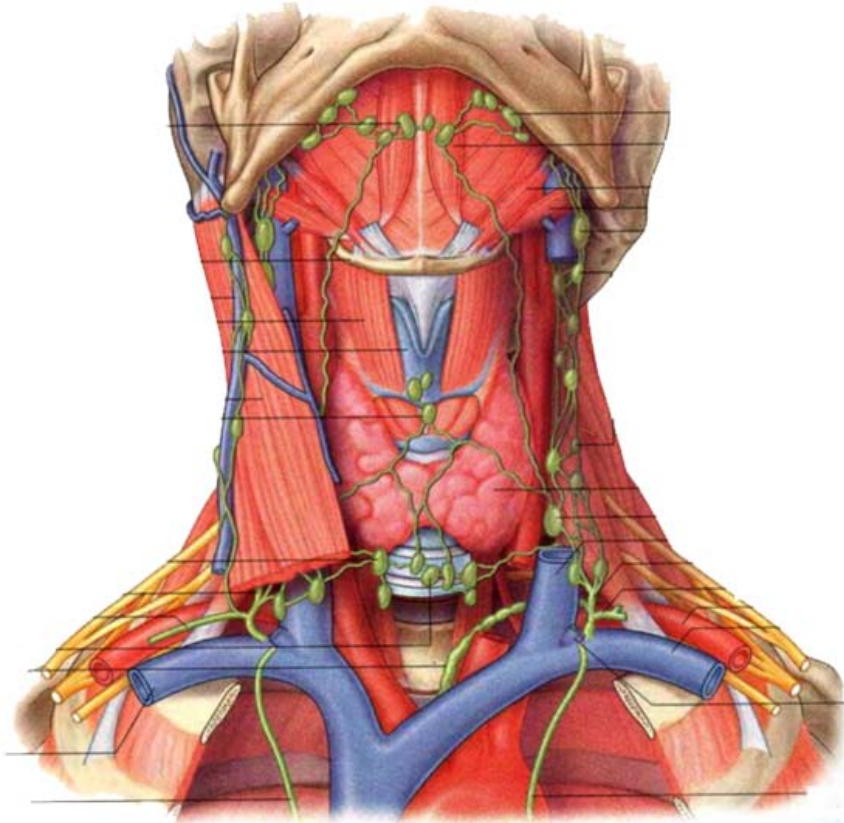


NECK 1 - OUTLINE

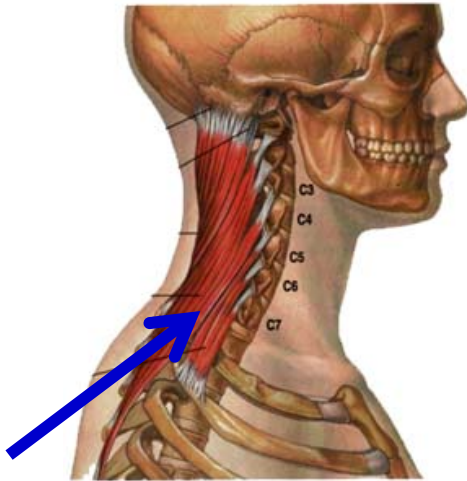


- I. OVERVIEW -
NECK IS
COMPARTMENTALIZED
- II. MUSCLES
- III. NERVES
- IV. ARTERIES
- V. VEINS
- VI. FASCIA
- VII. LYMPHATICS

WORD OF THE DAY - CONTRACTURE - condition of sustained (permanent) SHORTENING of a structure (ex. muscle).

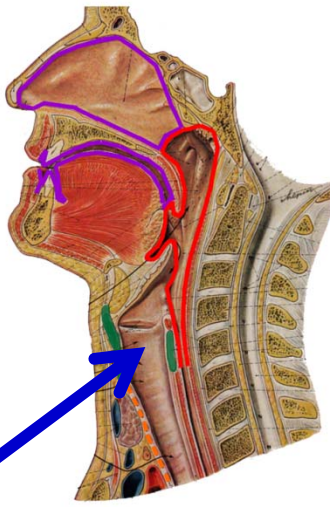
I. OVERVIEW OF NECK - neck is compartmentalized

disease processes in or between compartments



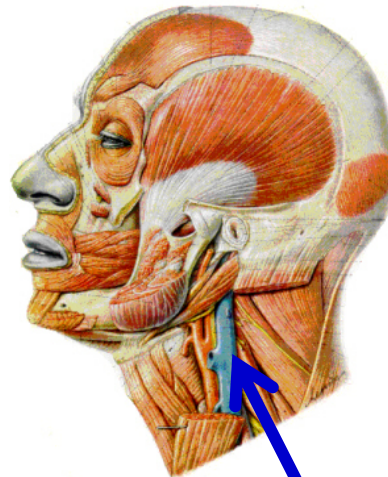
Posterior - **Vertebrae and Muscles**

1. Posterior
Compartment -
Vertebrae and
muscles which
support and move
head and neck



Anterior - **Viscera**
(Pharynx, Larynx, etc.)

2. Anterior
Compartment- Viscera
and rostral
continuation GI and
Respiratory Systems



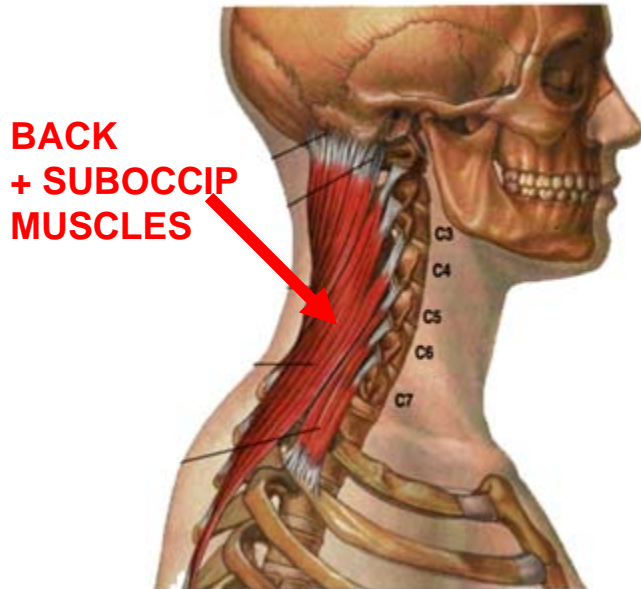
Lateral - **Carotid Sheath**

3. Lateral
Compartment- Blood
vessels and nerve

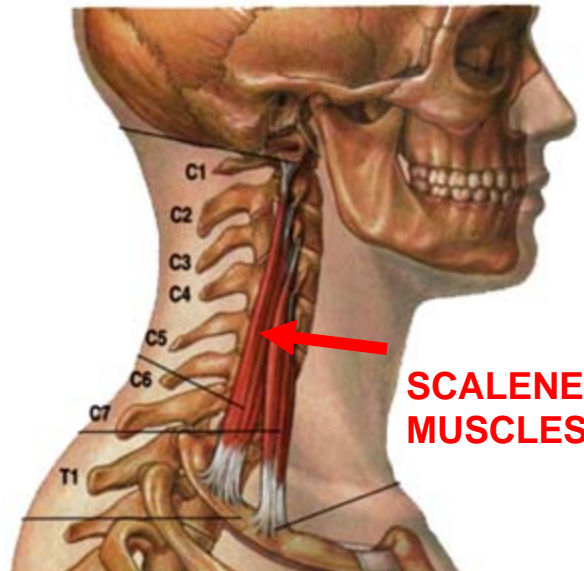
1. POSTERIOR COMPARTMENT

- muscles that move head and neck

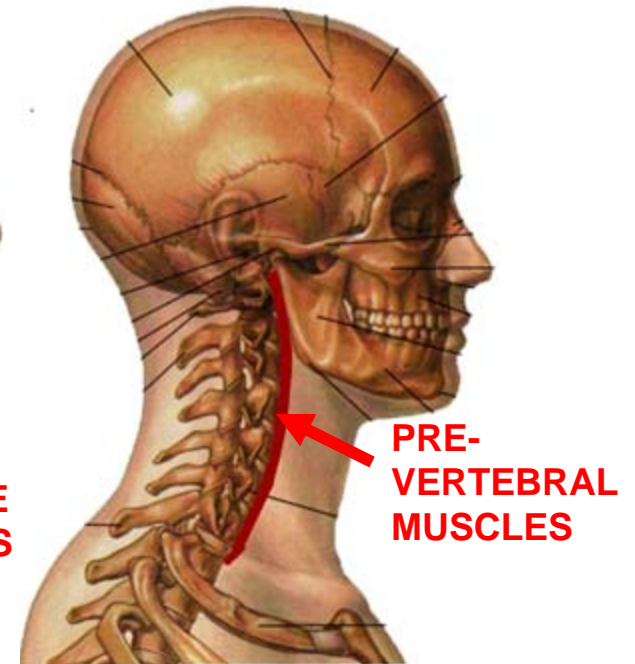
NECK IS MOBILE



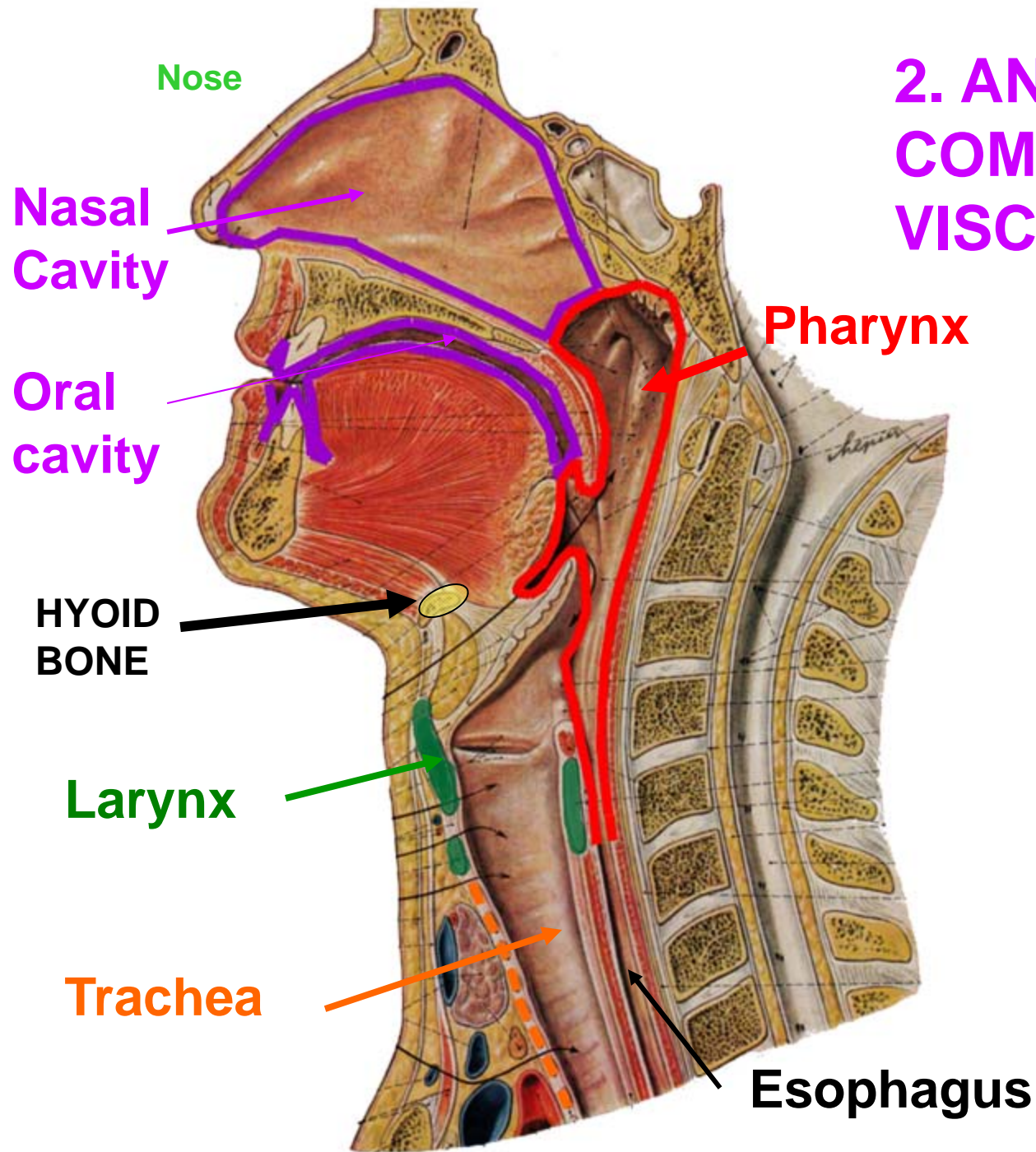
**Posterior side -
Deep Muscles
(extensors like
back) and
Suboccipital
Muscles**



**Lateral side -
Scalene
muscles - flex
neck laterally
(IMPORTANT
LANDMARKS FOR
NERVES, ETC.)**



**Anterior side -
Prevertebral Muscles -
directly anterior to
vertebrae - flex head
and neck (anterior
movement)**

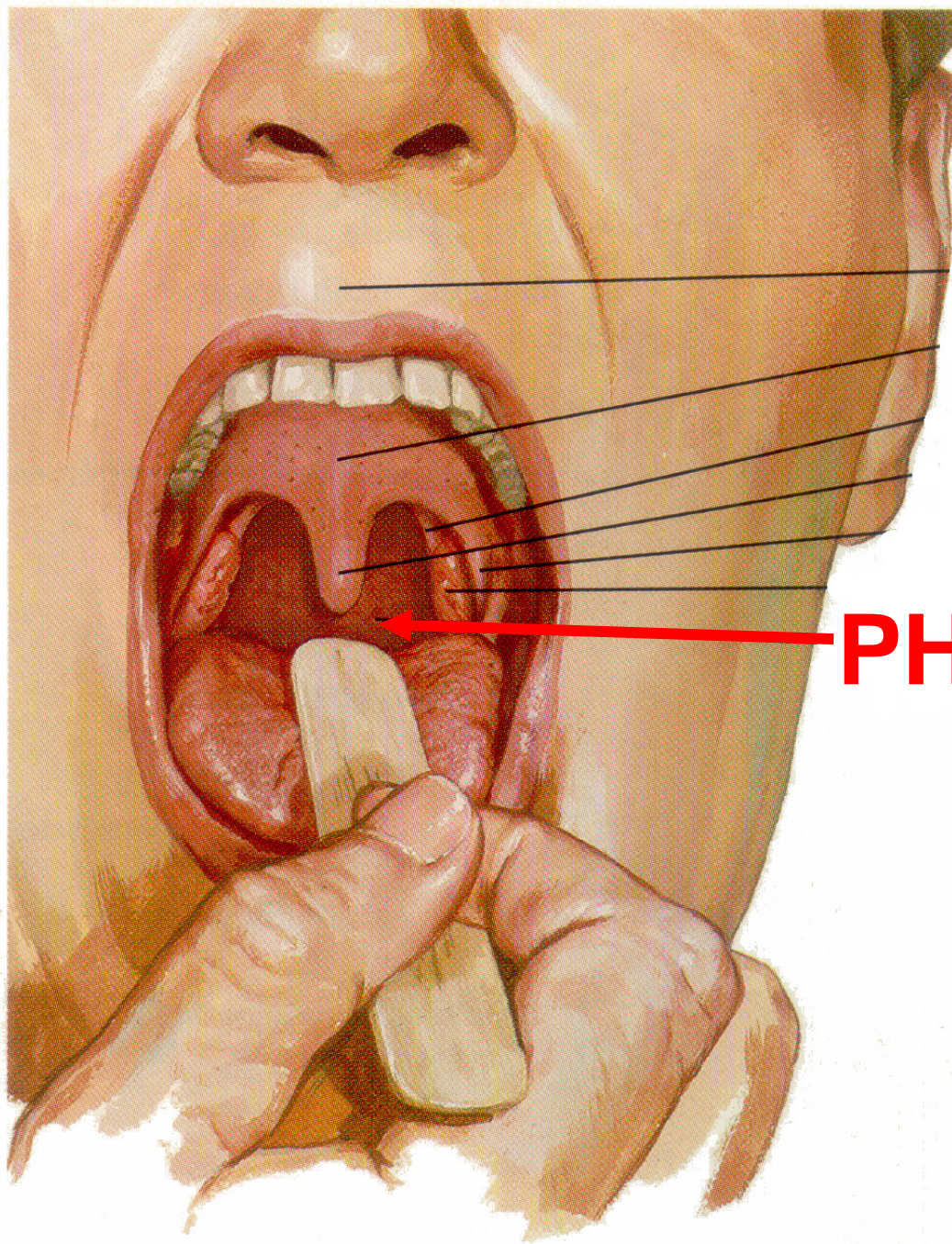


2. ANTERIOR COMPARTMENT - VISCERA

1) **Larynx & Esophagus** open into **pharynx**

2) **Pharynx** - a **tube of muscles and fascia** that **opens to nasal and oral cavities**

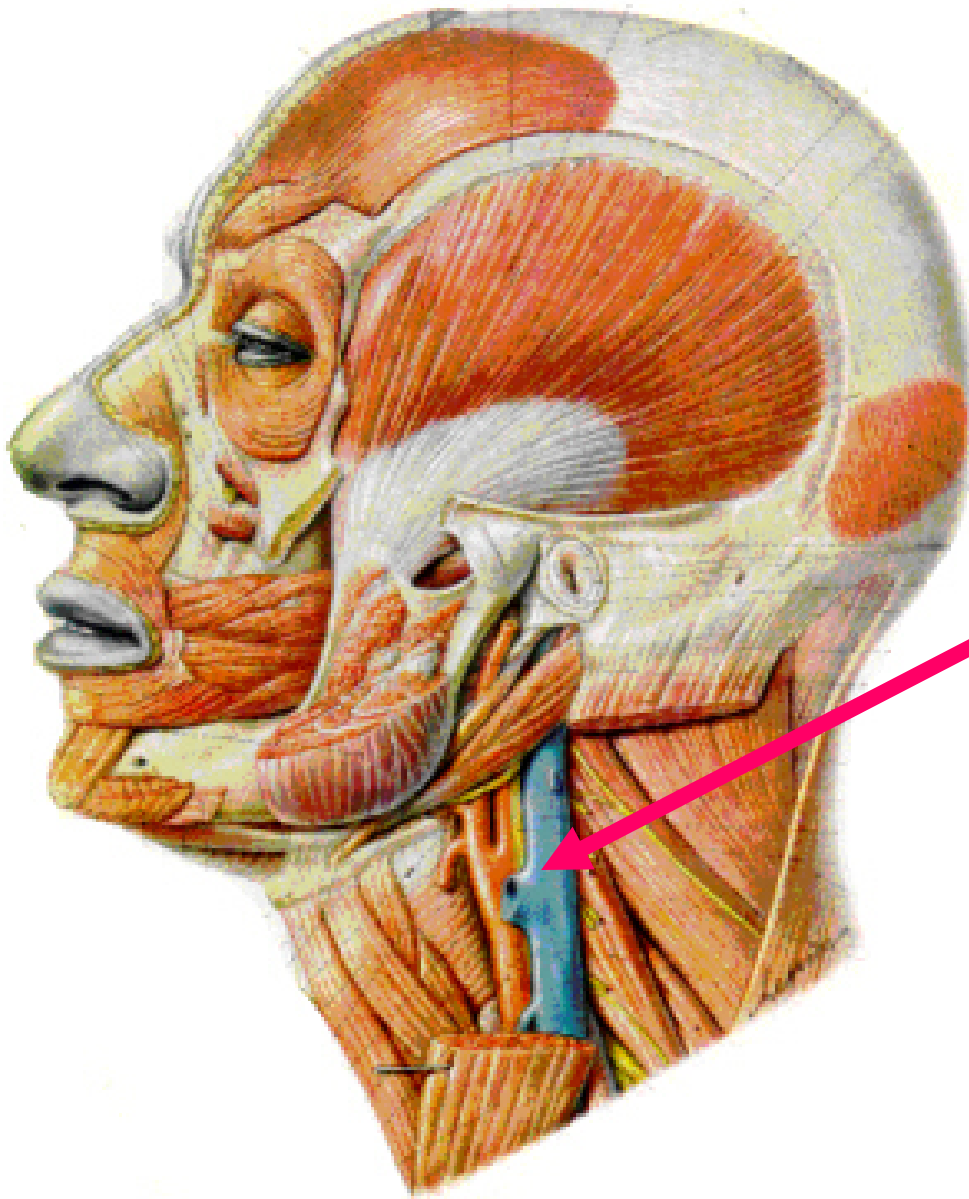
**SAY
AAHH!**



PHARYNX

3. LATERAL COMPARTMENT - CAROTID SHEATH

CLINICAL **



Lateral Compartment-
lateral and posterior to
pharynx

Contained in Carotid
Sheath

1) Common and Internal
Carotid arteries; 2)
Internal jugular vein, 3)
Vagus nerve

Note: Sympathetic chain
is posterior to (NOT IN)
Carotid Sheath

II. MUSCLES OF NECK

**KNOW MUSCLE, ACTION, INNERVATION;
NOT REQUIRED: ORIGIN, INSERTION**

Muscles not attached to Hyoid bone

MUSCLE		INSERTION	ACTION	NERVE
Sternodeioidomastoid	Two heads 1) Sternum - Manubrium 2) Clavicle - medial 1/3	Both heads to Temporal bone - Mastoid process	Acting on both sides - flex neck; Acting singly - rotate head so face is directed to opposite side	Accessory nerve (XI)
Scalenus anterior and Scalenus medius	Vertebra- transverse processes of upper cervical	Rib 1	Flex neck and elevate rib 1	branches of ventral rami of cervical spinal nerves

Infrahyoid muscles

MUSCLE	ORIGIN	INSERTION	ACTION	NERVE
Omohyoid (Muscle has two bellies connected by an intermediate tendon)	Inferior belly from Scapula - medial to suprascapular notch (Intermediate tendon - linked to clavicle and rib 1) Superior belly - continues to insertion	Hyoid Bone	Depresses hyoid bone	Ansa cervicalis
Sternohyoid	Sternum - manubrium Clavicle	Hyoid bone	Depresses hyoid bone	Ansa cervicalis
Sternothyroid	Sternum - manubrium	Thyroid cartilage	Depresses thyroid cartilage, indirectly depresses hyoid bone, larynx	Ansa cervicalis
Thyrohyoid	Thyroid cartilage	Hyoid bone	Depresses hyoid bone, elevates larynx	C1 via branch hitchhiking with Hypoglossal nerve (XII)

A. MUSCLES OF NECK - NOT ATTACHED TO HYOID - move head and neck

1. STERNO-CLEIDOMASTOID

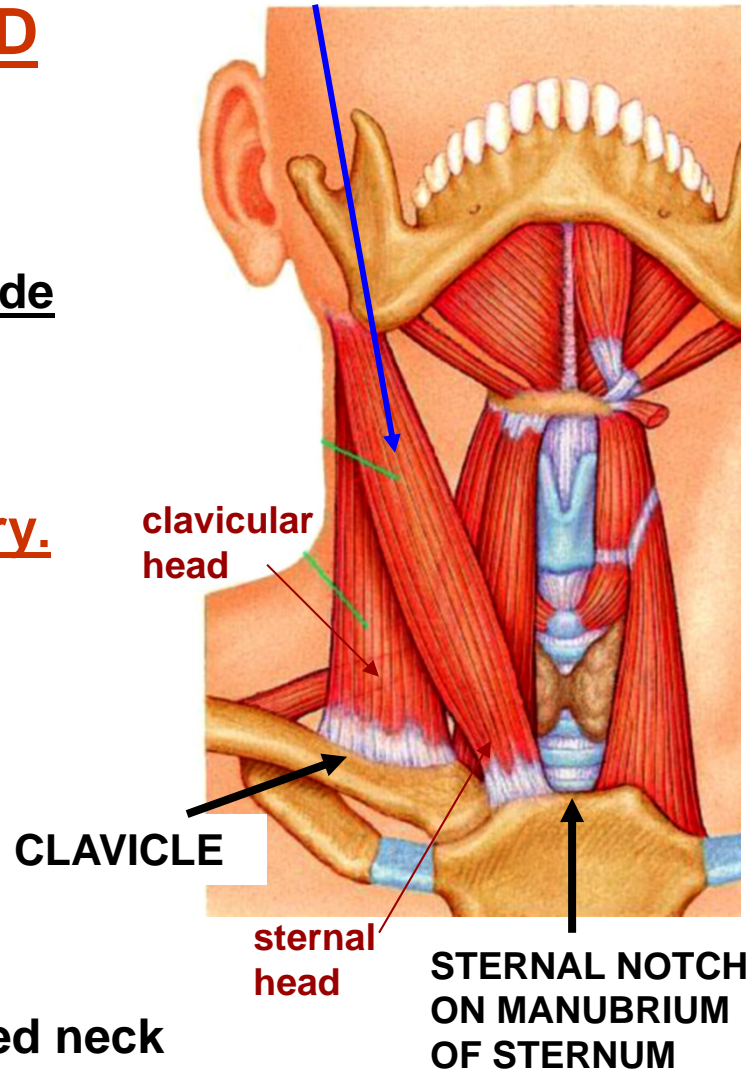
ACTIONS - bilateral - flex head; unilateral rotate head, face directed to opposite side

(MASTOID MOVES TOWARD STERNUM)

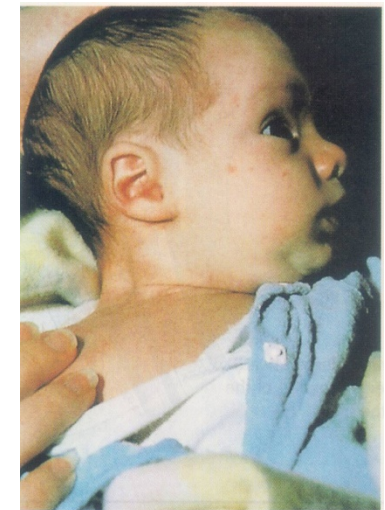
Inn - CN XI Accessory.

TORTICOLLIS = twisted neck

MOST IMPORTANT LANDMARK IN NECK

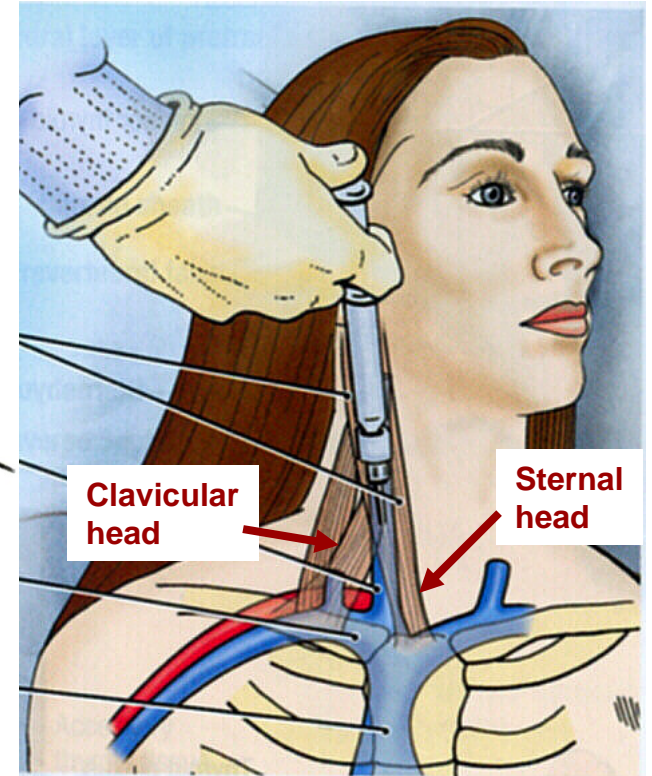
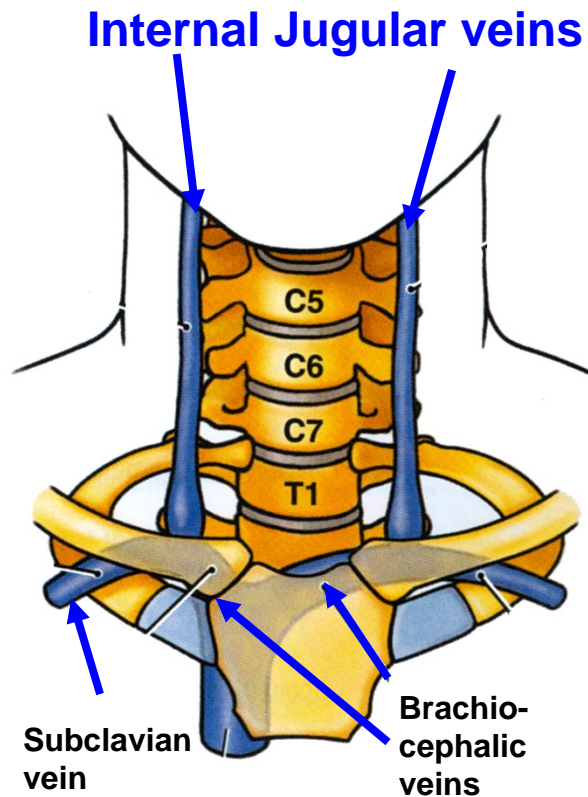
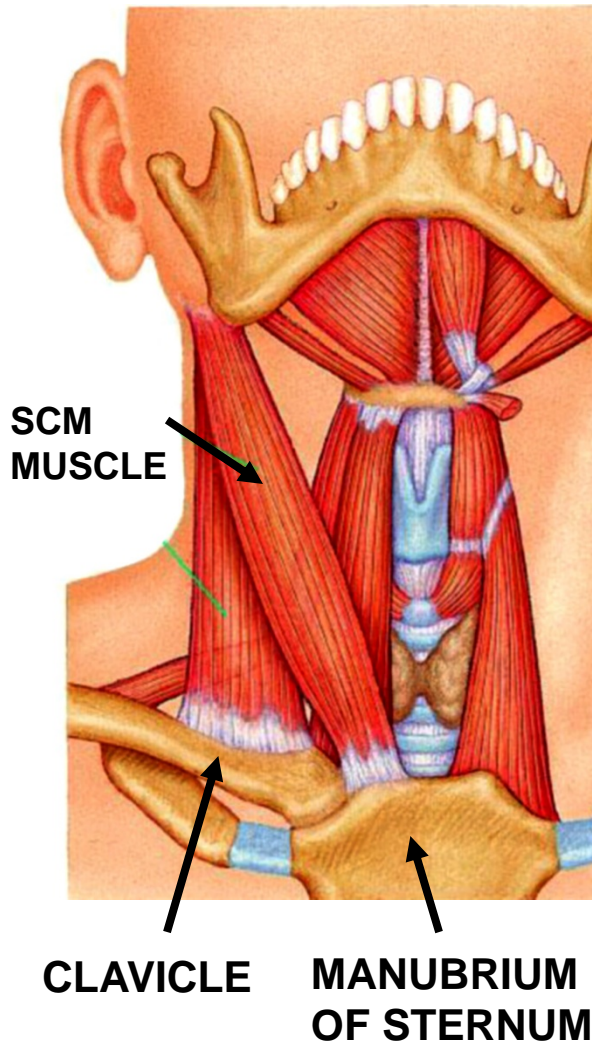


ACTION - PULL MASTOID TOWARD STERNUM



*** TORTICOLLIS – Contracture of Sternocleidomastoid (congenital or acquired); face to opposite side**

STERNOCLEIDOMASTOID: IMPORTANT LANDMARK IN PROCEDURES: VENOUS CATHETERIZATION

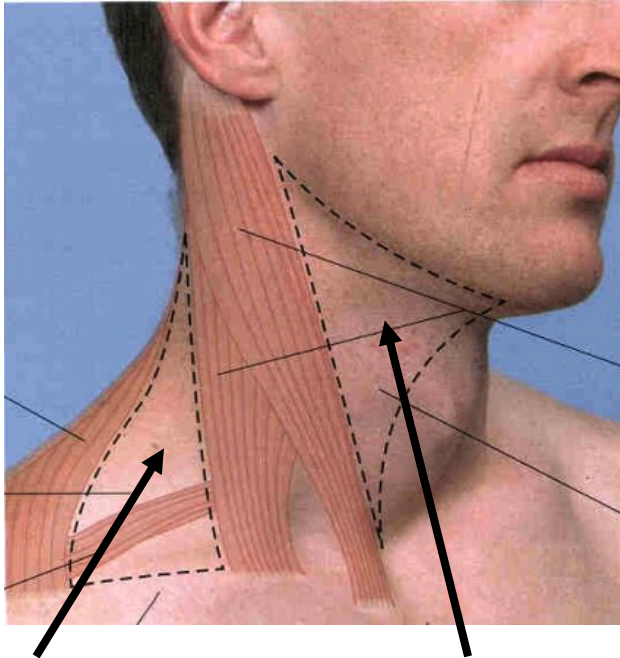


Internal Jugular vein can be accessed and catheterized **between Sternal and Clavicular heads** of Sternocleidomastoid

feel sternal head on yourself

STERNOCLEIDOMASTOID: IMPORTANT LANDMARK IN EXAMINATION OF NECK

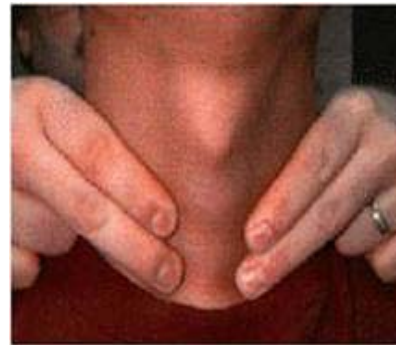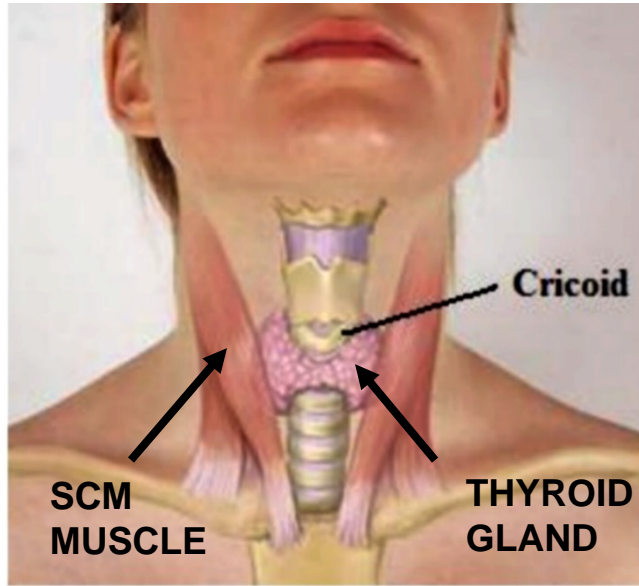
Sternocleidomastoid (SCM) defines areas in Neck



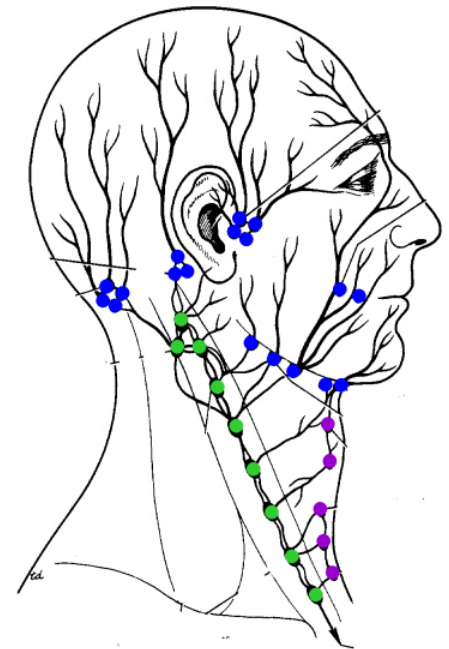
POSTERIOR TRIANGLE
(Post. to Sternocleidomastoid)

ANTERIOR TRIANGLE
(Ant. to Sternocleidomastoid)

Thyroid gland: palpated in Anterior Triangle below Cricoid cartilage, medial to Sternocleidomastoid



Stand behind patient; have patient swallow



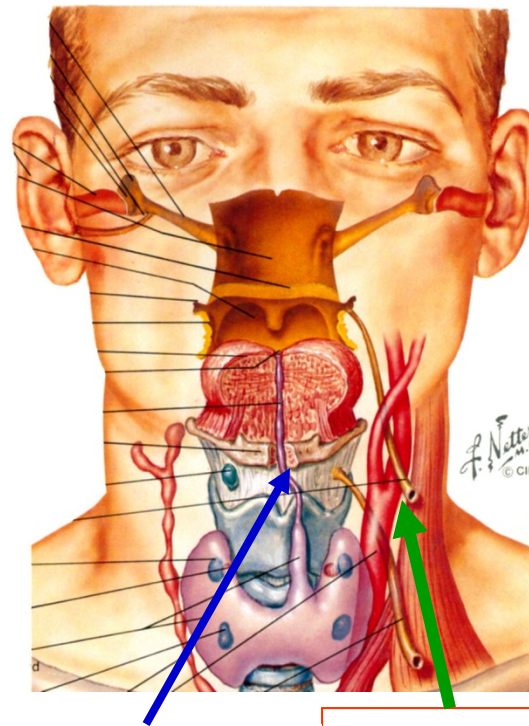
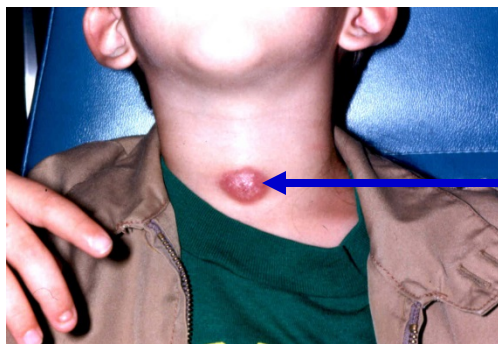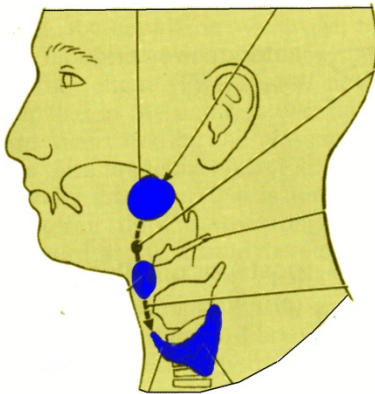
Deep Cervical Chain of Lymph nodes are located **deep to Sternocleidomastoid**

ICS: ENT EXAM
Spring 2020

USE STERNOCLEIDO MASTOID TO DIAGNOSE NECK MASSES: BRANCHIAL CLEFT CYSTS, FISTULI LATERAL NECK MASSES

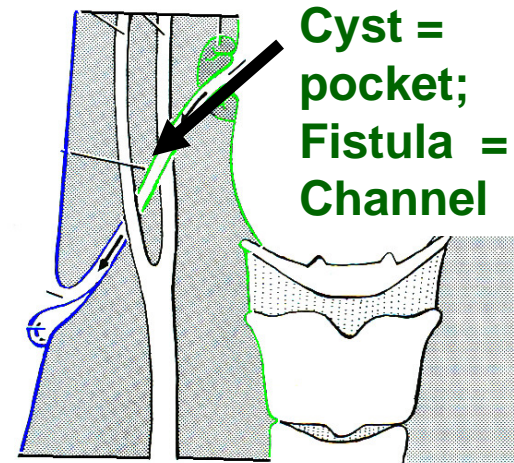
LATERAL NECK MASS - Branchial Cyst or (Fistula = Channel) -
located Anterior to Sternocleidomastoid Muscle

Differentiate from
Thyroglossal Duct Cysts
- Midline masses



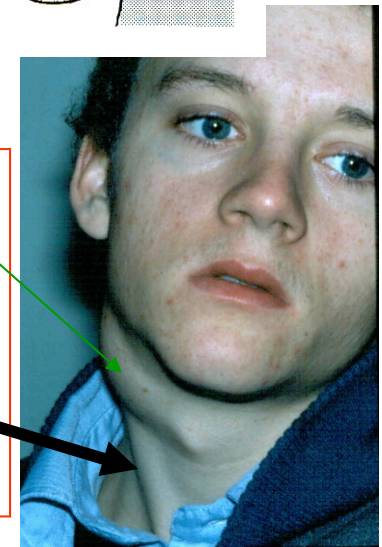Thyroglossal
Duct Cysts -
Midline
mass

Branchial
Cysts,
Fistula -
Lateral
neck mass



Cyst =
pocket;
Fistula =
Channel

Branchial
Cyst -
Anterior
to Sterno-
cleido-
mastoid

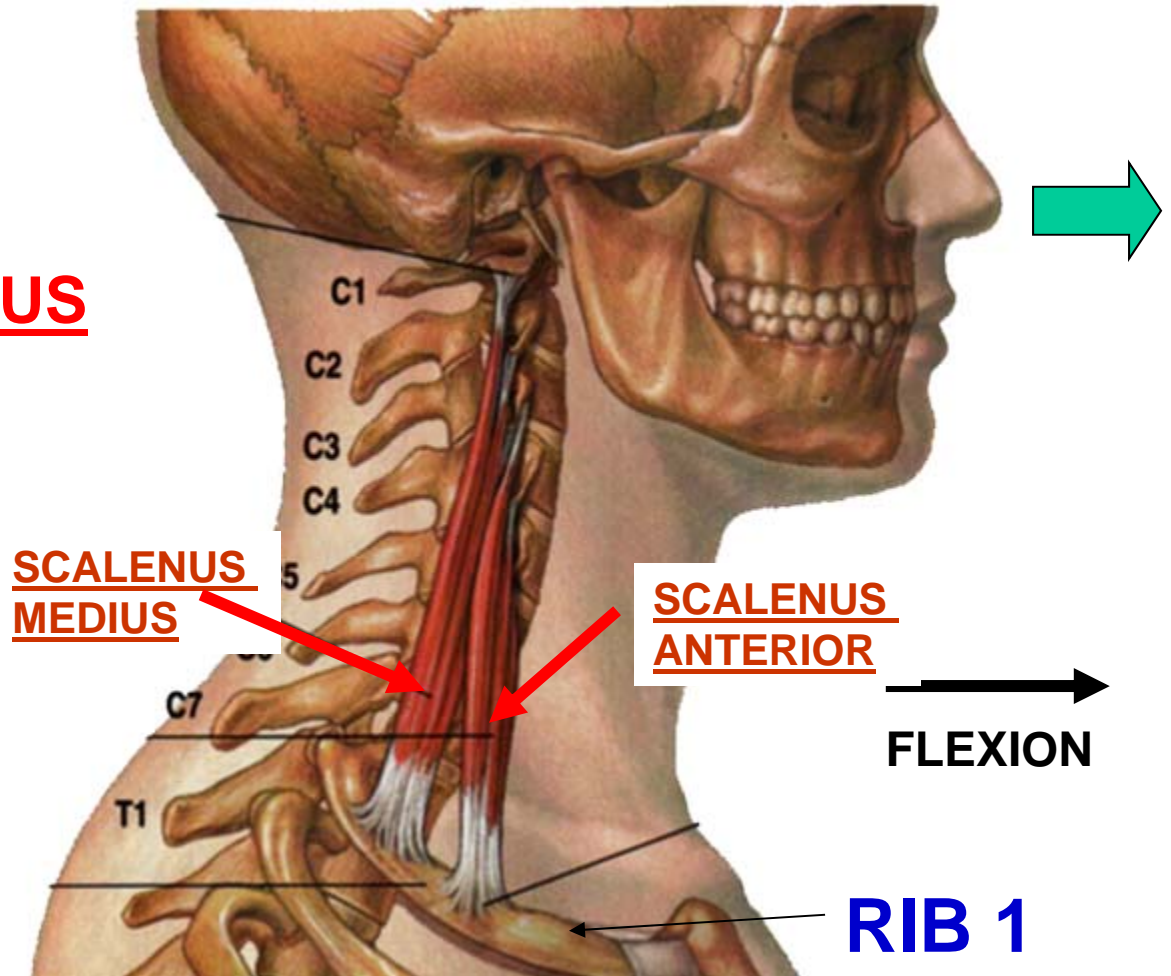


MUSCLES OF NECK - NOT ATTACHED TO HYOID

2. SCALENUS ANTERIOR AND SCALENUS MEDIUS

A - flex neck, elevate rib 1

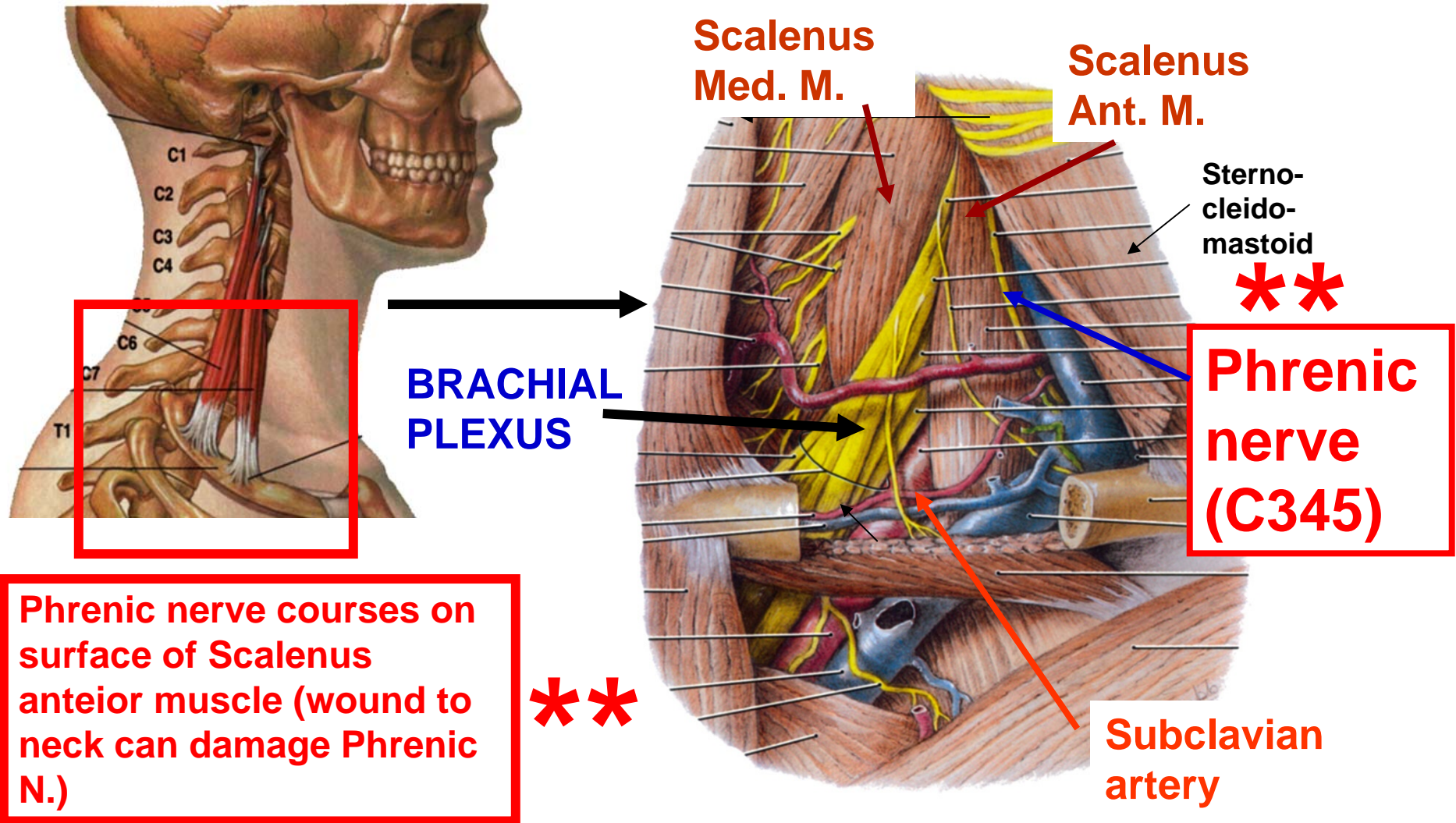
Inn - ventral rami of cervical spinal nerves



SCALENUS ANTERIOR - SECOND MOST IMPORTANT LANDMARK IN NECK: BRACHIAL PLEXUS, PHRENIC NERVE; LATERAL (POSTERIOR) TO STERNOCLEIDOMASTOID

SCALENUS ANTERIOR AND SCALENUS MEDIUS ARE IMPORTANT LANDMARKS

- **Brachial Plexus**, Subclavian Artery pass between Scalenus Ant. and Med.;
- **Phrenic nerve** (to Diaphragm) **courses on Scalenus Anterior**

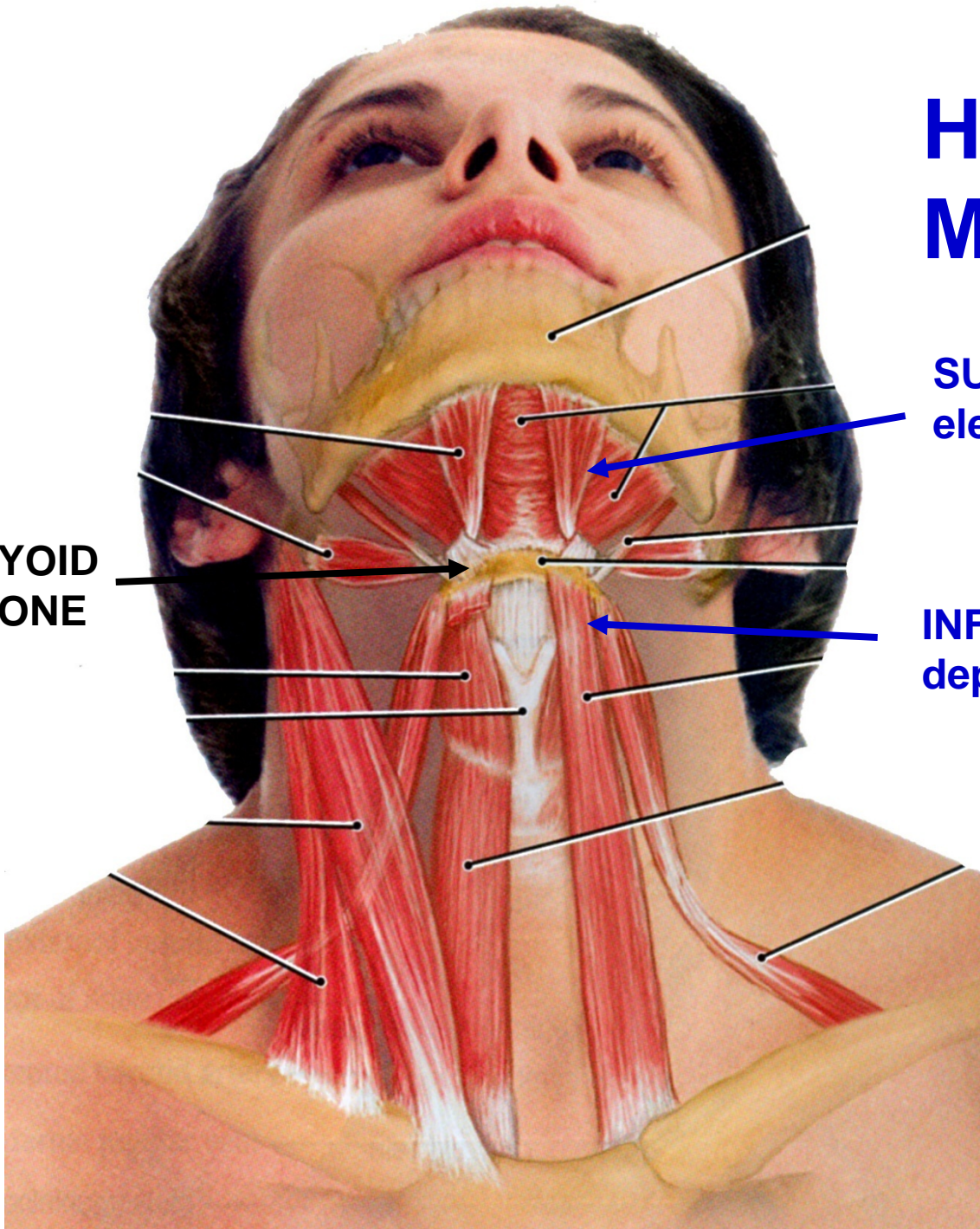


HYOID MUSCLES

HYOID
BONE

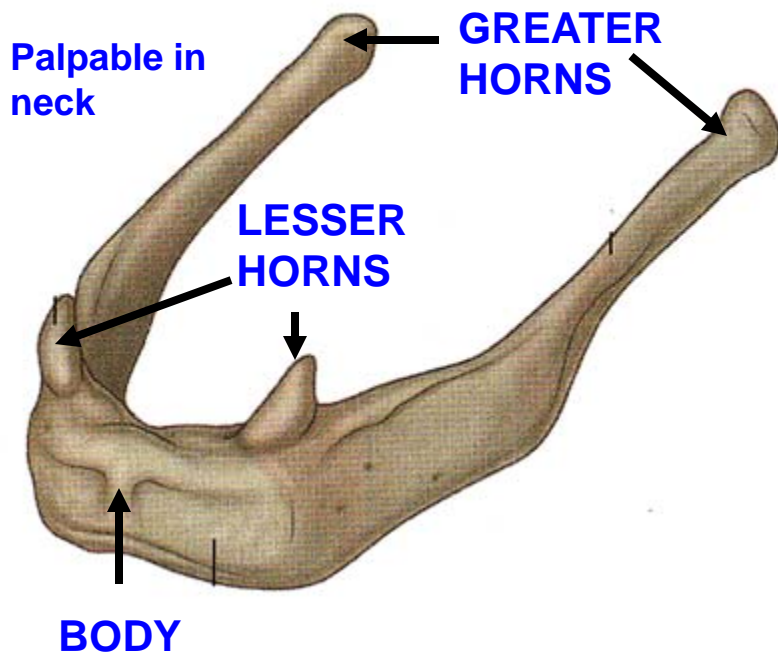
SUPRAHYOID MUSCLES -
elevate hyoid

INFRAHYOID MUSCLES -
depress hyoid

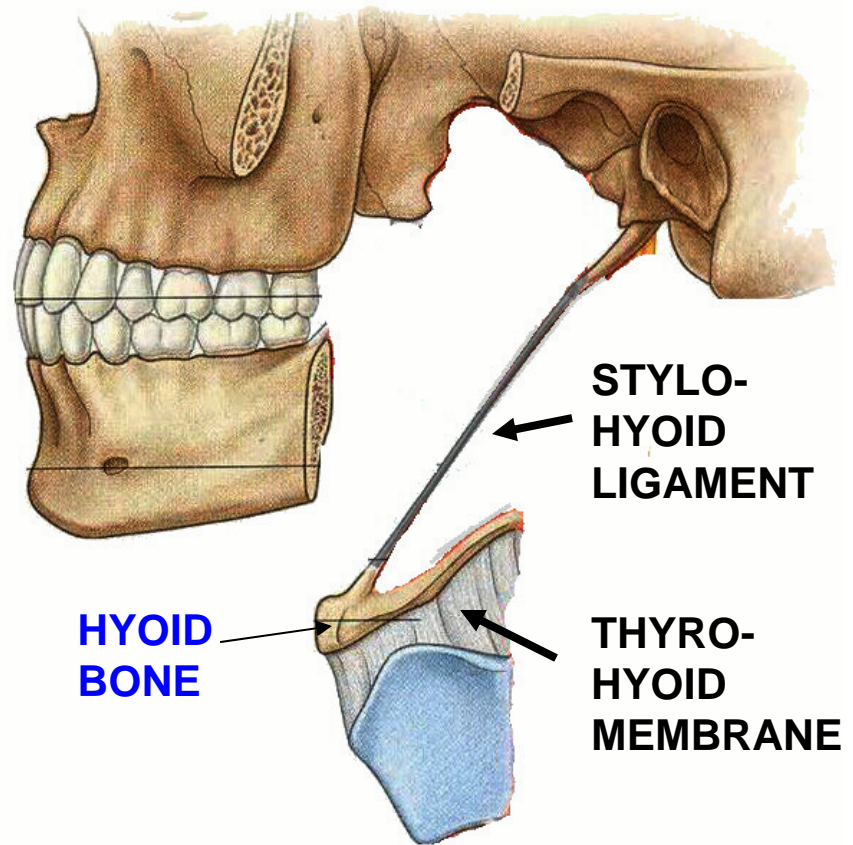


A. HYOID BONE - 'free floating', no bony attachment; held by muscles, ligaments

Parts: Body, Greater and Lesser Horns; **Hyoid means "U" shaped**



- All Infrahyoid & Suprahyoid attach to Body of Hyoid (except Sternothyroid inserts to thyroid cartilage)



Stylohyoid ligament - to Styloid process of temporal bone

Thyrohyoid membrane - to Thyroid cartilage

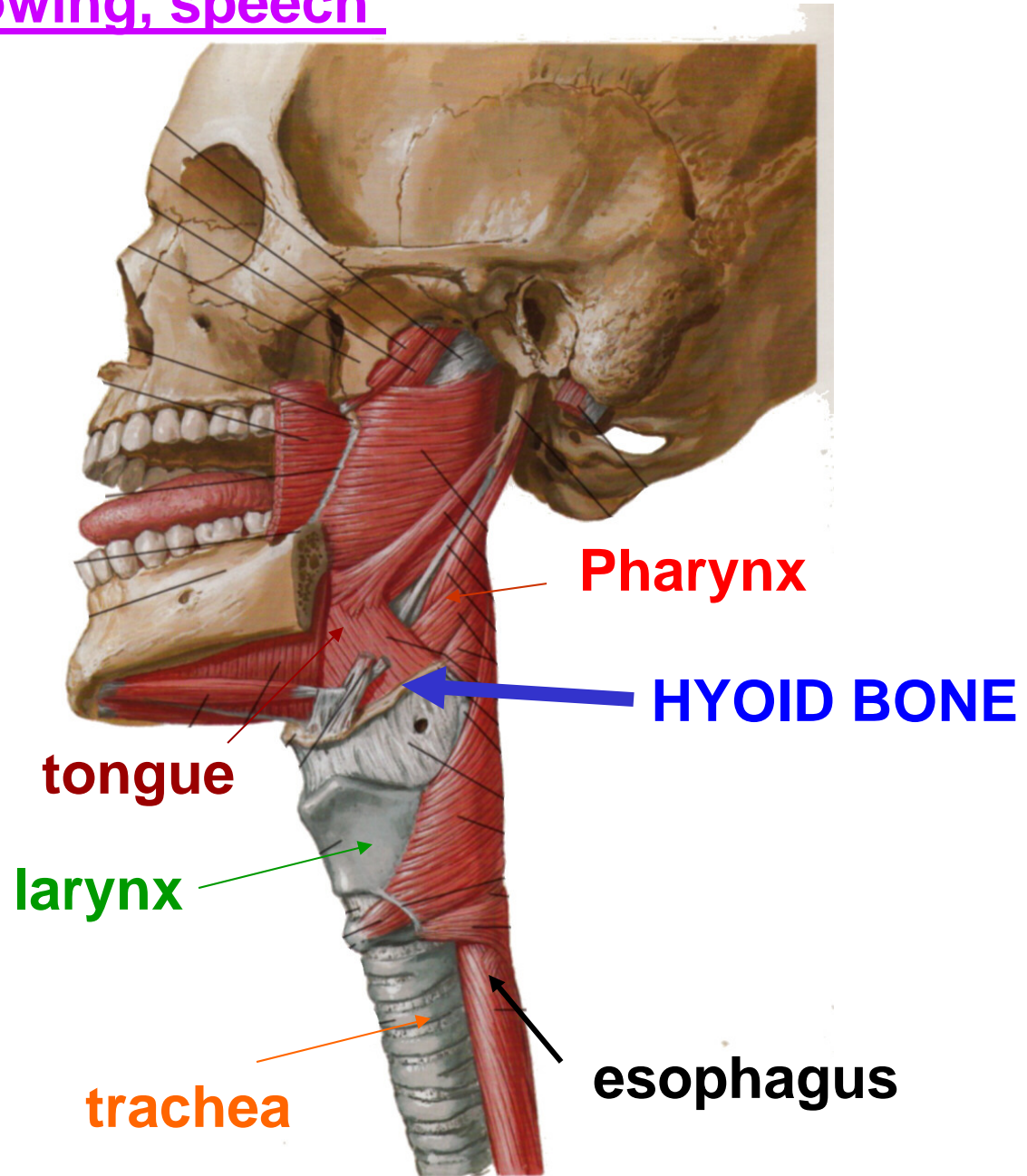
STRUCTURES DERIVED FROM BRANCHIAL ARCHES

ARCH/NERVE	SKELETAL	LIGAMENTS	MUSCLES
First (V)	1) Malleus 2) Incus	1) Ant. ligament of malleus 2) Spheno-mandibular ligament	1) Muscles of Mastication 2) Tensor tympani 3) Tensor palati 4) Mylohyoid 5) Ant. belly of Digastric
Second (VII)	1) Stapes 2) Styloid process 3) Hyoid bone - lesser horn, upper half of body	Stylohyoid ligament	1) Muscles of Facial Expression 2) Stapedius 3) Stylohyoid 4) Post. belly of Digastric
Third (IX)	Hyoid bone - greater horn, lower half of body	-----	Stylopharyngeus
Fourth (X)	Cartilages of Larynx	-----	1) All muscles of Larynx 2) All muscles of Pharynx (except Stylopharyngeus) 3) All muscles of Soft Palate (except Tensor palati)
Sixth (XI)	-----	-----	1) Sternocleidomastoid 2) Trapezius

HYOID BONE DEVELOPS AS ADAPTATION TO LIFE ON LAND - SPEECH, SWALLOWING

ANTERIOR COMPARTMENT - moveable, changes shape in swallowing, speech

Hyoid Bone – attached to larynx, pharynx and tongue; free floating; attached by ligaments and moved by muscles

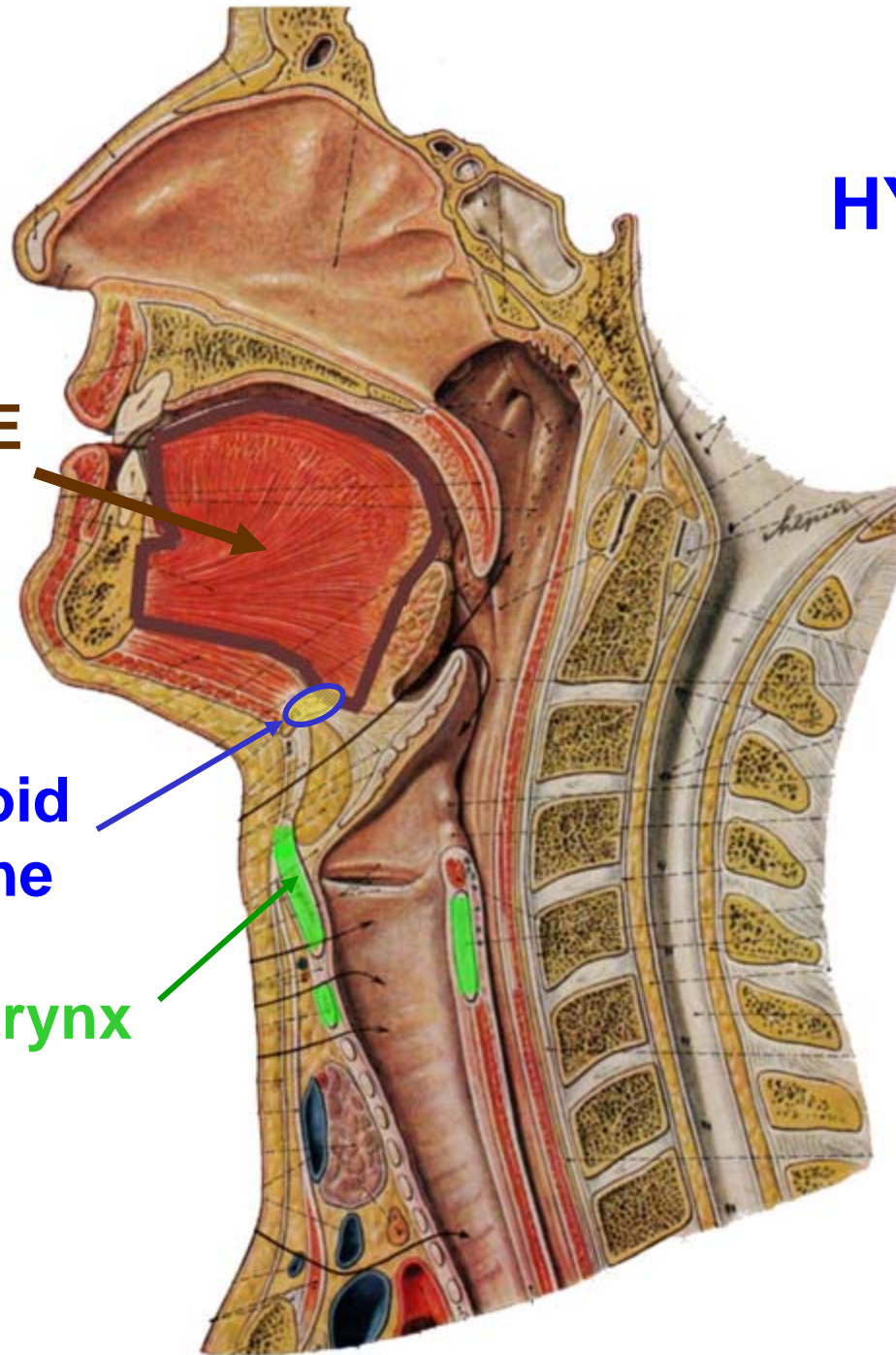


HYOID BONE

TONGUE

Hyoid Bone

Larynx



- muscles that move hyoid bone move larynx and tongue, for Swallowing, Talking

- contraction of muscles can stabilize position of hyoid bone (ex. in movements of tongue)

INFRAHYOID MUSCLES - all depress hyoid - many named for origin/insertion

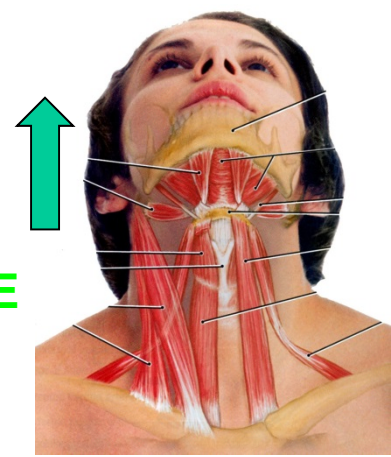
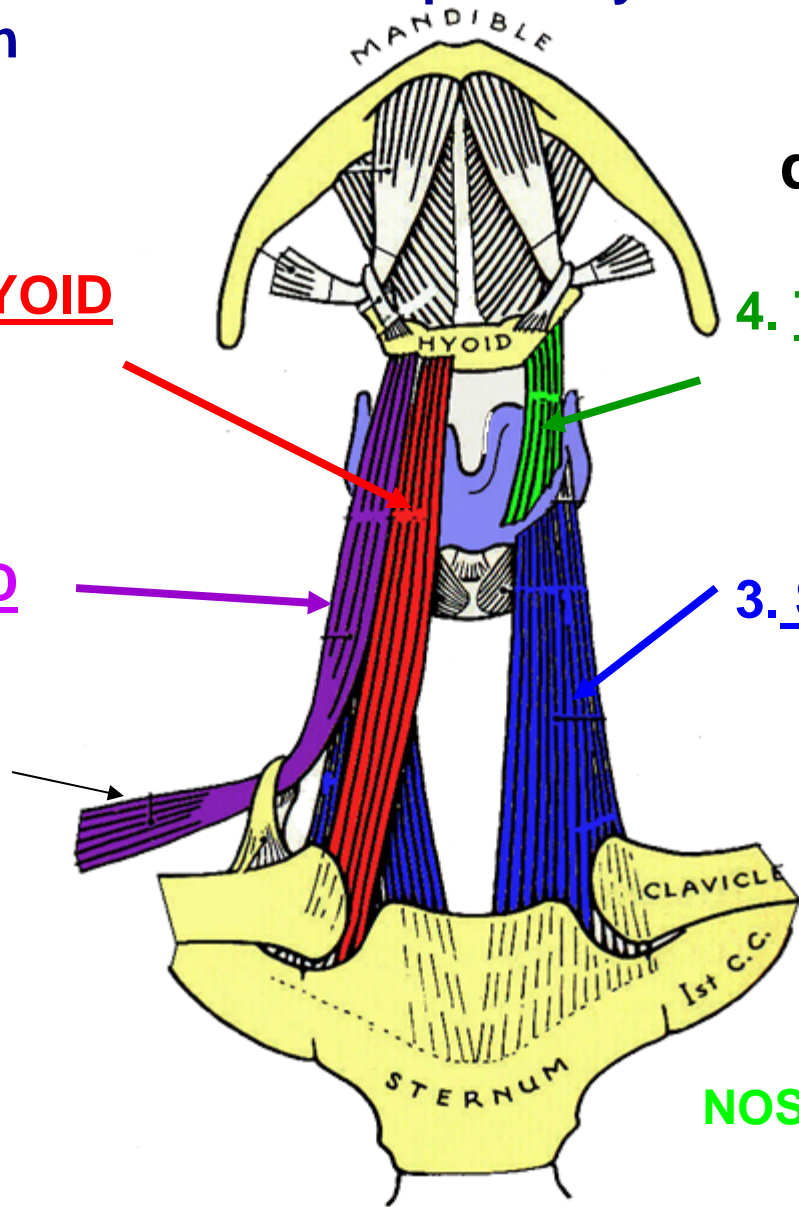
2. STERNOHYOID

1. OMOHYOID

deeper

4. THYROHYOID

3. STERNOHYOID



ORIENT -
HEAD
TILTED
BACK

NOSE

SUPRAHYOID MUSCLES - all elevate hyoid

Suprahyoid muscles

MUSCLE	ORIGIN	INSERTION	ACTION	NERVE
Digastric (has two bellies)	Posterior belly from Temporal bone - mastoid notch (medial to mastoid process) Anterior belly from Mandible - inner side	Hyoid Bone - via intermediate tendon	Elevates hyoid bone, Depresses mandible	Posterior belly - Facial nerve (VII) Anterior belly - Trigeminal nerve (V3)
Stylohyoid	Temporal bone - styloid process	Hyoid bone	Elevates hyoid bone	Facial nerve (VII)
Mylohyoid	Mandible - mylohyoid line	Hyoid bone	Elevates hyoid bone, Raises floor of mouth during swallowing	Trigeminal nerve (V3)
Geniohyoid	Mandible - inner side	Hyoid bone	Elevates hyoid bone, draws hyoid forward	C1 via branch hitch-hiking with Hypoglossal nerve (XII)

SUPRAHYOID MUSCLES - all elevate hyoid

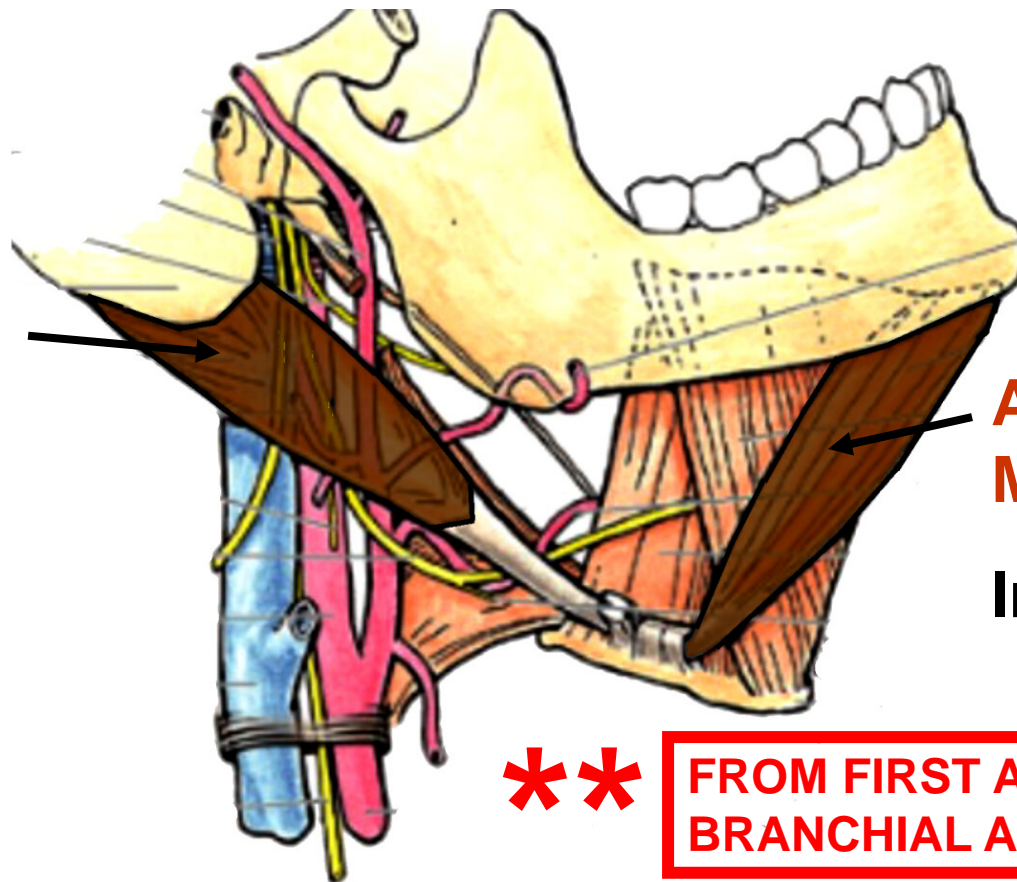
1. DIGASTRIC - two bellies / two cranial nerves - insert to hyoid via intermediate tendon

NOSE



Post Belly-
Temp. Bone

Inn - CN VII



Ant. Belly -
Mandible

Inn. - CN V

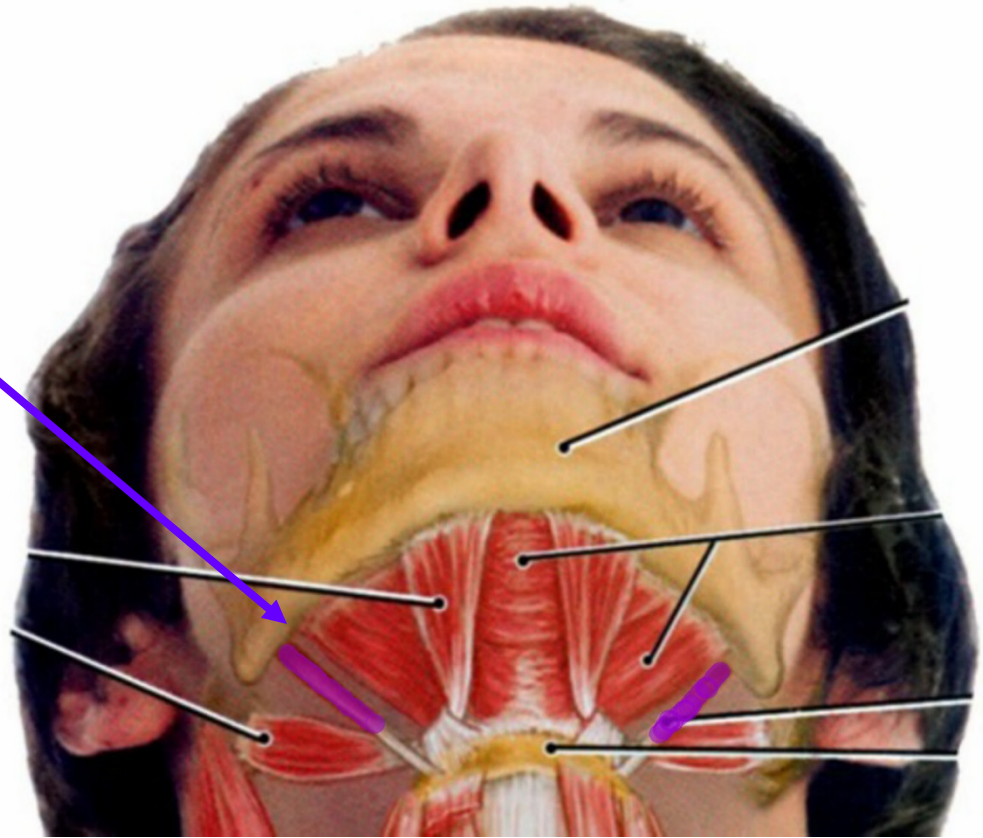
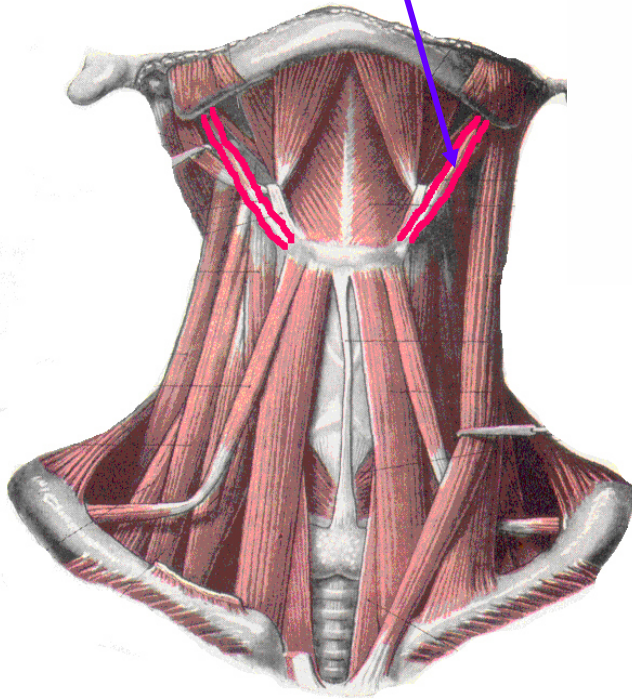
FROM FIRST AND SECOND
BRANCHIAL ARCH

Act - Depress mandible - MAJOR EFFECT is OPEN MOUTH

SUPRAHYOID MUSCLES - all elevate hyoid

2. STYLOHYOID

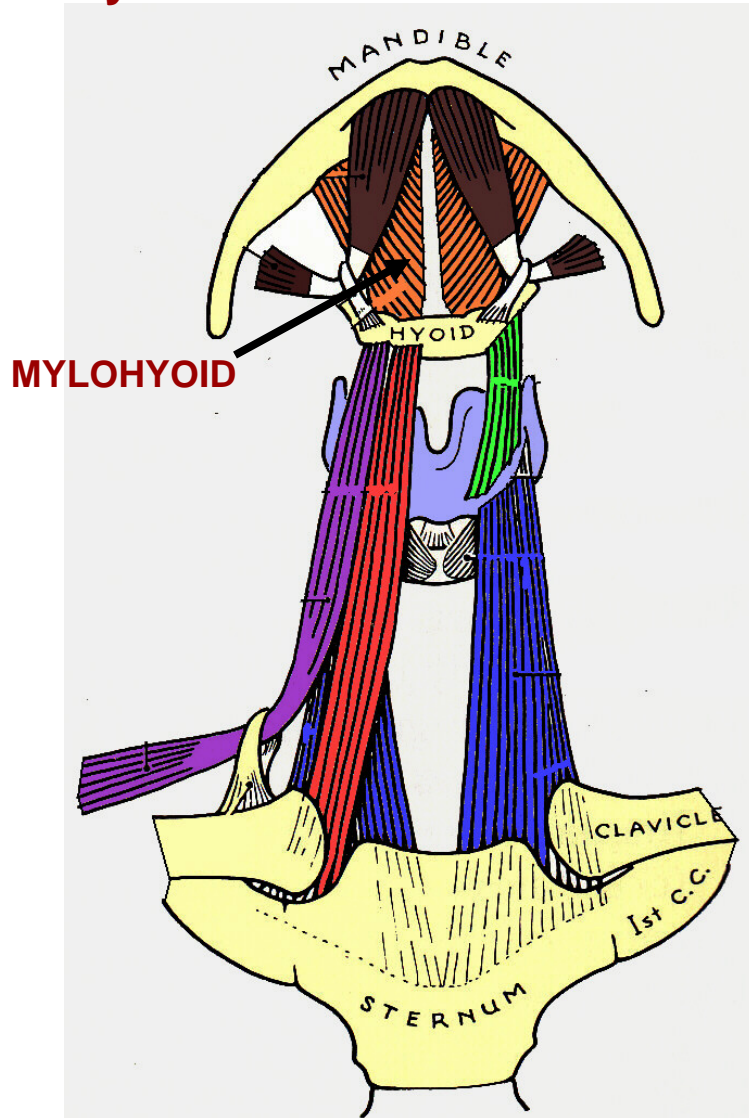
Inn - CN VII



SUPRAHYOID MUSCLES - all elevate hyoid

3. MYLOHYOID - forms muscular floor of mouth

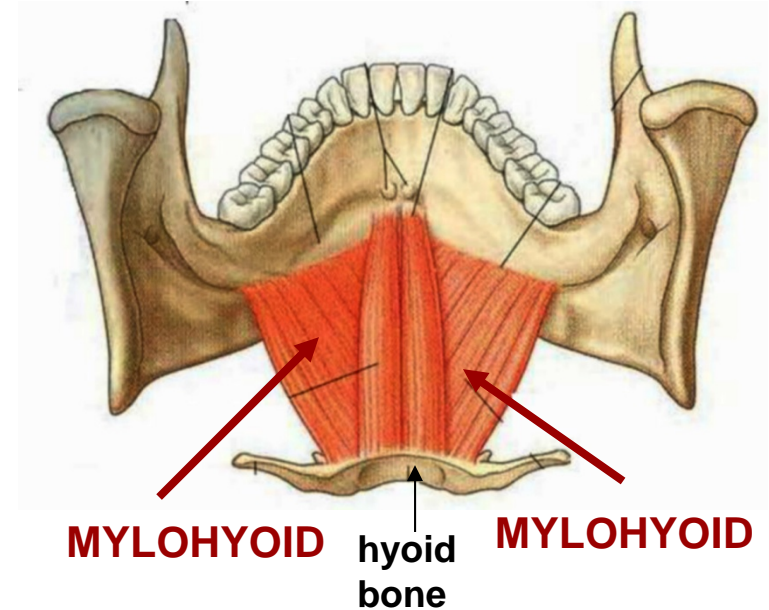
mylo = Gk. molar tooth



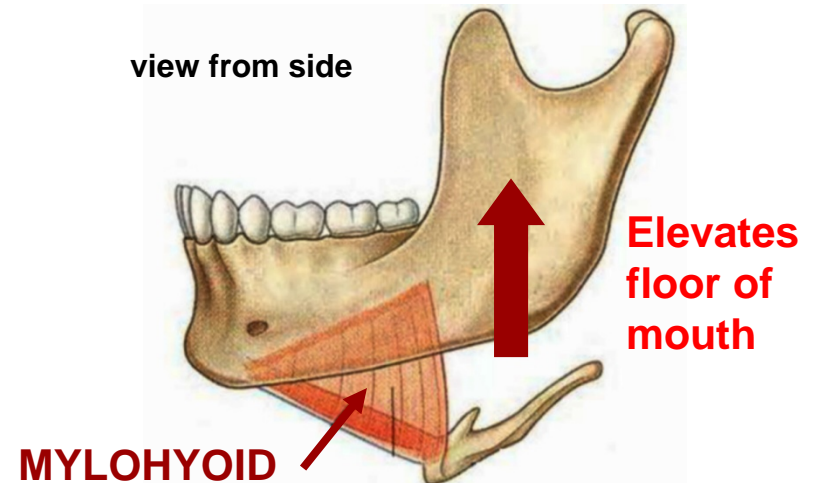
mandible
Action -
Elevates
floor of
mouth in
swallowing

Inn - CN V -
from V3

view from inside mouth

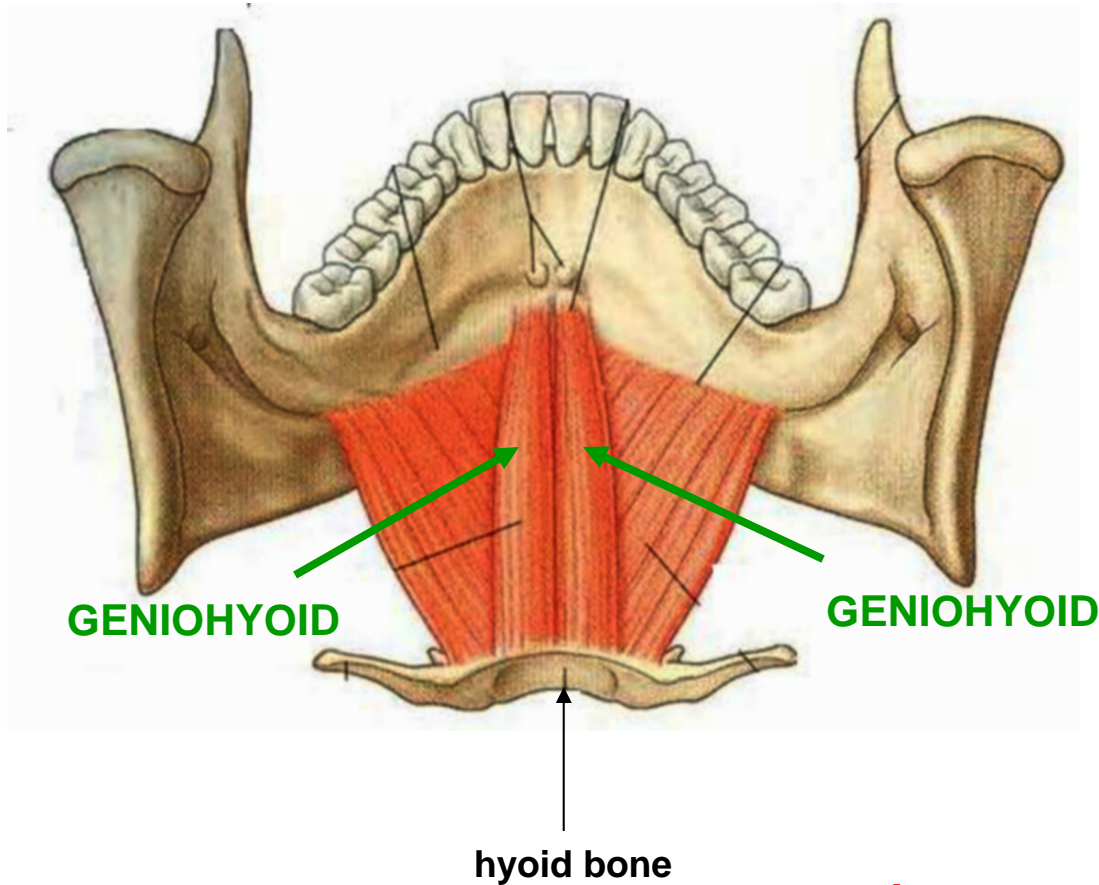


view from side



SUPRAHYOID MUSCLES - all elevate hyoid

view from inside mouth



4. GENIOHYOID -

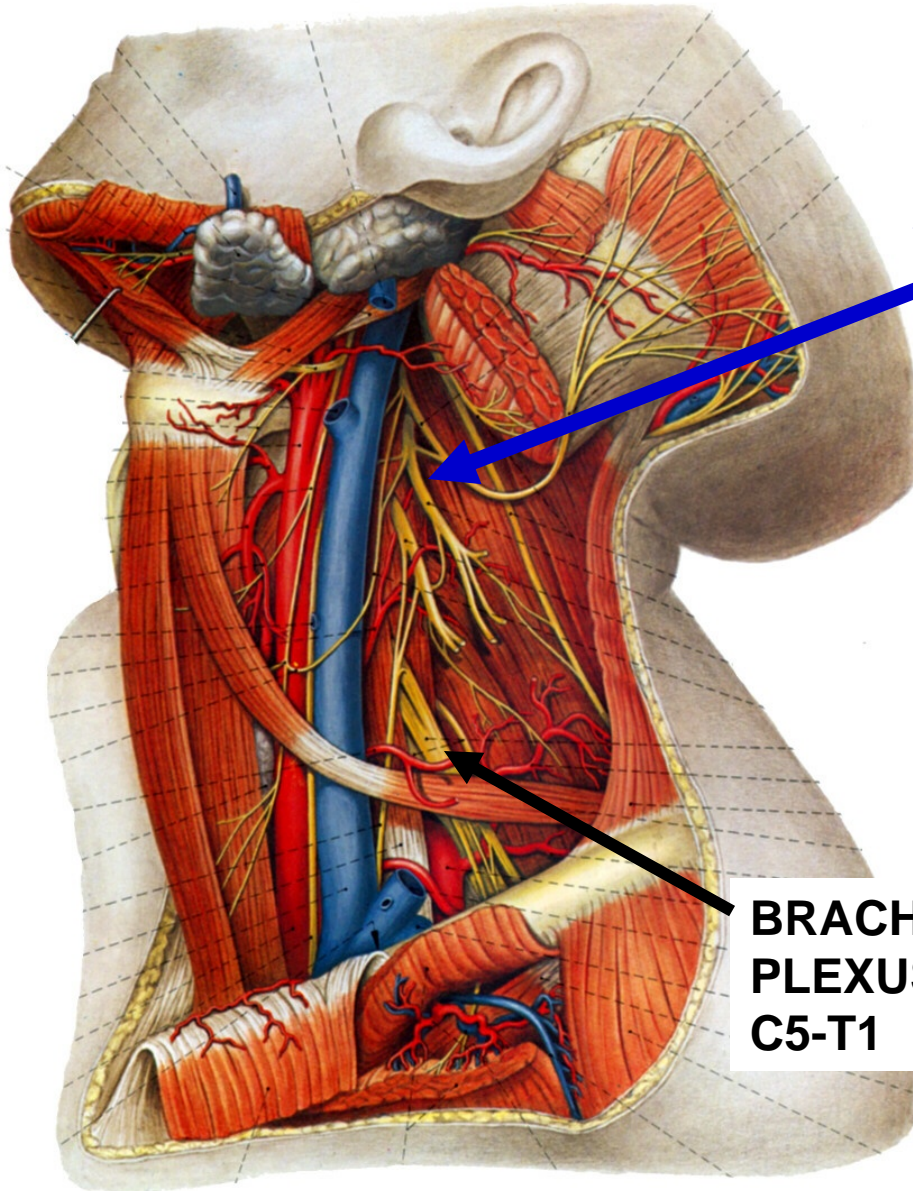
A - Elevates hyoid and draws forward

Inn - C1 branch
hitch-hiking with
Hypoglossal nerve
(CN XII)

important in swallowing

III. NERVES OF NECK

A. CERVICAL PLEXUS

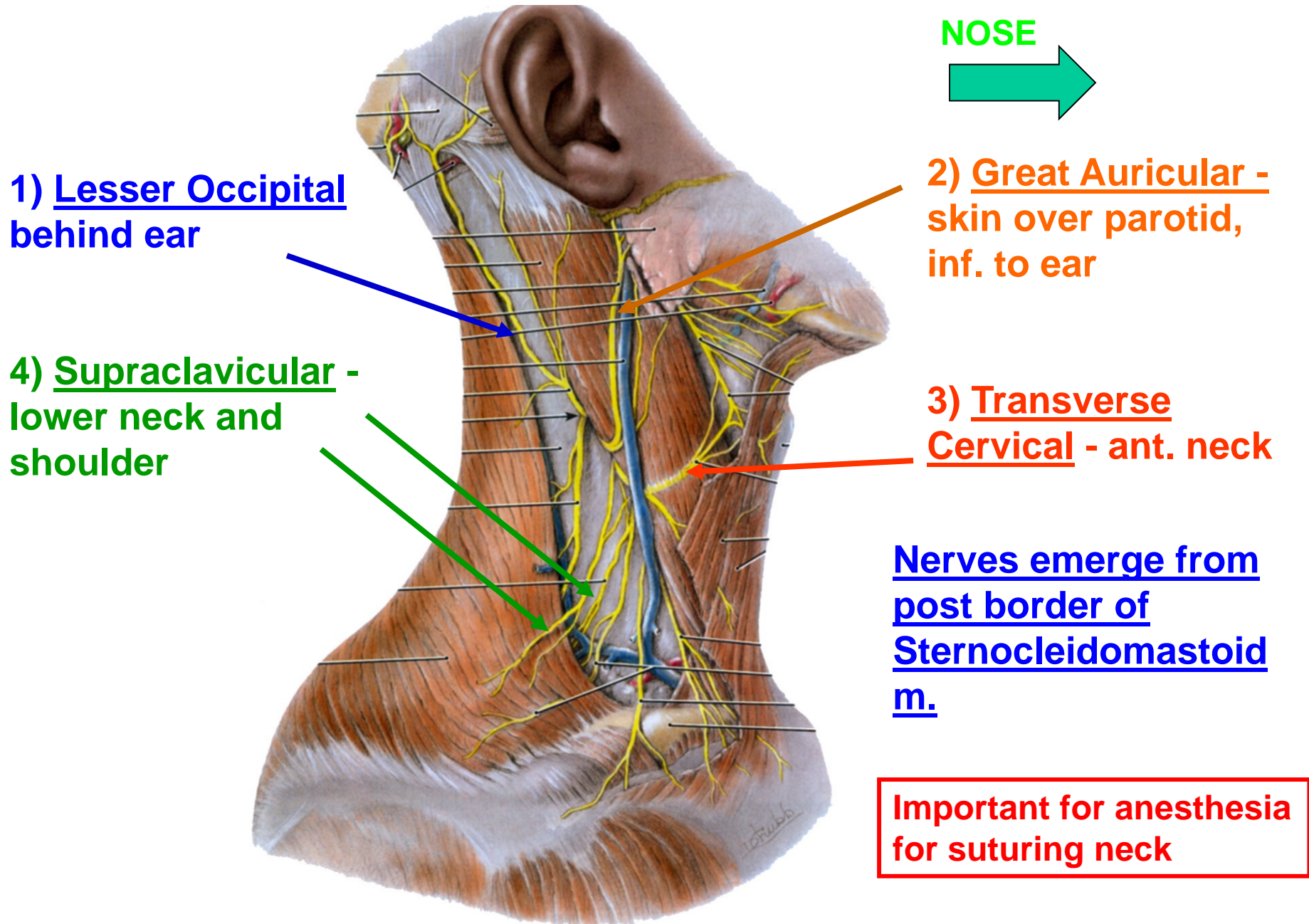


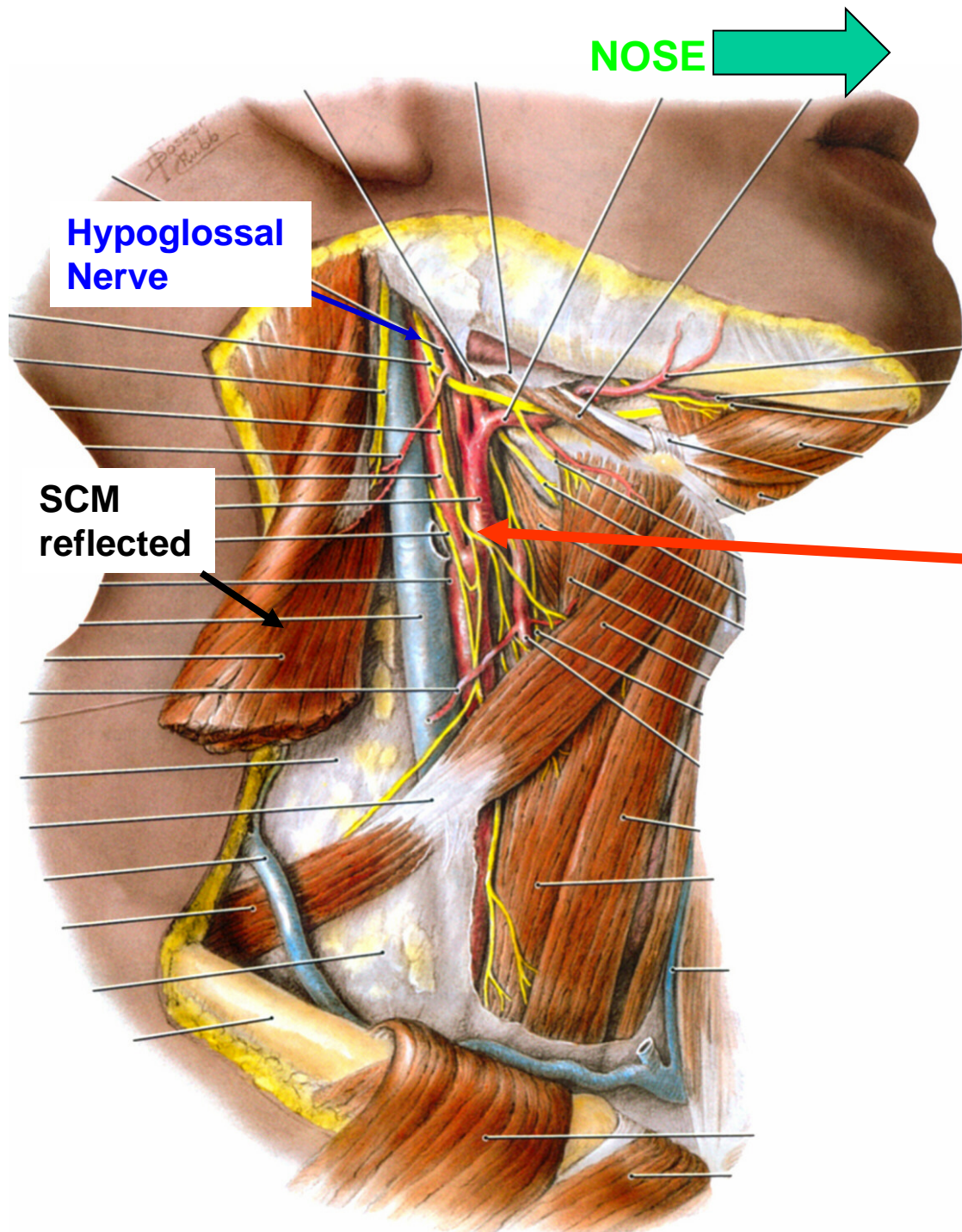
from C2-C4
ventral primary
rami

BRACHIAL
PLEXUS
C5-T1

not know detailed
branching pattern:
cervical plexus is
deep and protected

A. CERVICAL PLEXUS - cutaneous nerves





B. ANSA CERVICALIS

- fibers from C1 join Hypoglossal Nerve (XII)

- some leave and join fibers of C2 and C3 to form ANSA (loop) Cervicalis

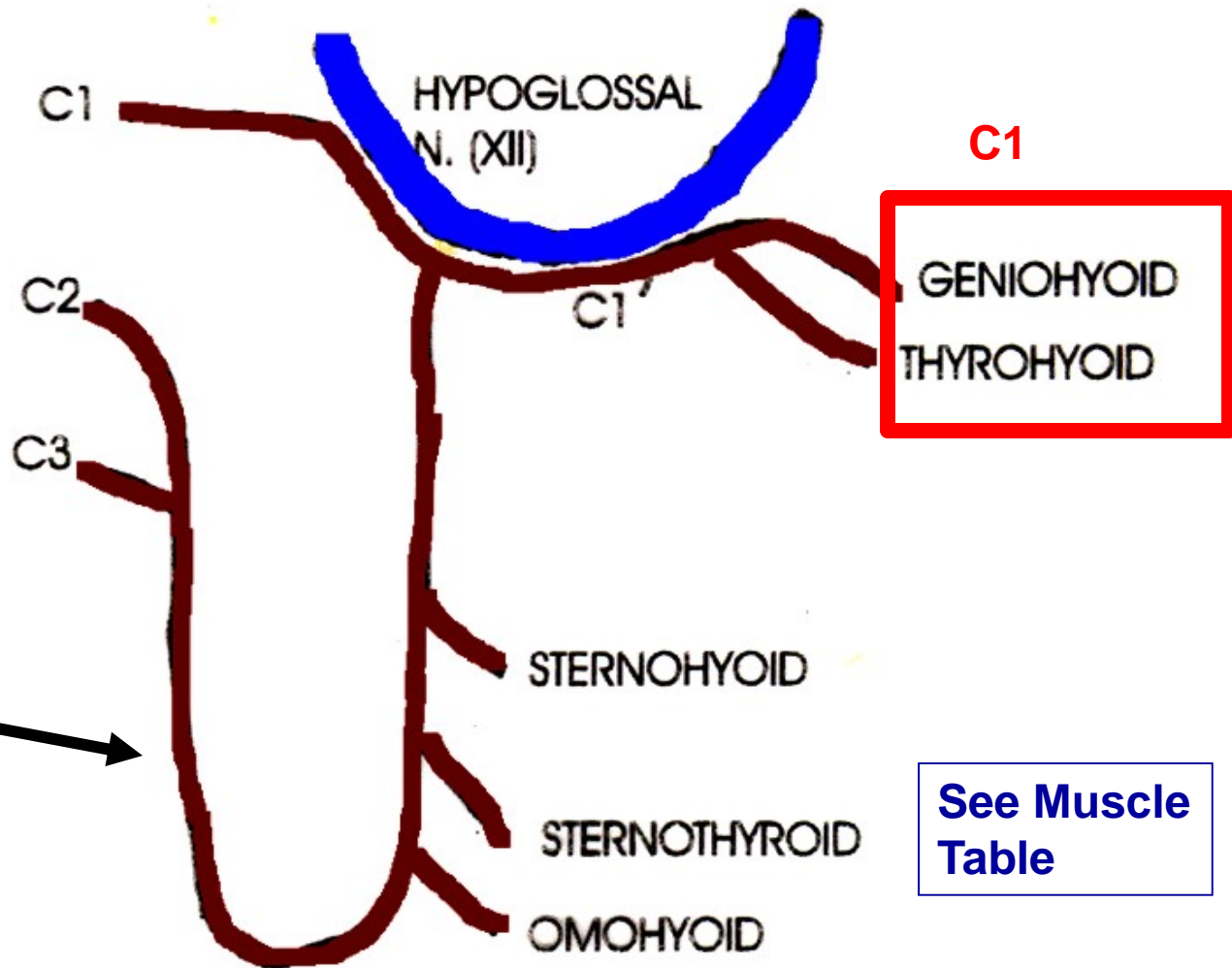
- other fibers continue with XII to innervate Thyrohyoid and Geniohyoid

(Looks like XII innervates neck muscles; actually C1-C3 do)

ANSA CERVICALIS

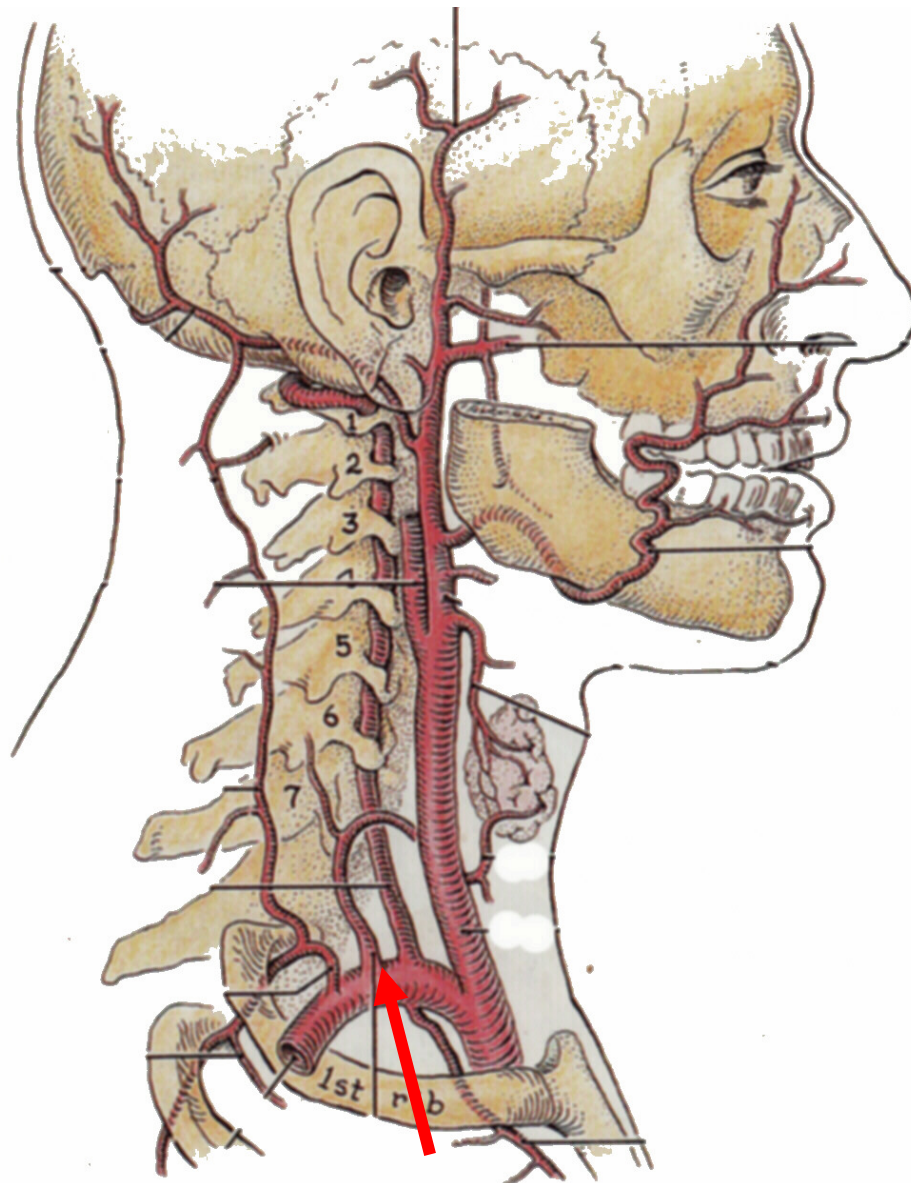
**CN XII
Receives
hitchhiking
fibers**

**LOOP =
ANSA
CERVICALIS**



**See Muscle
Table**

IV. ARTERIES OF HEAD AND NECK



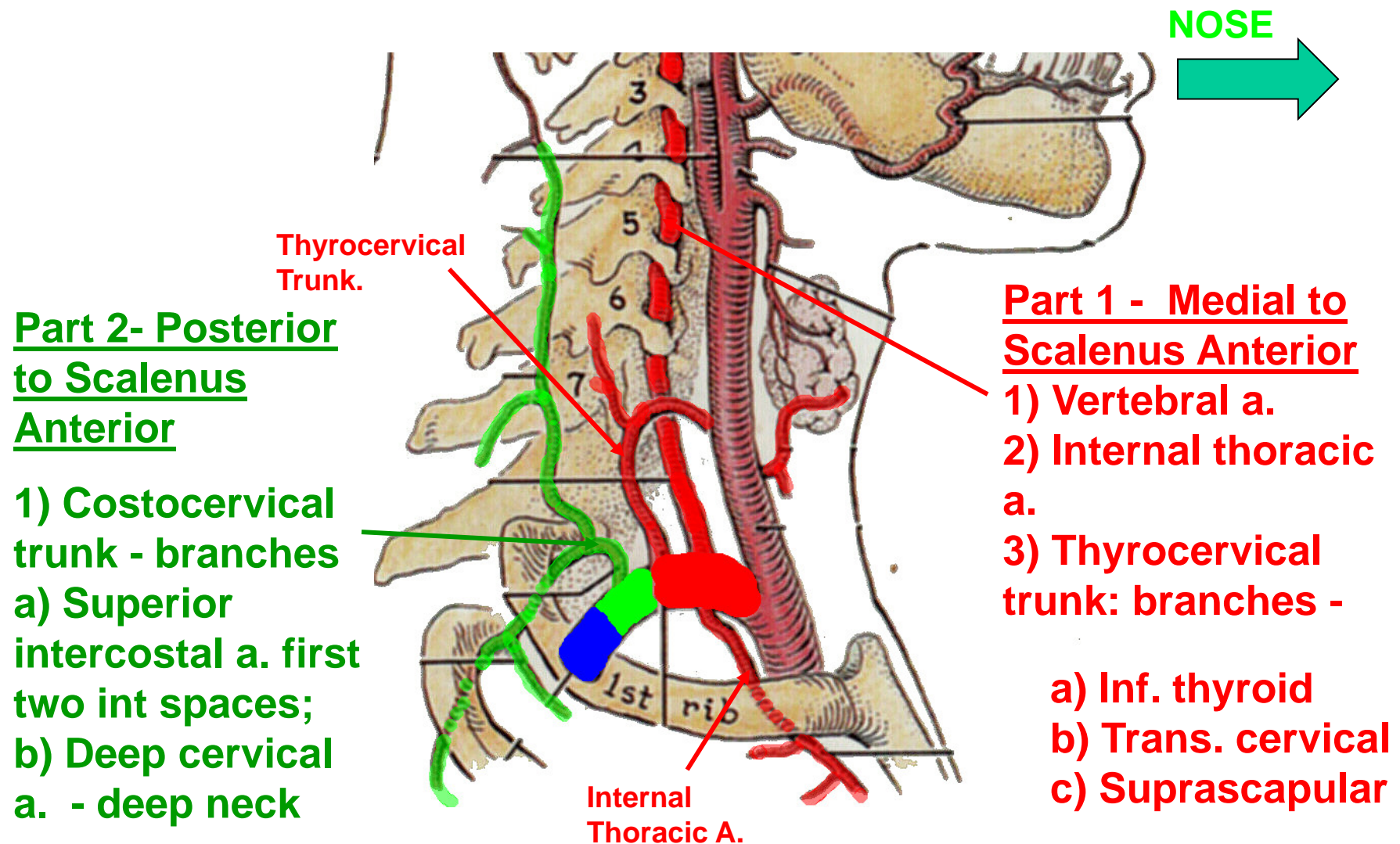
SUBCLAVIAN A.

A. SUBCLAVIAN ARTERY

At root of neck -
passes to arm -
becomes Axillary a.
(rib 1)

- Scalenus Anterior
muscle divides
Subclavian into 3
parts

SUBCLAVIAN ARTERY - divided into 3 parts by Scalenus Anterior muscle



Part 3 - Lateral to Scalenus Anterior - No Branches

**BRACHIAL
PLEXUS**

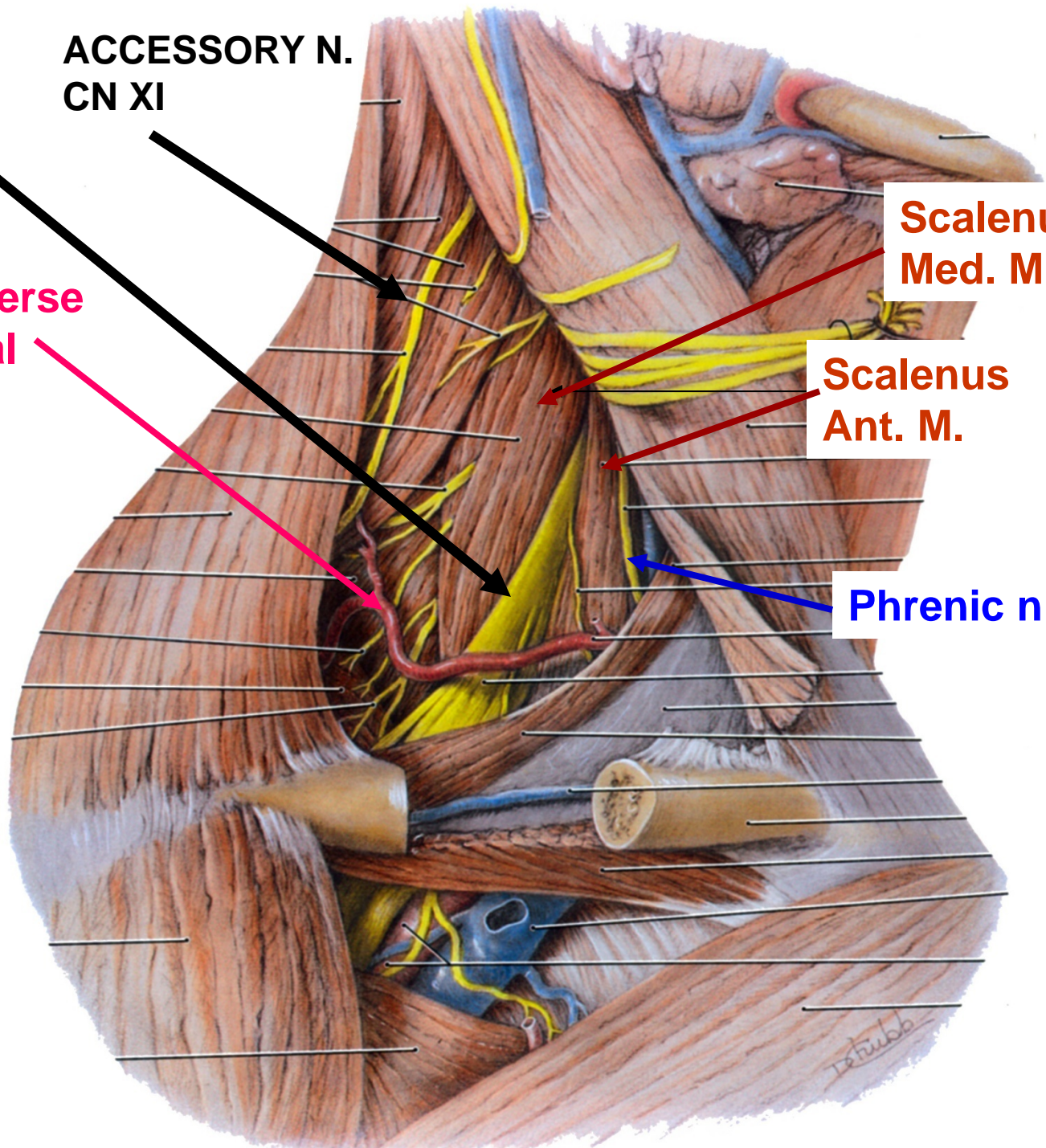
**ACCESSORY N.
CN XI**

**Transverse
cervical
artery**

**Scalenus
Med. M.**

**Scalenus
Ant. M.**

Phrenic n.



**BRACHIAL
PLEXUS**

**Transverse
cervical
artery**

**Supra-
scapular
artery**

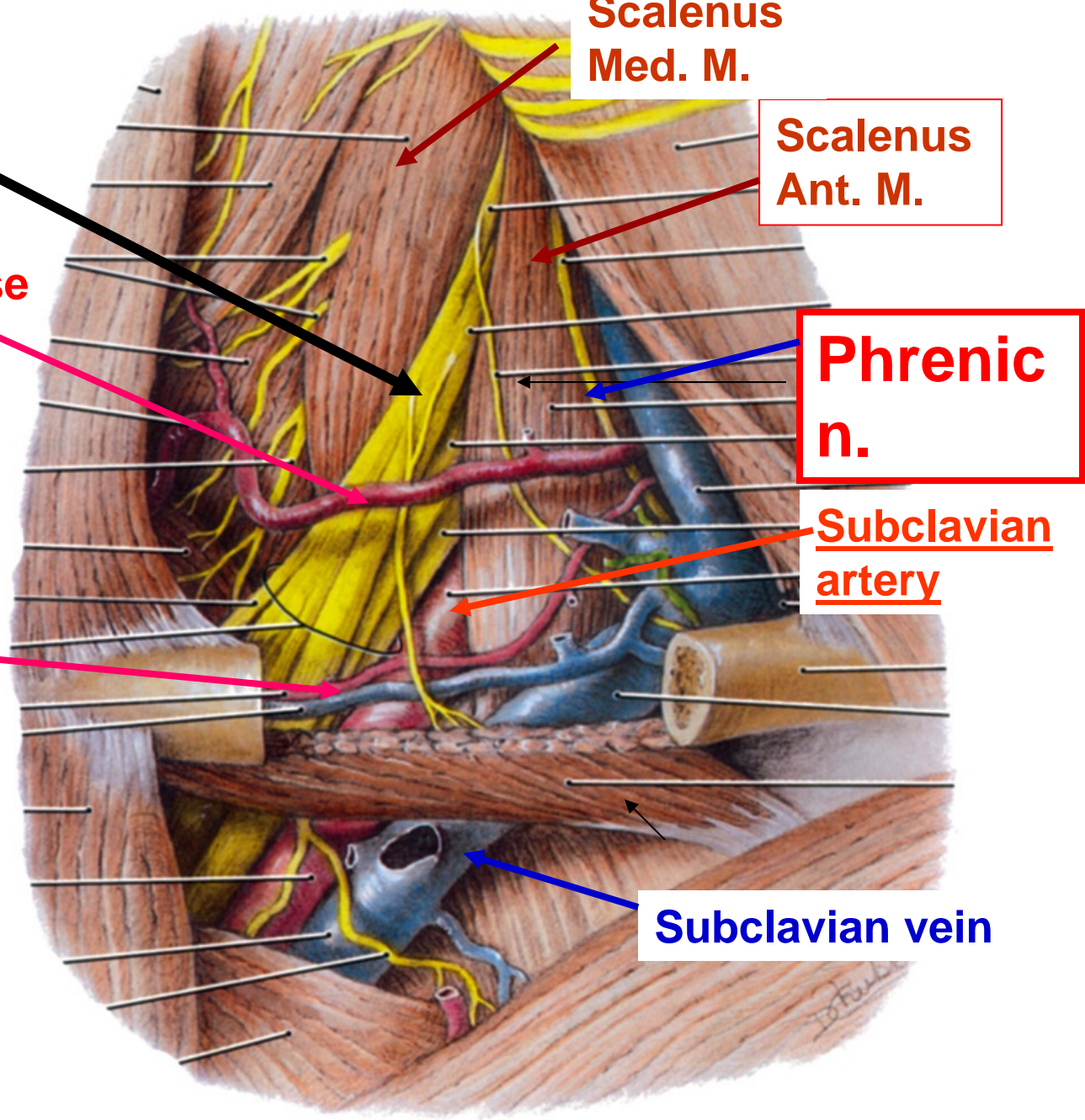
**Scalenus
Med. M.**

**Scalenus
Ant. M.**

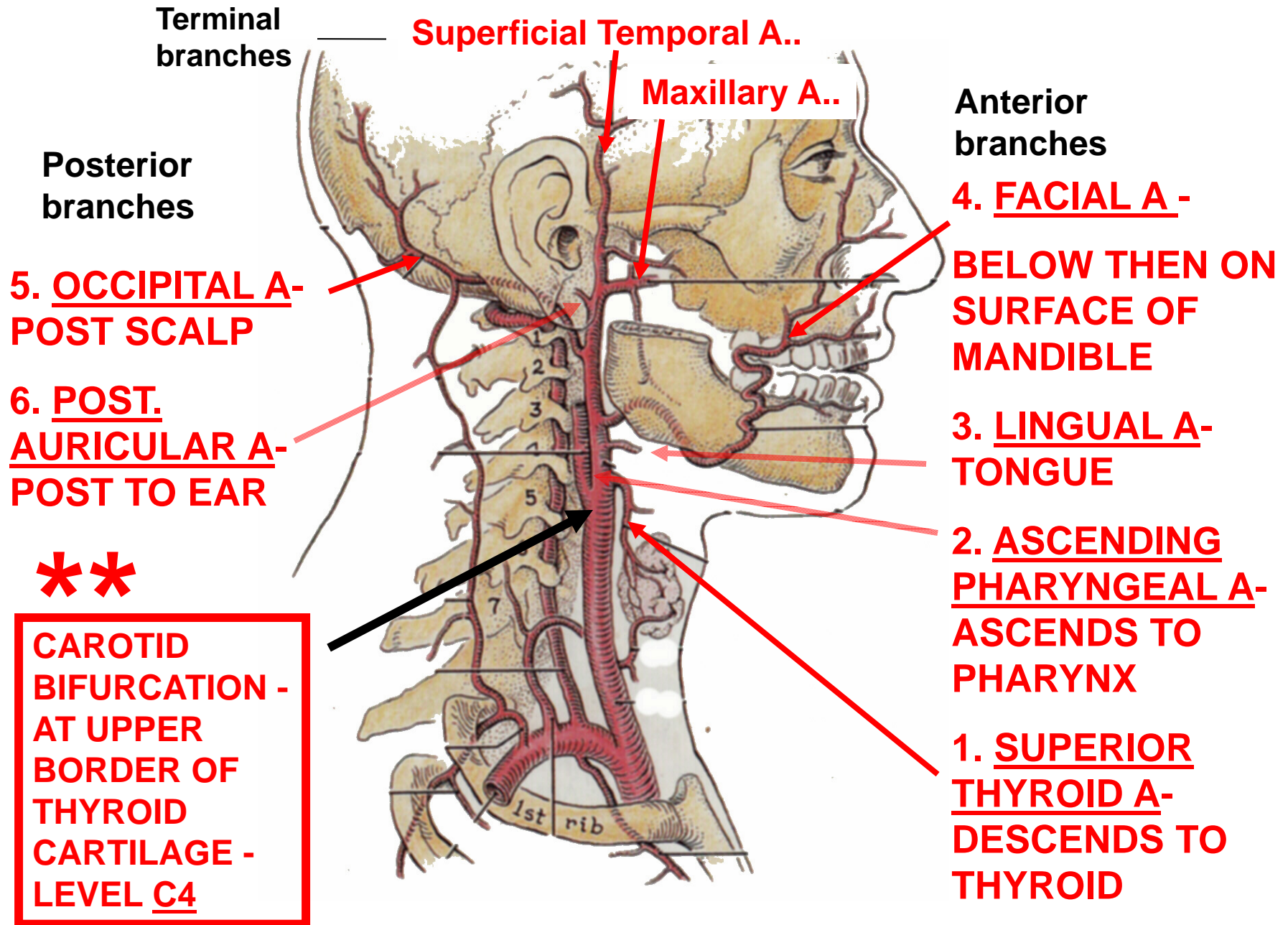
**Phrenic
n.**

**Subclavian
artery**

Subclavian vein



B. EXTERNAL CAROTID ARTERY



EXTERNAL CAROTID ARTERY

NOSE



Superficial Temporal-
scalp and temporalis

Post Auricular- post. ear
and scalp

Occipital-
posterior scalp

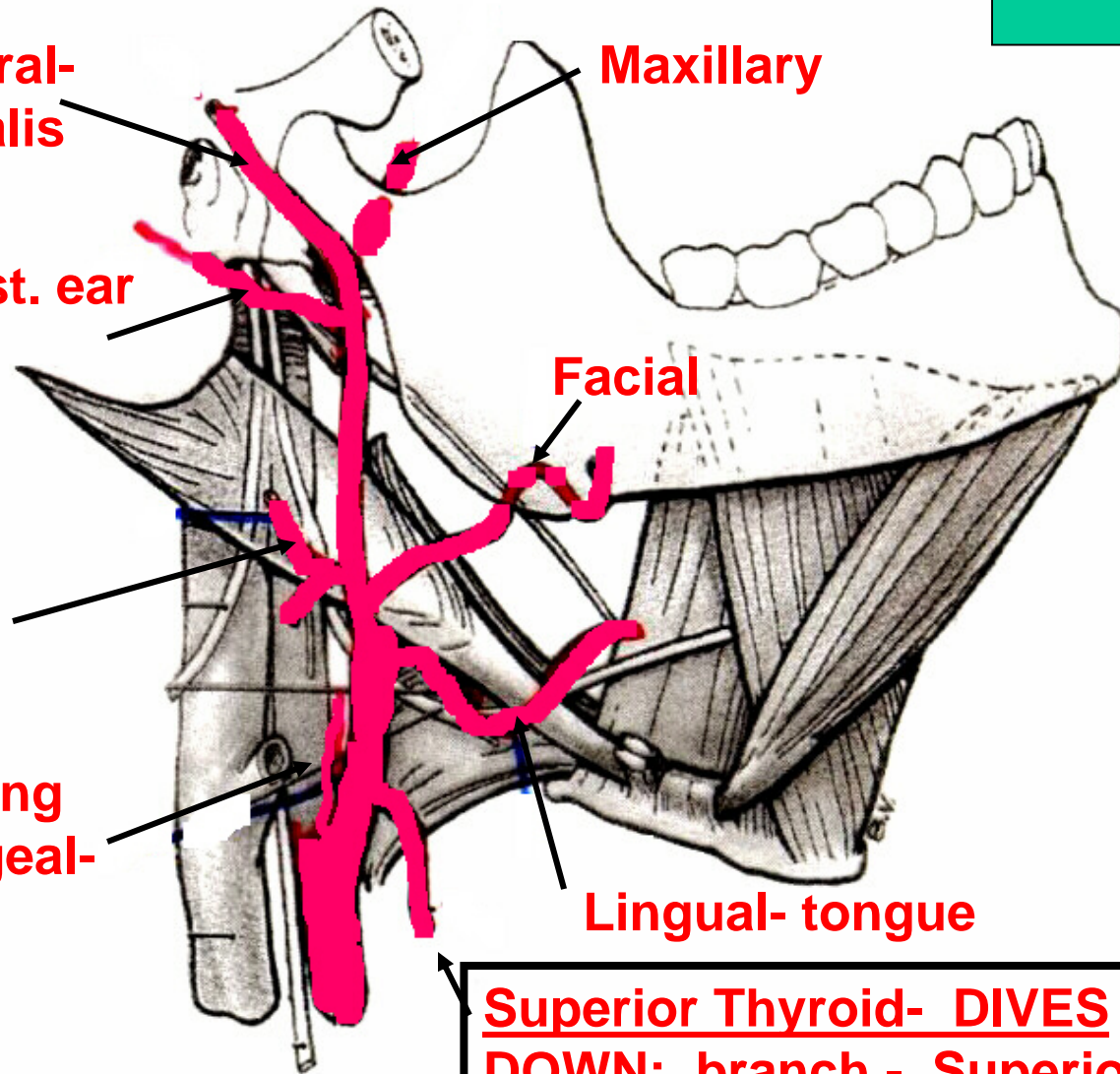
Ascending
Pharyngeal-
pharynx

Maxillary

Facial

Lingual- tongue

Superior Thyroid- DIVES
DOWN: branch - Superior
Laryngeal artery



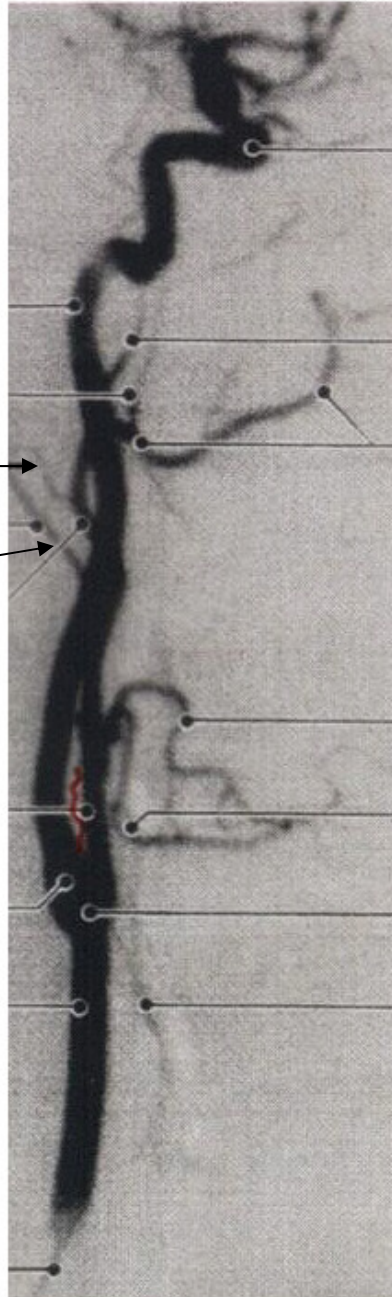
carotid arteriogram

Post side

Ant side

POST. AURICULAR

OCCIPITAL



SUP. TEMPORAL

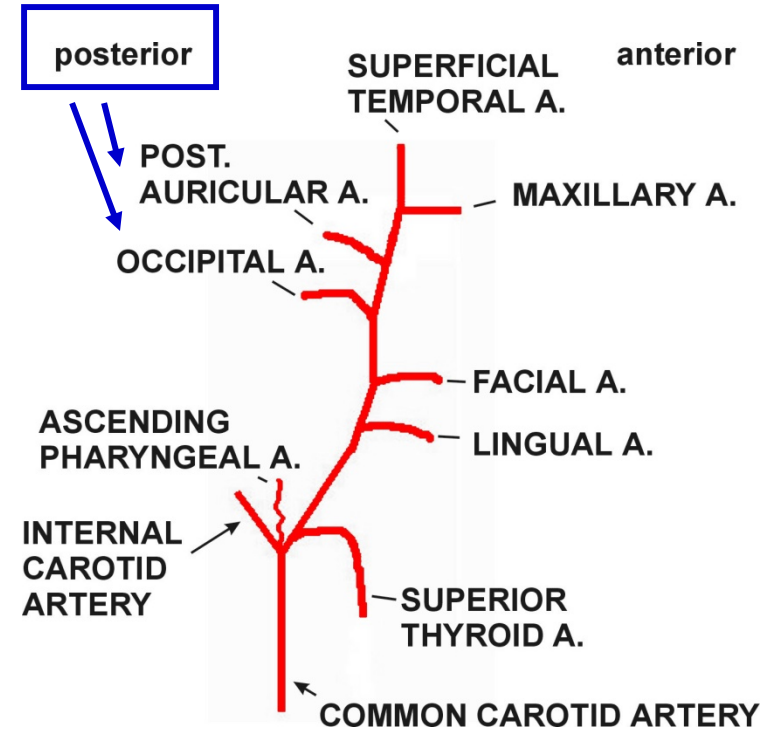

MAXILLARY

FACIAL

LINGUAL

SUP. THYROID

NOSE



posterior

POST. AURICULAR A.

OCCIPITAL A.

ASCENDING PHARYNGEAL A.

INTERNAL CAROTID ARTERY

SUPERFICIAL TEMPORAL A.

MAXILLARY A.

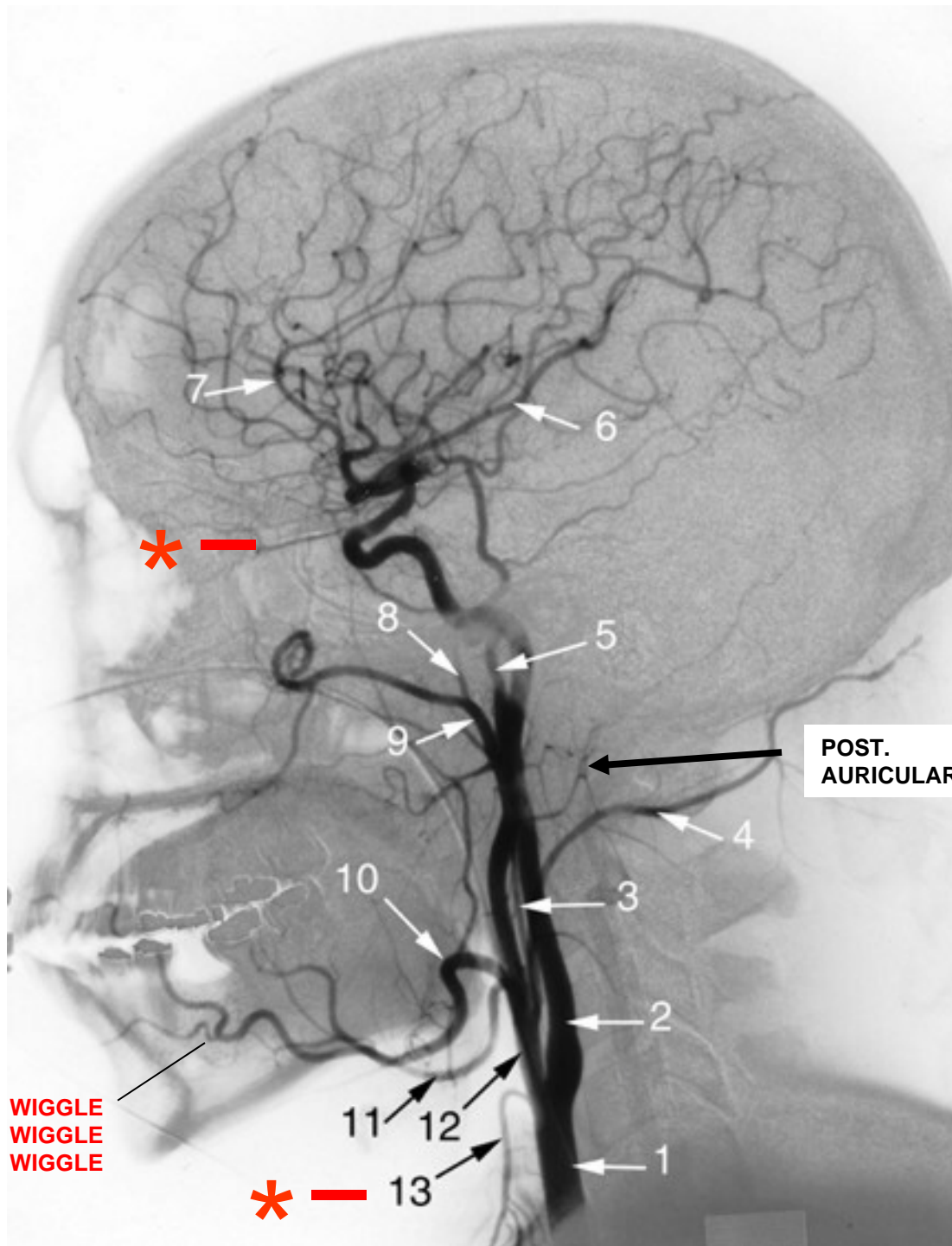
FACIAL A.

LINGUAL A.


SUPERIOR THYROID A.

COMMON CAROTID ARTERY

anterior



NOSE



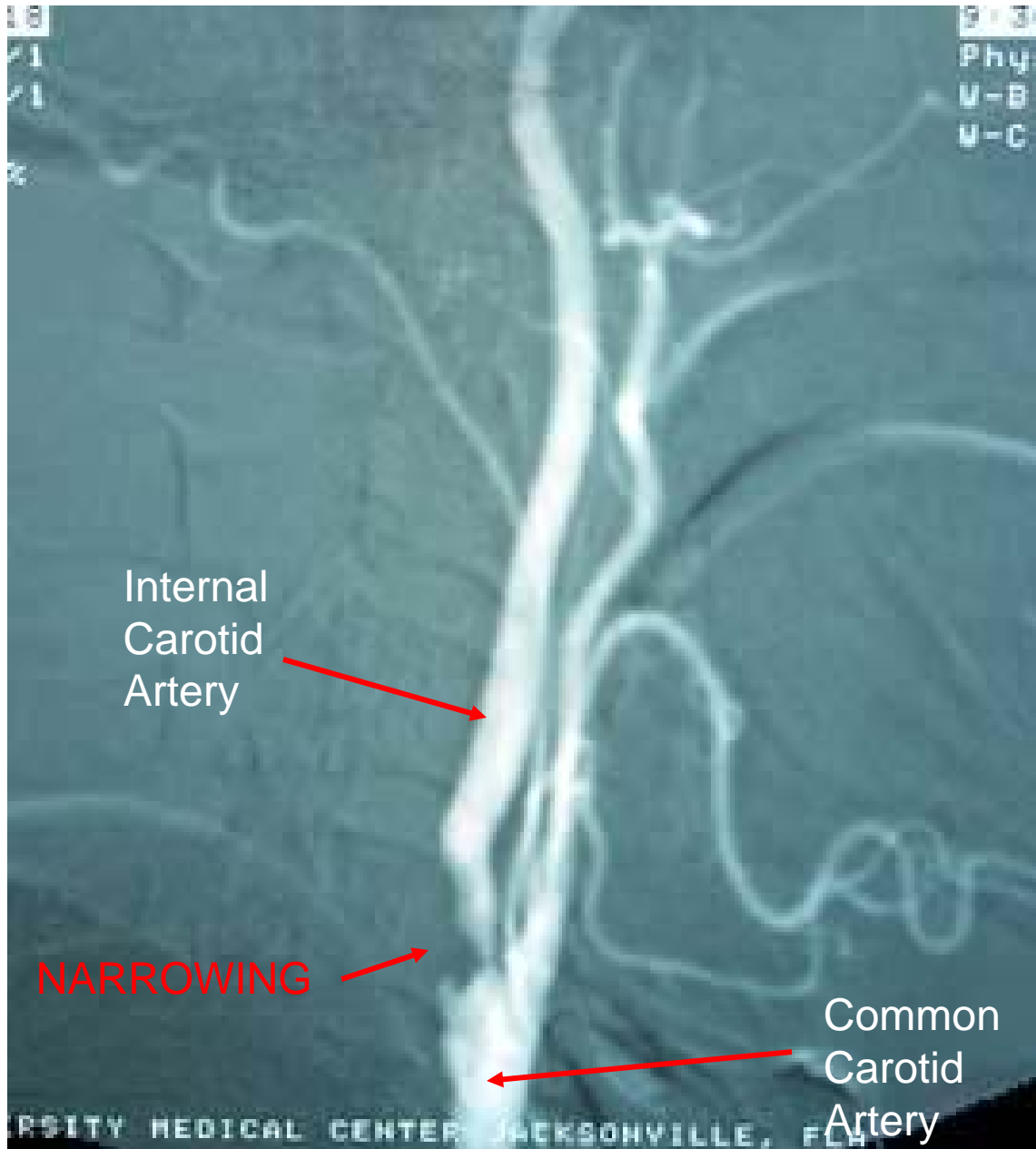
**KNOW THIS
SLIDE**

1. COMMON CAROTID
2. INTERNAL CAROTID
3. ASCENDING PHARYNGEAL
4. OCCIPITAL
5. SUPERFICIAL TEMPORAL
6. MIDDLE CEREBRAL
7. ANTERIOR CEREBRAL
8. MIDDLE MENINGEAL
9. MAXILLARY
10. FACIAL
11. LINGUAL
12. EXTERNAL CAROTID

13. SUPERIOR THYROID

*- OPHTHALMIC ARTERY
ARISING FROM CAROTID
SIPHON ***

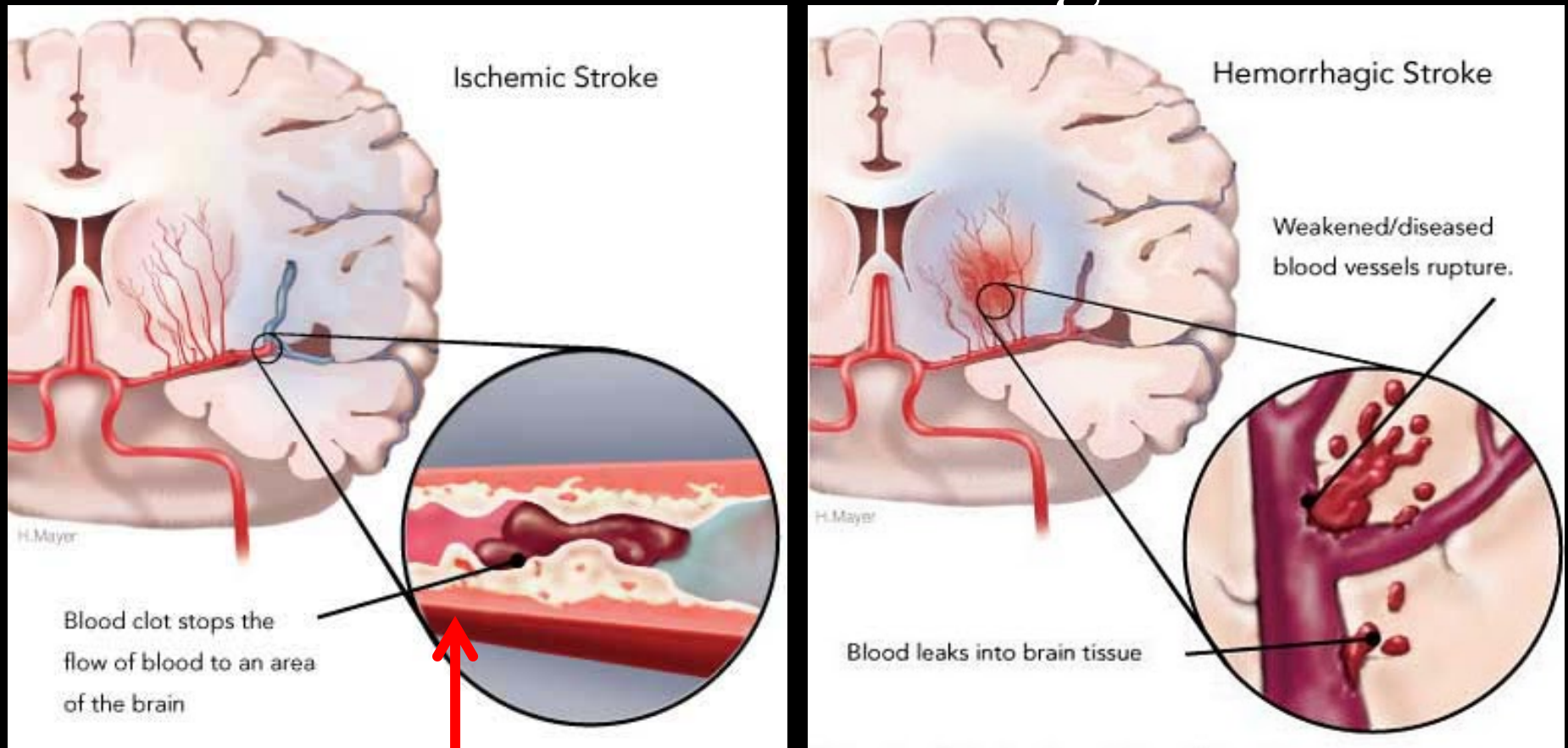
WIGGLE
WIGGLE
WIGGLE



The patient presented is a healthy 72 year old man who was found to have a preocclusive stenosis on work up.

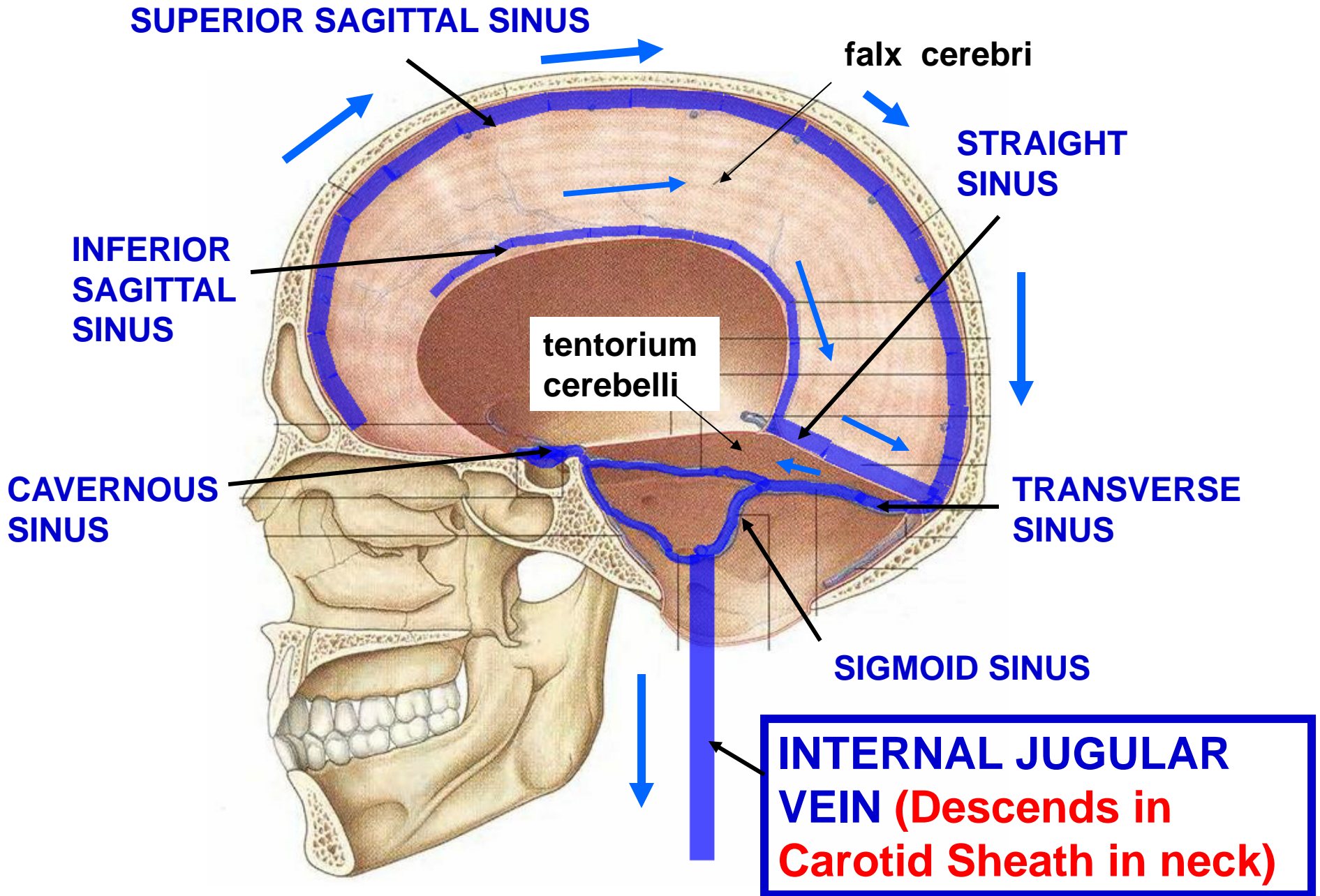
**STENOSIS -
ABNORMAL
NARROWING OF
VESSEL**

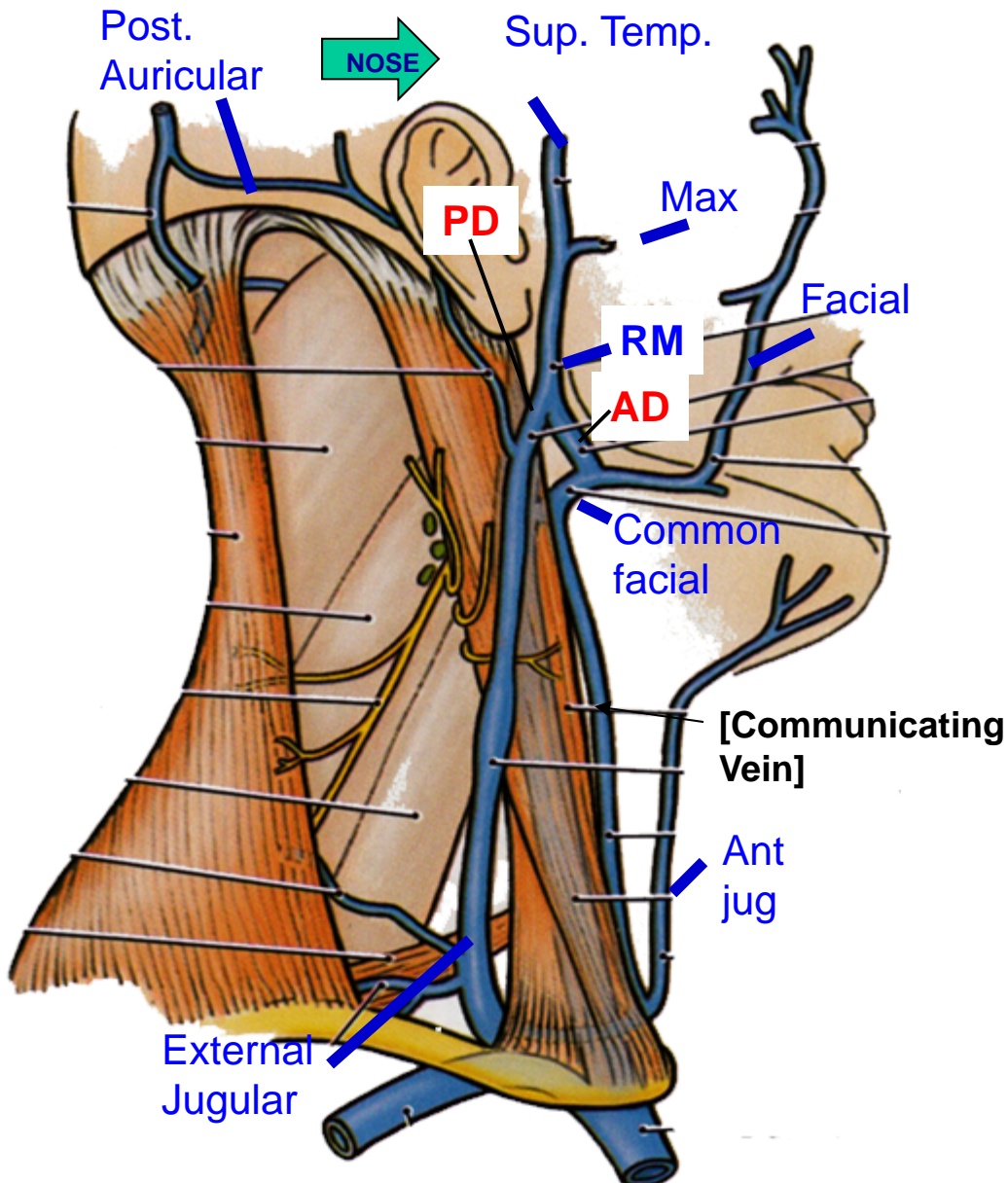
Ischemic vs. Hemorrhagic Stroke



Danger of Occlusion is Ischemic stroke – Insufficient blood supply to brain or giving rise to embolus (clot that is carried in arterial system, to brain)

VENOUS SINUSES OF BRAIN





V. VEINS OF NECK - drain areas of External Carotid Artery

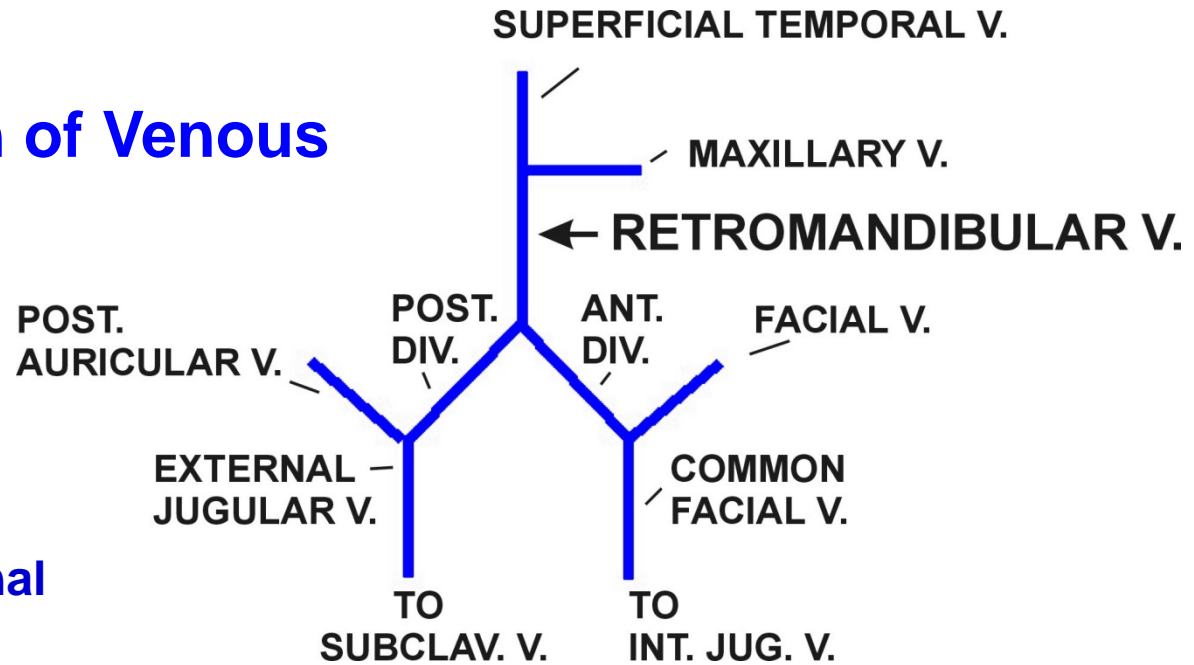
1. Superficial Temporal and Maxillary veins form Retromandibular V. (RM)
2. Retromand. V. Divides Ant. (AD) and Post. (PD) divisions
3. Ant. Division joins Facial V. to form Common Facial V. drains to Int. Jugular V.
4. Post. Division joins Post. Auricular V. to form External Jugular V (on surface of **Sternocleidomastoid muscle**) drains to **Subclavian V.**
5. Ant. Jugular from veins below mandible drains Ext. Jugular (above clavicle)

EXTERNAL JUGULAR V. - ON SURFACE OF STERNOCLEIDOMASTOID; NOT IN CAROTID SHEATH
INTERNAL JUGULAR V. - DEEP TO STERNOCLEIDOMASTOID; IN CAROTID SHEATH ***

VEINS OF NECK

Typical Pattern of Venous Drainage

Variations Common



Large External Jugular V.



Justin Bieber - teen 'idol'



Helen Schneider - singer



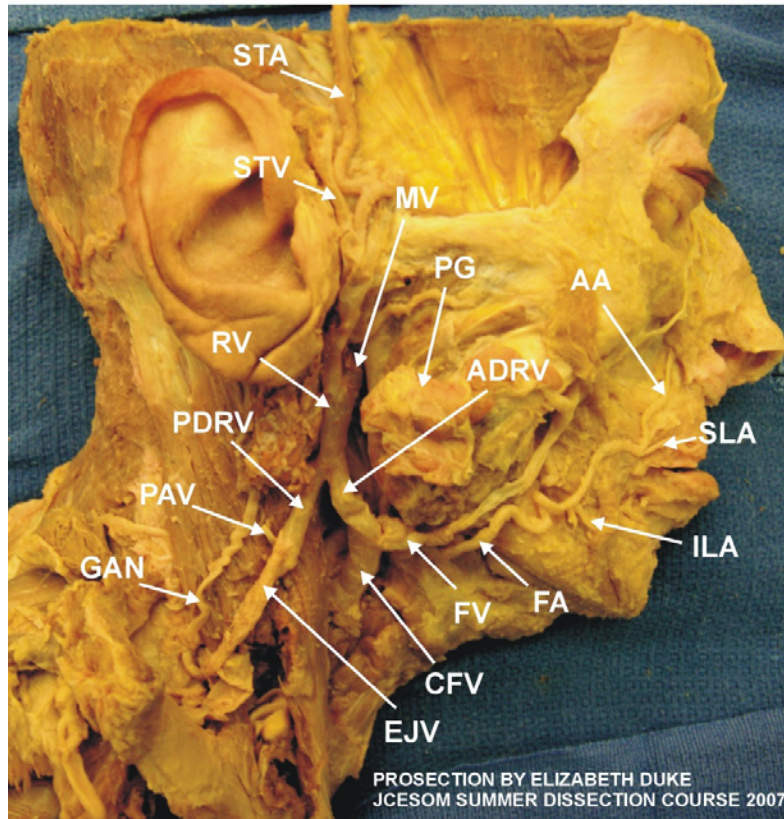
Bono - singer

Large Anterior Jugular V.

DEEP STRUCTURES IN PAROTID GLAND: FORMATION OF RETROMANDIBULAR VEIN

285

NOTE: PAROTID GLAND DISSECTED AND REFLECTED



VEINS OF NECK – Prosection 285

**Note: Posterior
Auricular vein
torn**

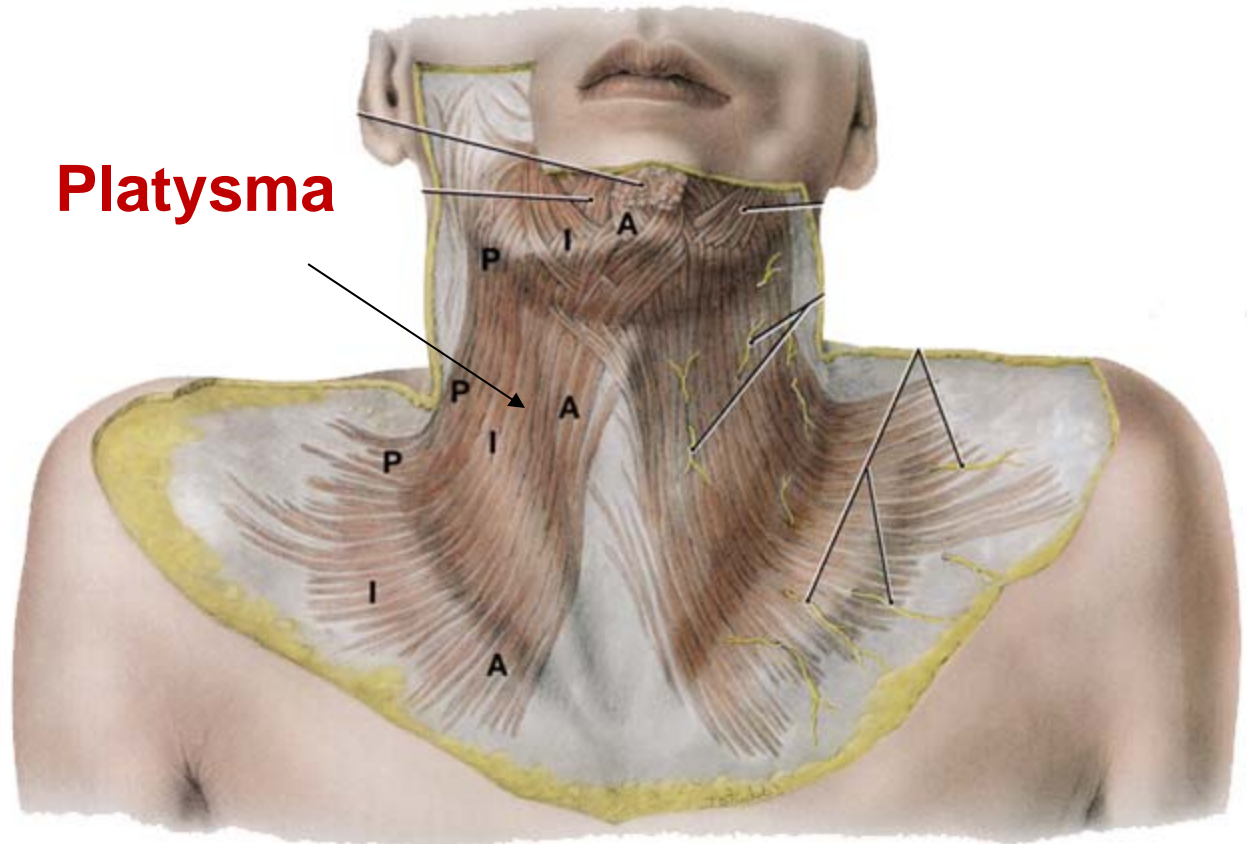
RV - RETROMANDIBULAR V
ADRV - ANTERIOR DIVISION OF RV
PDRV - POSTERIOR DIVISION OF RV
FA - FACIAL ARTERY
AA - ANGULAR ARTERY
SLA - SUPERIOR LABIAL ARTERY
ILA - INFERIOR LABIAL ARTERY
FV - FACIAL VEIN
GAN - GREAT AURICULAR NERVE
STV - SUPERFICIAL TEMPORAL VEIN
STA - SUPERFICIAL TEMPORAL ARTERY
PAV - POSTERIOR AURICULAR VEIN (CUT)

MV - MAXILLARY VEIN
CFV - COMMON FACIAL
VEIN
EJV - EXTERNAL
JUGULAR VEIN
PG - PAROTID GLAND
(cut and reflected)

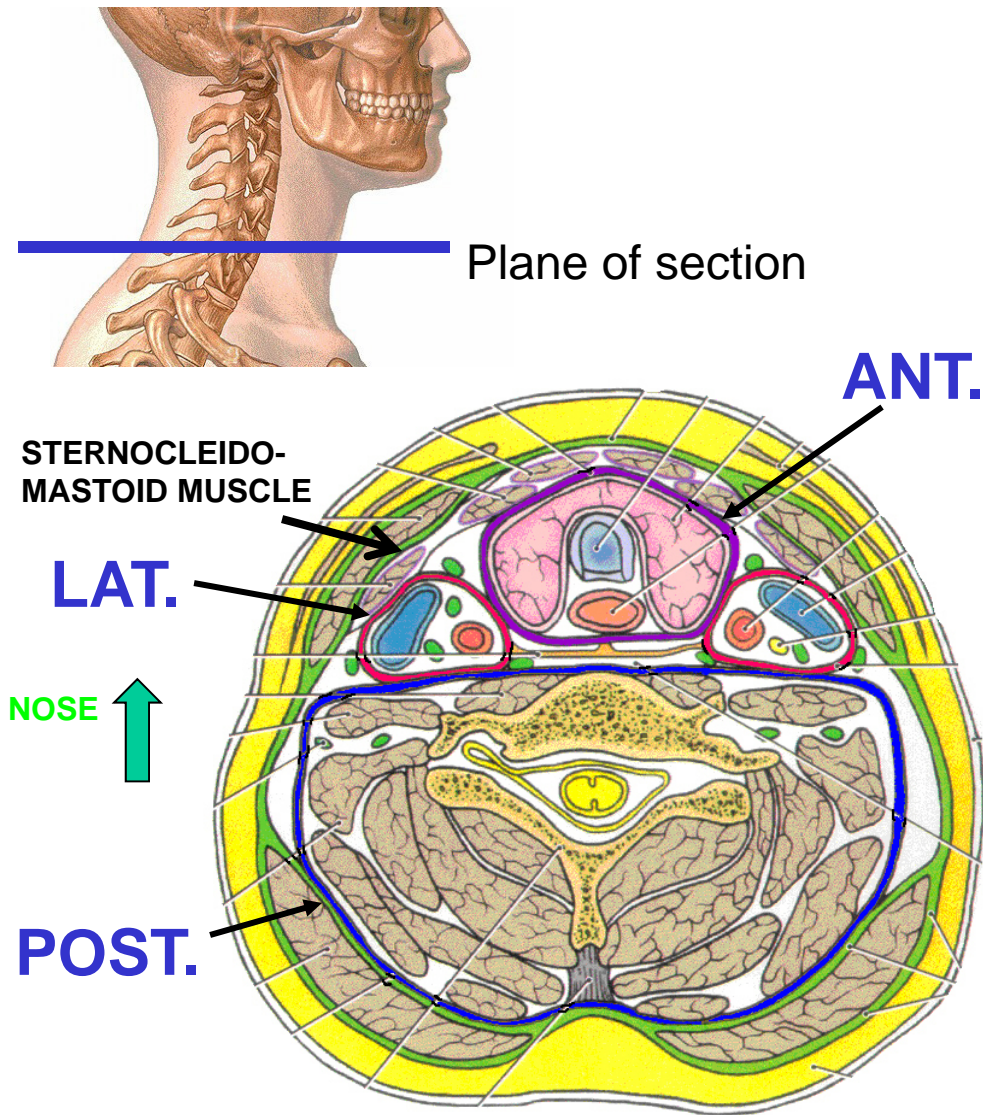
VI. FASCIA OF NECK

A. Superficial fascia:

- connective tissue below dermis
- completely surrounds neck - thin and hard to demonstrate
- contains **Platysma (muscle of Facial Expression CN VII)** and **Superficial veins**



I. OVERVIEW OF NECK - neck is compartmentalized



1. Posterior Compartment -
Vertebrae and muscles
which support and
move head and neck

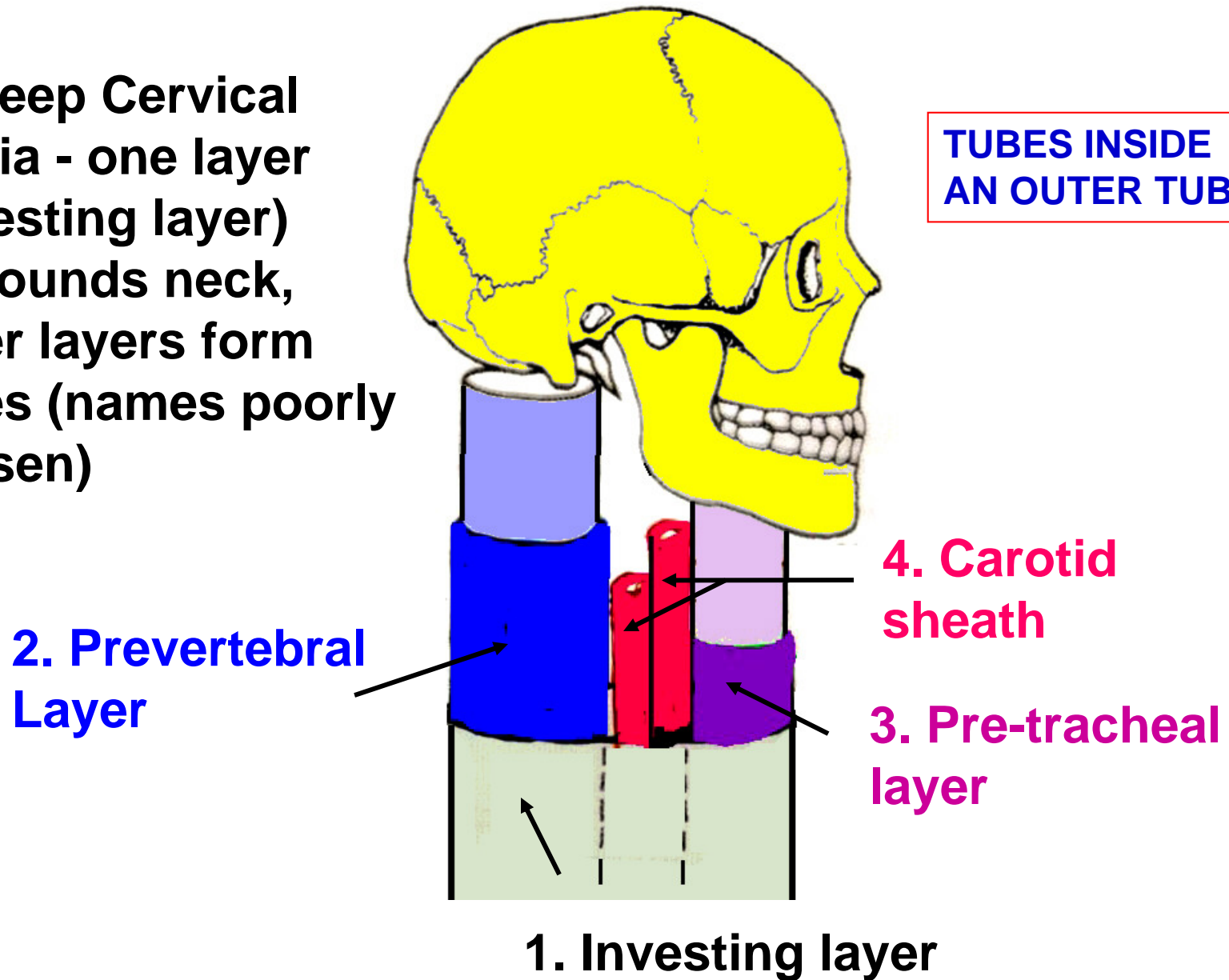
2. Anterior Compartment- **Viscera**
and rostral continuation
GI & Respiratory
Systems

3. Lateral Compartment-
Blood vessels and
nerve - **Carotid sheath**

HORIZONTAL SECTION THROUGH NECK

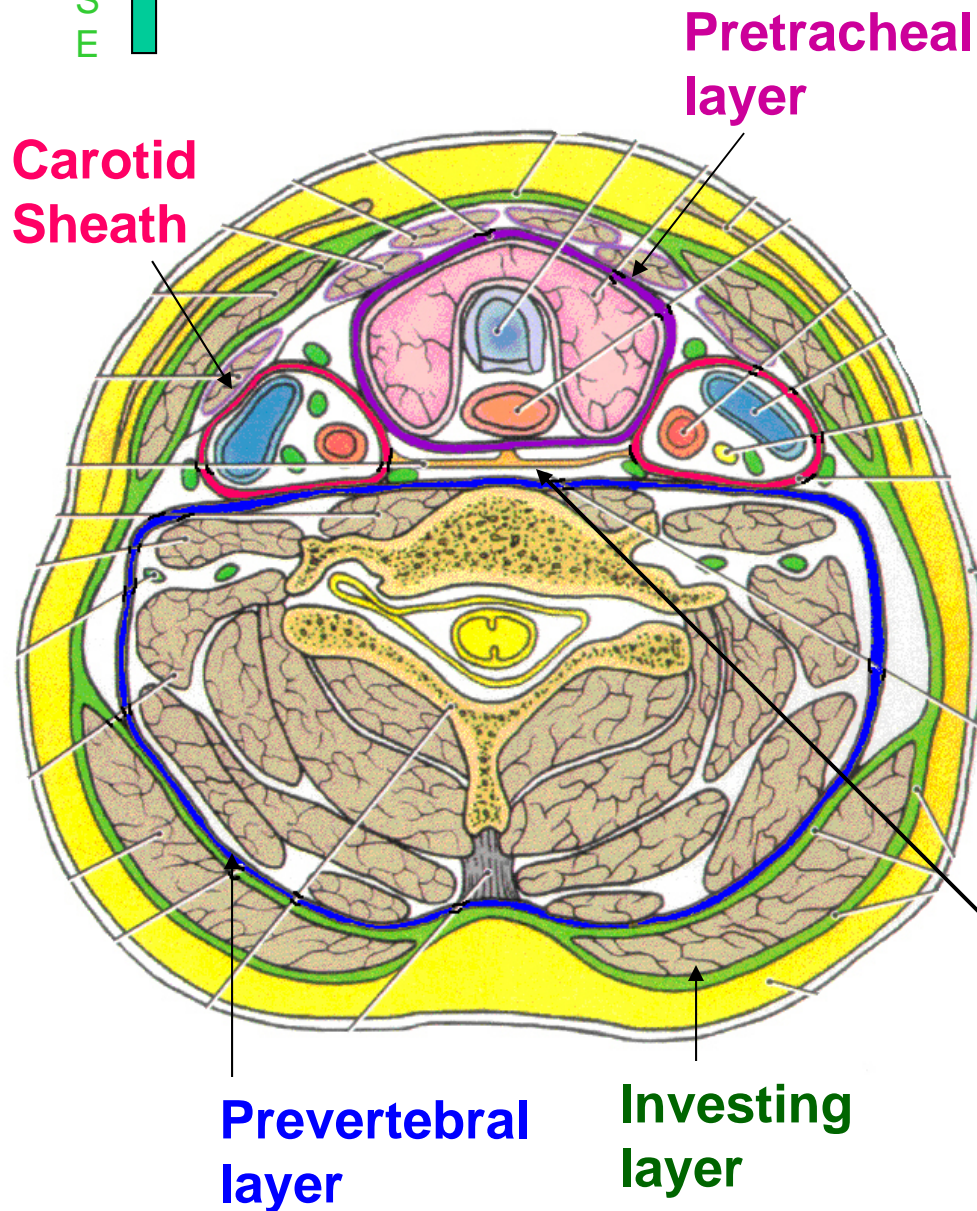
FASCIA OF NECK

B. Deep Cervical fascia - one layer (Investing layer) surrounds neck, other layers form tubes (names poorly chosen)



N
O
S
E

FASCIA OF NECK



1. Investing layer of deep cervical fascia- surrounds neck, splits around sternocleidomastoid, trapezius, supra and infrahyoid m.

2. Prevertebral Layer- surrounds vert. column, muscles of neck, (prevertebral, lat. vertebral, suboccipital m.)

3. Pretracheal Layer- surrounds trachea, esophagus and thyroid continues to thorax. **

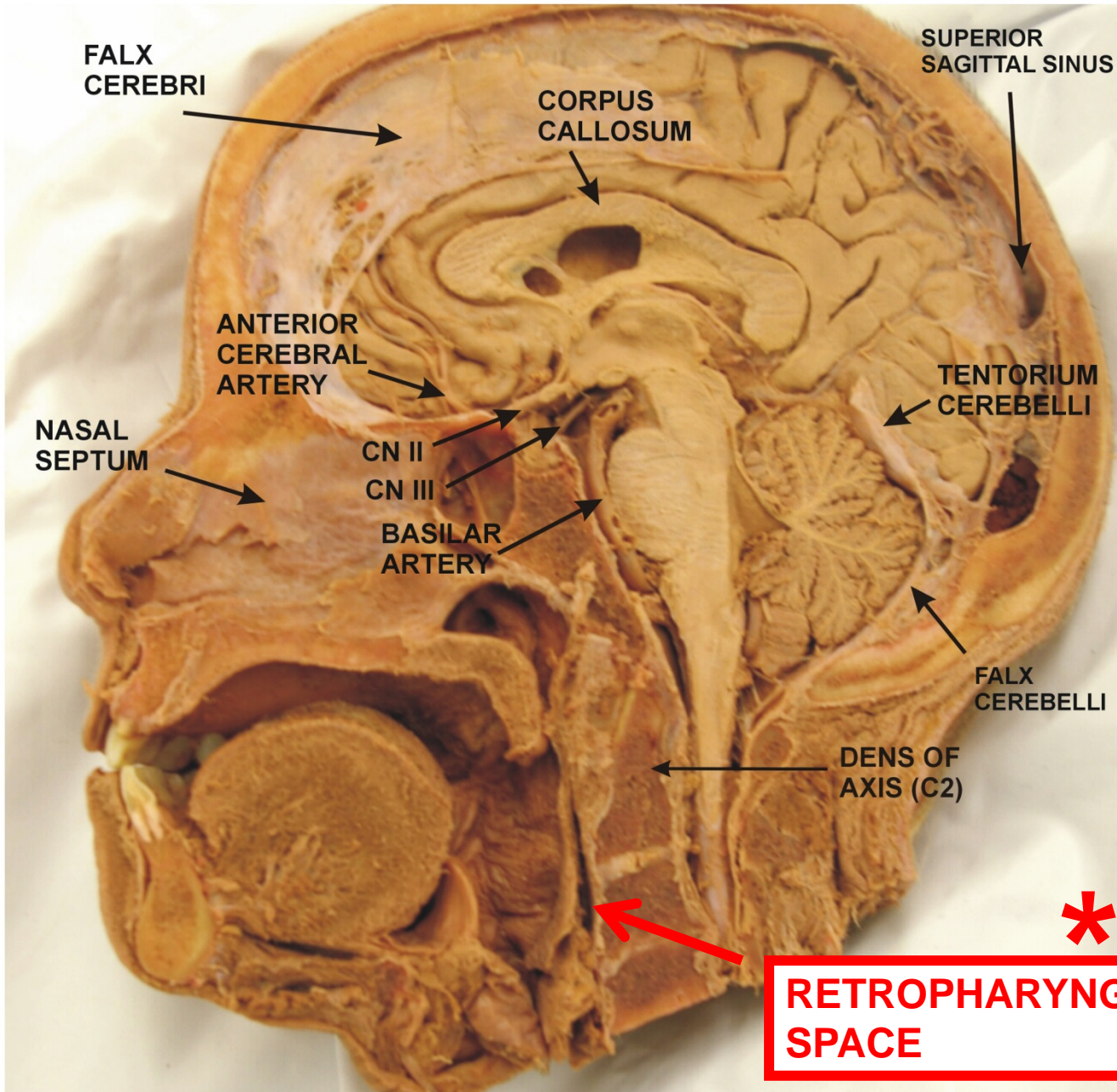
CLINICAL

4. Carotid Sheath- surrounds Common & Int carotid, Int jugular and X Vagus (not: Symp. Chain)

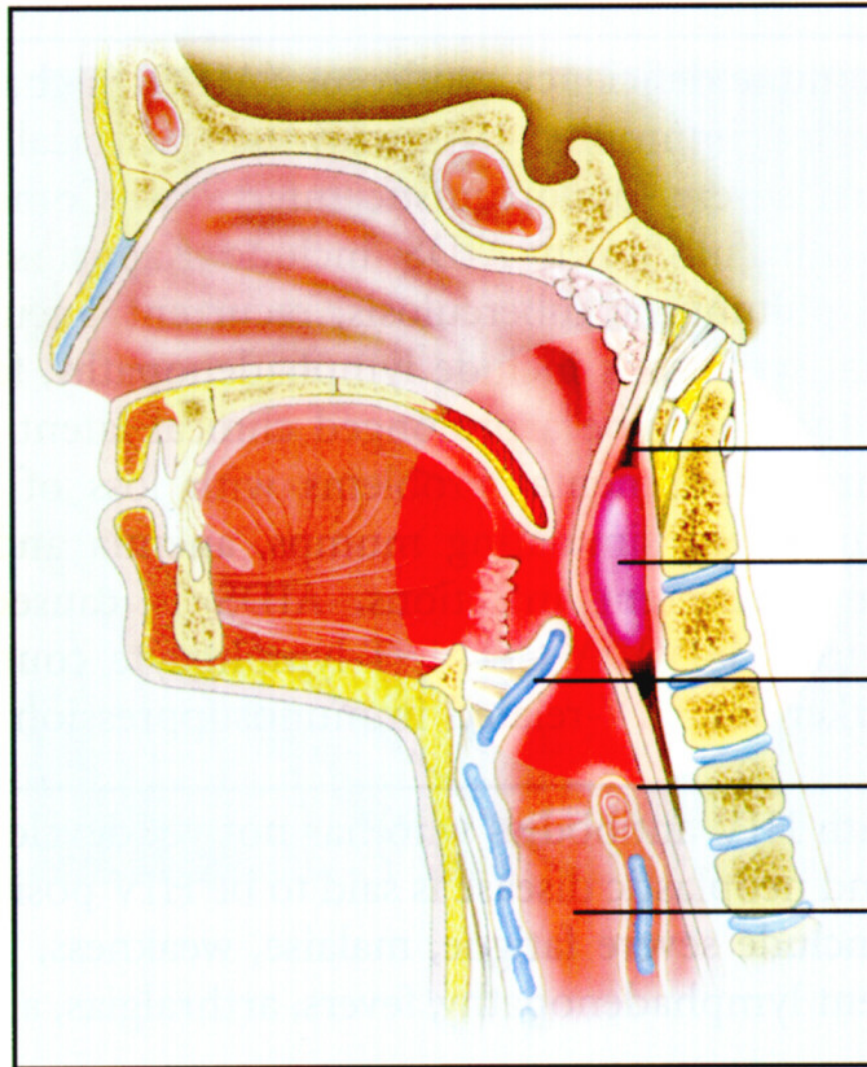
Retropharyngeal Space- between Pretracheal and Prevertebral layers - infection from head (tonsillitis) can spread to mediastinum **

MEDIAL VIEW OF BISECTED HEAD

1069



RETROPHARYNGEAL ABSCESS



Infection in retropharyngeal space can spread unimpeded to thorax (mediastinum)



Retropharyngeal space

Abscess

Epiglottis

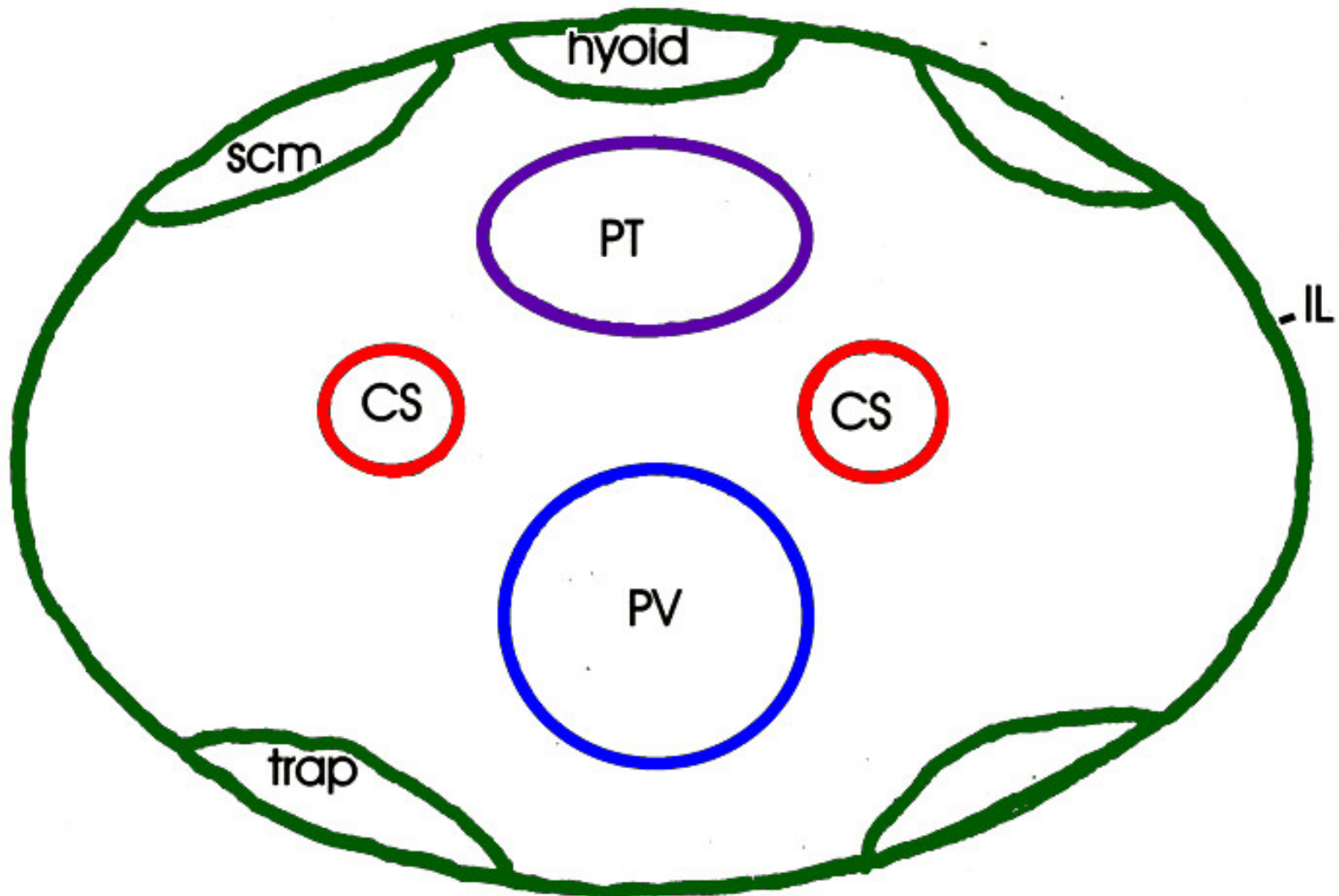
Esophagus

Trachea

Retropharyngeal Abscess - can be difficult to diagnose (no external swelling; life-threatening as abscess can block airway; George Washington may have died of this.

CLINICALLY IMPORTANT

FASCIA OF NECK



VII. LYMPHATICS OF HEAD AND NECK

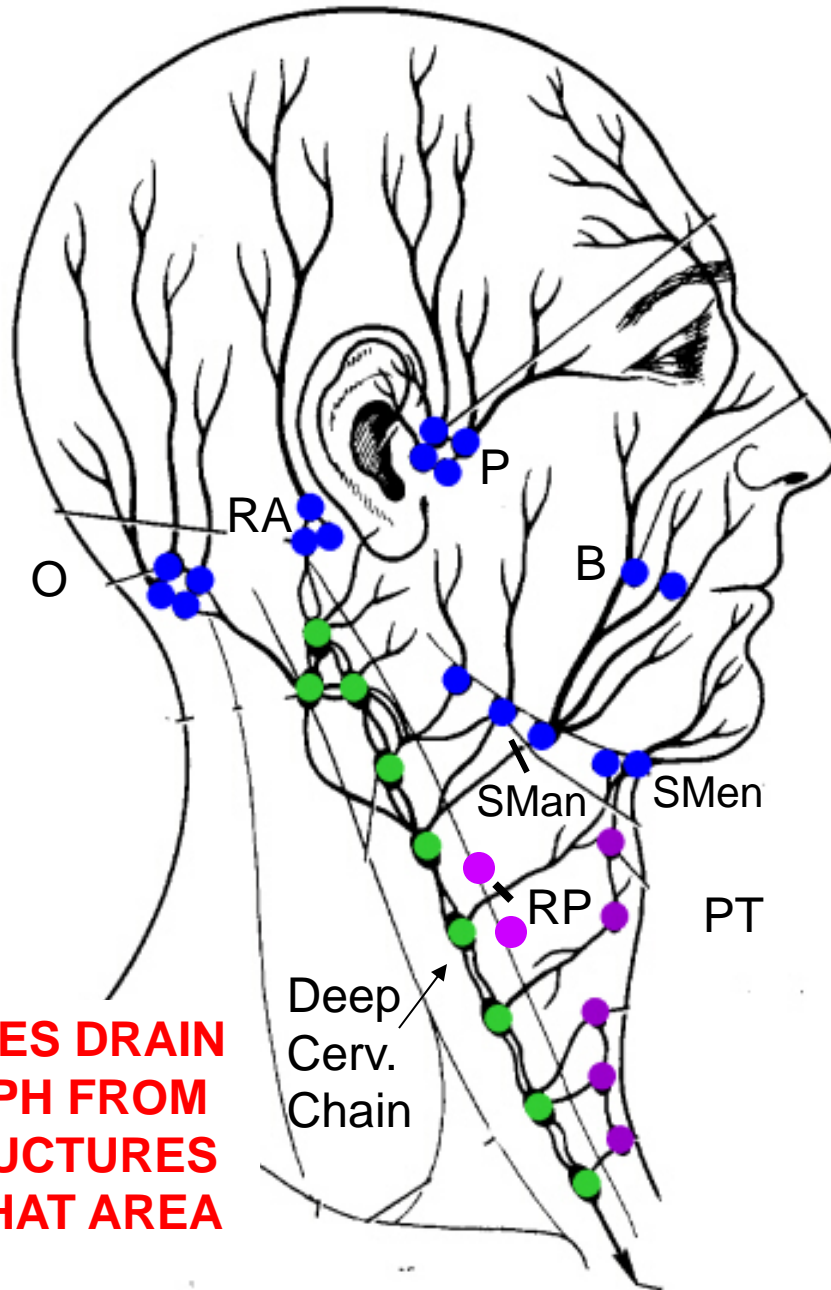
three groups (two arranged as rings; drain to chain); many named for regions drained

A. Superficial Ring; Submental, Submandibular, Buccal, Parotid, Retroauricular and Occipital nodes

B. Deep Ring: Pretracheal, Retropharyngeal nodes

C. Deep cervical chain- along Internal Jugular vein; receive lymph from all above nodes

D. Jugular lymph trunk - to Right lymphatic duct or Thoracic duct



**NODES DRAIN
LYMPH FROM
STRUCTURES
IN THAT AREA**

